



CLINICAL GROUP



**JOURNAL OF
Surgery and Surgical Research**

ISSN: 2455-2968

DOI: <https://dx.doi.org/10.17352/jssr>

Case Report

Sciatic nerve injury associated with acetabular fracture (About a case)

MJEI Mekkaoui*, J Boukhris, M Boussaidane, B Chafry, D Bencheba, AS Bouabid and M Boussouga

Department of Orthopaedic and Traumatologic Surgery-Mohammed V Military Hospital, Rabat, Morocco

Received: 18 March, 2020

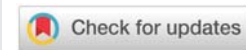
Accepted: 02 April, 2020

Published: 03 April, 2020

***Corresponding author:** Jalal mekkaoui, Department of Orthopaedic and Traumatologic Surgery-Mohammed V Military Hospital, Rabat, Morocco, E-mail: jalal_mekkaoui@hotmail.com

Keywords: Sciatic nerve palsy; Acetabular fracture; Hip dislocation

<https://www.peertechz.com>



Abstract

Sciatic nerve injuries associated with acetabular fractures is a serious and rare complication. It may be a result of the initial trauma or injury at the time of surgical reconstruction. Prevention requires attention to intraoperative limb positioning, retractor placement, and instrumentation. Patients may present with a broad range of symptoms ranging from radiculopathy to foot drop and the neurological lesions may be irreversible.

We report the case of a 38 years old young man, operated for a left fracture-dislocation of the hip joint complicated by a total paralysis of the sciatic nerve after the surgical act. The diagnosis of the sciatic nerve injury was suspected clinically and confirmed by the electrophysiological explorations. The tomodensitometry was normal without compressive haematoma. After one year of surgery, the patient had a complete recovery of the posterior tibial nerve, and partial recovery of the fibular nerve.

The purpose of the clinical case is to account for the need for clinical awareness in the early postoperative period, for early management and improvement of functional prognosis.

Introduction

Sciatic palsy is a known complication of fracture-dislocation of the hip surgery [1]. It is a rare but serious complication, and often the cause of prolonged morbidity for patients. There are several posttraumatic, perioperative, and postoperative causes for sciatic nerve palsy. Its incidence is <0.2% [2]. The delayed appearance forms or diagnosed late may be responsible for irreversible neurological damage.

Case presentation

A 38-years-old man with no significant pathological history, with a body weight of 70 kg, was hospitalized in our department for acetabular fracture with dislocation of the of the left hip without sciatic nerve deficit (Figures 1,2).

A surgical reduction under general anesthesia of the dislocation with reduction of the posterior wall of the acetabulum and its fixation by a plate allowed a stable and anatomical reduction of the hip (Figure 3).

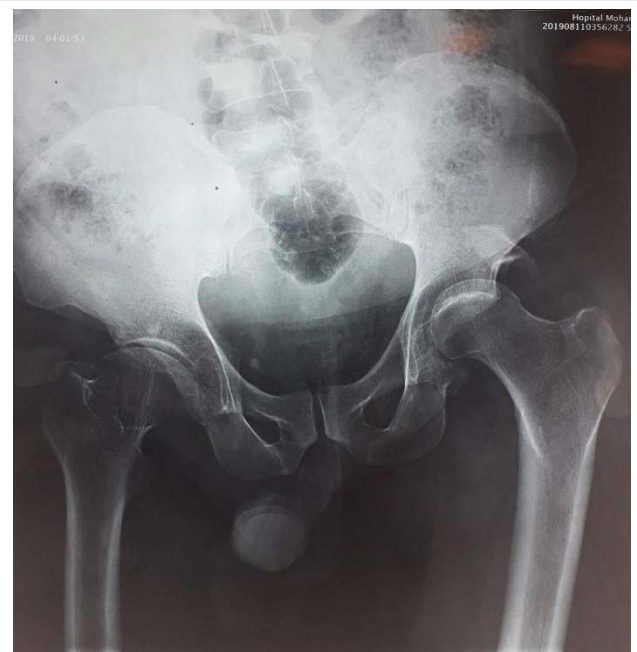

Figure 1: X Ray of acetabular fracture with dislocation of the hip.

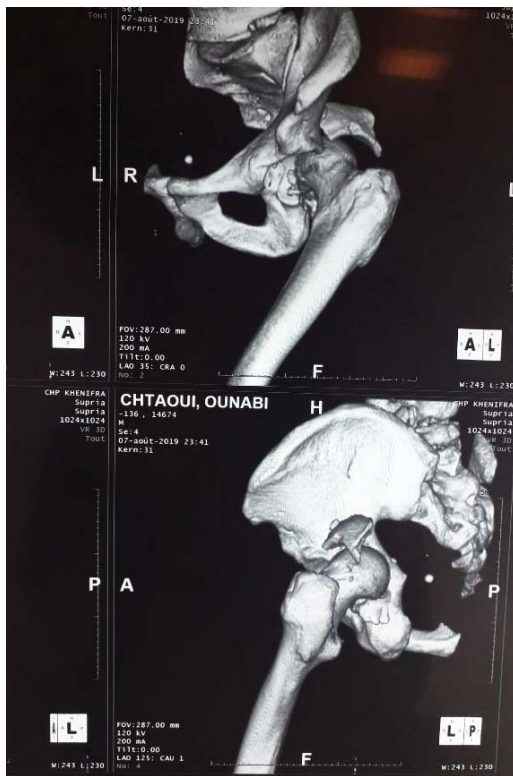


Figure 2: Tomography of acetabular fracture with dislocation of the hip.

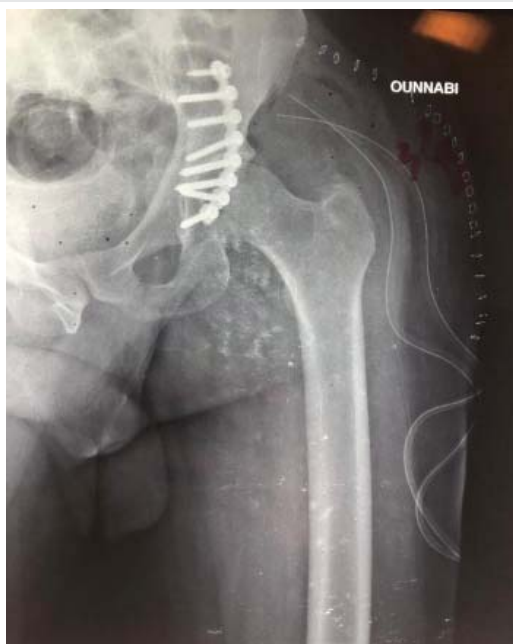

Figure 3: Postoperative control X Ray.

After a short 24-hour stay in surgical resuscitation, the patient received antibiotic prophylaxis, anticoagulation and a transfusion of four globular pellets. At the second postoperative stage, the patient presented a global sensory-motor deficit of the major sciatic nerve. The Computed Tomography (CT) was normal without hematic effusion. The electrophysiological exploration carried out on the third postoperative day found a neurotmesis of the left sciatic nerve.

An anti-equine splint was then prescribed and associated with a functional rehabilitation aimed at maintaining a revival and a muscular trophicity, as well as an articular mobilization of the knee and the ankle. At 14 months of follow-up, the patient presented a total sensory-motor recovery of the posterior tibial nerve and partial area of the anterior fibular nerve. A lateral fibular nerve palsy is always noted, always walking with an anti-equine splint. We are considering a tendon transfer in the coming months.

Discussion

Sciatic nerve paralysis is a known complication of fracture-dislocation of the hip joint surgery. It occurs mainly in the posterior and transtrochanteric areas with an average incidence of 0.8% (0% to 2.8%) [3]. There are several posttraumatic, perioperative, and postoperative causes for sciatic nerve palsy including fracture-dislocation of the hip joint, excessive tension or inappropriate placement of retractors, instrument or implant-related complications, heterotopic ossification, hematoma, and scarring [4]. In the immediate postoperative period, the neurological deficit may be due to a direct injury during manipulation, traction on the sciatic nerve during surgery or thermal damage by cement. The use of a posterior approach has also been implicated as a risk factor. In most patients the actual cause is never determined.

Delayed sciatic paralysis after hip and acetabular surgery is fortunately rare, but can be definitive. They have been reported in the literature [2].

Sciatic nerve palsy associated with acetabular fractures may result from [1] damage at the time of trauma [2], iatrogenic injury during reconstructive surgery, or [5] a late complication of surgery. Posttraumatic causes of sciatic nerve palsy include fracture-dislocation of the hip joint. Iatrogenic causes include intraoperative positioning and placement of retractors, instruments, or implants [6]. Late complications resulting in sciatic nerve injury include wear debris, implant migration, haematoma, capsular or muscular scarring, and heterotopic ossification resulting from the use of extensive approaches [7]. The natural history of sciatic nerve injuries is likely dependent on several factors including the anatomic location of the injury, severity of the injury, chronicity of the injury, patient comorbidities, and age.

Preventive measures include avoiding iatrogenic stretch injury to the nerve by keeping the hip extended and knee flexed during surgery. Retractors should be carefully positioned and extensive posterior retraction with the hip in flexion should be avoided [8]. Instrument or implant placement should be performed safely with the assistance of intraoperative fluoroscopy if necessary. Somatosensory Evoked Potentials (SSEP) and spontaneous Electromyography (EMG) can alert the surgeon to potential nerve injury. Heterotopic ossification prophylaxis is useful for preventing progressive sciatic nerve entrapment [9].

The management of patients depends on the presence of neurological damage at the time of the trauma. Preoperative



nerve damage should lead to explore the nerve during the surgery. In case of postoperative paralysis, an obvious cause should be sought (haematoma, implant migration...) and must lead to surgical exploration. In the absence of an obvious cause of nerve paralysis, clinical and electrophysiological monitoring every 6 months to follow the evolution. Palliative surgery can be proposed in the absence of recovery (tendon transfer) [10].

The prognosis of sciatic nerve palsy after acetabular fracture cannot easily be predicted. A number of factors such as the nature of the original nerve injury and the duration of the insult are important factors in determining its prognosis.

Conclusion

The paralysis of the sciatic nerve after hip and acetabular surgery is a serious and fortunately rare complication. There are several posttraumatic, perioperative, and postoperative causes for sciatic nerve palsy including fracture–dislocation of the hip joint. Increased vigilance in the postoperative period is essential.

References

- Jenkins DB (1998) Hollinshead's functional anatomy of the limbs and back, 7th edn. Saunders, Philadelphia.
- Pokorny D, Jahoda D, Veigl D (2006) Topographic variations of the relationship of the sciatic nerve and the piriformis muscle and its relevance to palsy after total hip arthroplasty. *Surg Radiol Anat* 28: 88-91. [Link: https://bit.ly/39ztKvj](https://bit.ly/39ztKvj)
- Mason WTM, Burgess BM, Villar RN (2000) A little too close to the bone? Risk of sciatic nerve injury during hip arthroplasty. *HIP International* 10: 166-169. [Link: https://bit.ly/3aGPYqa](https://bit.ly/3aGPYqa)
- Brown GD, Swanson EA, Nercessian OA (2008) Neurologic injuries after total hip arthroplasty. *Am J Orthop* 37: 191-197. [Link: https://bit.ly/2R5INH0](https://bit.ly/2R5INH0)
- Benson ER, Schutzer SF (1999) Posttraumatic piriformis syndrome: diagnosis and results of operative treatment. *J Bone Joint Surg Am* 81: 941-949. [Link: https://bit.ly/2x0K9M5](https://bit.ly/2x0K9M5)
- Uchio Y, Nishikawa U, Ochi M (1998) Bilateral piriformis syndrome after total hip arthroplasty. *Arch Orthop Trauma Surg* 117: 177-179. [Link: https://bit.ly/2UScpb0](https://bit.ly/2UScpb0)
- Mounasamy V, Cui Q, Brown TE, Saleh K, Mihalko WM (2008) Acute sciatic neuritis following total hip arthroplasty: A case report. *Arch Orthop Trauma Surg* 128: 25-28. [Link: https://bit.ly/2JCz0Ea](https://bit.ly/2JCz0Ea)
- Sunderland S (1953) The relative susceptibility to injury of the medial and lateral popliteal divisions of the sciatic nerve. *Br J Surg* 41: 300-302. [Link: https://bit.ly/2xGRikO](https://bit.ly/2xGRikO)
- Tornetta P (2001) Displaced acetabular fractures: indications for operative and nonoperative management. *J Am Acad Orthop Surg* 9: 18-28. [Link: https://bit.ly/2R5choa](https://bit.ly/2R5choa)
- Weil Y, Mattan Y, Goldman V, Liebergall M (2006) Sciatic nerve palsy due to hematoma after thrombolysis therapy for acute pulmonary embolism after total hip arthroplasty. *J Arthroplasty* 21: 456-459. [Link: https://bit.ly/2UF2zez](https://bit.ly/2UF2zez)

Discover a bigger Impact and Visibility of your article publication with Peertechz Publications

Highlights

- ❖ Signatory publisher of ORCID
- ❖ Signatory Publisher of DORA (San Francisco Declaration on Research Assessment)
- ❖ Articles archived in worlds' renowned service providers such as Portico, CNKI, AGRIS, TDNet, Base (Bielefeld University Library), CrossRef, Scilit, J-Gate etc.
- ❖ Journals indexed in ICMJE, SHERPA/ROMEO, Google Scholar etc.
- ❖ OAI-PMH (Open Archives Initiative Protocol for Metadata Harvesting)
- ❖ Dedicated Editorial Board for every journal
- ❖ Accurate and rapid peer-review process
- ❖ Increased citations of published articles through promotions
- ❖ Reduced timeline for article publication

Submit your articles and experience a new surge in publication services (<https://www.peertechz.com/submission>).

Peertechz journals wishes everlasting success in your every endeavours.

Copyright: © 2020 Mekkaoui MJEI, et al. This is an open-access article distributed under the terms of the Creative Commons Attribution License, which permits unrestricted use, distribution, and reproduction in any medium, provided the original author and source are credited.

Citation: Mekkaoui MJEI, Boukhris J, Boussaidane M, Chafry B, Bencheba D, et al. (2020) Sciatic nerve injury associated with acetabular fracture (About a case). *J Surg Surgical Res* 6(1): 015-017. DOI: <https://dx.doi.org/10.17352/2455-2968.000088>