

Sibashankar Kar*

Department of Cardiothoracic and Vascular Surgery, Hi-Tech Dental College and Hospital, Bhubaneswar-751010, India

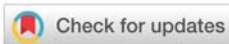
Received: 30 September, 2019

Accepted: 29 October, 2019

Published: 30 October, 2019

***Corresponding author:** Sibashankar Kar, MBBS, DNB, Department of Cardiothoracic and Vascular Surgery, Hi-Tech Dental College and Hospital, Bhubaneswar-751010, India, Tel: 91-8010492022; E-mail: what2talk@gmail.com

<https://www.peertechz.com>



Case Report

Epicardial adipose tissue in a coronary artery disease patient

EAT detected by 2D echocardiography as an echo-free space between myocardium and pericardium, confusing it as pericardial effusion. Usually thickness is measured in atleast two locations on the right ventricular free wall. The epicardial fat is vascularized by branches of the coronary arteries. Epicardial fat thickness is positively correlated with myocardial lipid content and may affect cardiomyocyte function [1].

EAT releases inflammatory adipokines and decrease anti-inflammatory adipokines, hence promote inflammation and CAD [2]. EAT acts as a paracrine organ that influences the coronary arteries by promoting chronic inflammation [3] and endothelial dysfunction [4]. The paracrine effect of segmental pericoronary fat causes atherosclerosis in the local arterial segment [5].

This patient was kept on high intensity statin therapy with strict diabetes control by insulin. Lipid profile on 1 year follow up was controlled. She had been on strict diet and exercise. We believe, very little has been known on EAT and its risk associations which makes this tissue a promising area of research.

References

1. Malavazos AE, Di Leo G, Secchi F, Lupo EN, Dogliotti G, et al. (2010) Relation of echocardiographic epicardial fat thickness and myocardial fat. *Am J Cardiol* 105: 1831-1835. [Link: http://bit.ly/2PrdV3B](http://bit.ly/2PrdV3B)
2. Taguchi R, Takasu J, Itani Y, Yamamoto R, Yokoyama K, et al. (2001) Pericardial fat accumulation in men as a risk factor for coronary artery disease. *Atherosclerosis* 157: 203-209. [Link: http://bit.ly/2PnKCPo](http://bit.ly/2PnKCPo)
3. Baker AR, Silva NF, Quinn DW, Harte AL, Pagano D, et al. (2006) Human epicardial adipose tissue expresses a pathogenic profile of adipocytokines in patients with cardiovascular disease. *Cardiovasc Diabetol* 5: 1. [Link: http://bit.ly/36a4s6x](http://bit.ly/36a4s6x)
4. Aydin H, Toprak A, Deyneli O, Yazici D, Tarcin O, et al. (2010) Epicardial fat tissue thickness correlates with endothelial dysfunction and other cardiovascular risk factors in patients with metabolic syndrome. *Metab Syndr Relat Disord* 8: 229-234. [Link: http://bit.ly/2MW2m2L](http://bit.ly/2MW2m2L)
5. Mahabadi AA, Reinsch N, Lehmann N, Altenbernd J, Kalsch H, et al. (2010) Association of pericoronary fat volume with atherosclerotic plaque burden in the underlying coronary artery: a segment analysis. *Atherosclerosis* 211: 195-199. [Link: http://bit.ly/348RFPX](http://bit.ly/348RFPX)

Thick Epicardial Adipose Tissue (EAT) is not always a finding at operation theatre in patients undergoing Coronary Artery Bypass Grafting (CABG). But epicardial fat has a direct relationship with obesity and metabolic syndrome. Its presence is an independent risk factor for Coronary Artery Disease (CAD). Intraoperative finding is an indicator for post-operative weight reduction and early initiation pharmaceuticals to prevent progression of native vessel disease.

We came across a 46-year diabetic and moderately obese female, presented with history of chest pain. Her coronary angiography showed diffuse triple vessel disease and she underwent CABG. The image (Figure 1) was taken after pericardiotomy. Heart was fully enveloped with a thick yellow layer of epicardial fat with barely seen myocardium. Coronaries were found deeply buried inside the epicardial fat when searched for distal anastomosis, making it a difficult procedure than usual.

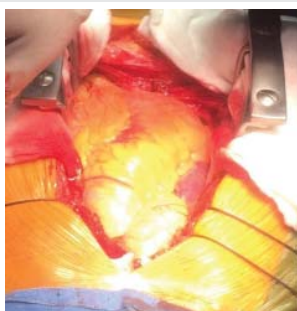


Figure 1: Operative image of heart covered with dense epicardial adipose tissue.

Copyright: © 2019 Kar S. This is an open-access article distributed under the terms of the Creative Commons Attribution License, which permits unrestricted use, distribution, and reproduction in any medium, provided the original author and source are credited.

Citation: Kar S (2019) Epicardial adipose tissue in a coronary artery disease patient. *J Surg Surgical Res* 5(2): 086-086. DOI: <https://dx.doi.org/10.17352/2455-2968.000079>