

Ahmed E Lasheen*

General & Laparoscopic Surgery Department, Faculty of Medicine, Zagazig University Hospital 44519, Egypt

Received: 11 July, 2019

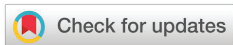Accepted: 07 August, 2019

Published: 08 August, 2019

*Corresponding author: Ahmed E Lasheen, General & Laparoscopic Surgery Department, Faculty of Medicine, Zagazig University Hospital 44519, Egypt, Tel: 0020552343035; E-mail: lasheenahmed@yahoo.com

Keywords: Internal; Lasheen urethral stent

<https://www.peertechz.com>



Research Article

Internal urethral stent (Lasheen urethral stent) for hypospadias repair

Abstract

Background: Hypospadias is a relatively common congenital defect of the male external genitalia. There is much controversy about using of the urethral stent with hypospadias repair. Our study offers new urethral stent (Lasheen urethral stent) to facilitate repair procedure, more comfortable, and improve outcome.

Methods: Twenty seven penile hypospadias cases were subjected to tabularized incised plate (TIP) repair at Zagazig University Hospital, from the period April 2017 to April 2018. Special type of urethral stent which formed of two parts; first one is hard part (piece of ordinary urinary catheter) about 2 cm in length, its diameter 8 or 10 French, and fixed from outside one suture at distal end with long two limbs of Prolene No. 3/0. This suture limbs used to fixed stent at the dorsum of penis by helping needle No. 22. Second part is soft part (piece of soft fine plastic tube) same size of first part, opened only during micturation and collapsed after finishing of voiding, and its length adjusted only to length of neo-urethra to new urethral meatus. Lasheen urethral stent put in place where hard part in normal urethra, soft part in neo-urethra, and distal end of stent just appear at new urethral meatus for two weeks. Broad spectrum antibiotic was given to all patients for one week postoperative. Locally, promote healing agent was used twice daily for two weeks. Follow up period was 12 months for any complications.

Results: Patients ages were ranged from 1.5 to 5 years (mean was 2.7years). The presence of stent in its position was well tolerated by all patients. There is mild skin bluish discoloration of penis which disappear within first week postoperatively. The removal of stent after 2 weeks was easy. Painless, and without any complications by cutting suture limbs from the dorsum of penis and applied traction on the distal stent at the meatus. No urethra-cutaneous fistula or meatal stenosis were observed at follow up period.

Conclusion: The using of Lasheen urethral stent in urethral reconstruction is comfortable, easy for application, no need for much care or nursing, and associated with good results.

Introduction

Hypospadias is common anomaly of penis about 0.4 % of male newborns [1]. Three anomalies were presented in penis in hypospadias case, firstly abnormal ventral opening of the urethral meatus, secondly ventral penis curvature (chordee), and thirdly abnormal distribution of foreskin with a hood dorsally and deficient ventrally [2]. Many procedures were present for correction of hypospadias and all aiming for correction of chordee, creating neo-urethra terminating in a slit-like neo-meatus at the apex of the reconfigured glans [3-6]. For long time, drainage procedures which may be an indwelling bladder catheter to suprapubic cystostomy were considered essential in hypospadias correction [7,8], and changed today for urethral stent [9]. This study is an effort to find type of urethral stent easy for application, comfortable for patient, not need to much

care or nursing, free of complications, and associated with good results.

Patients and methods : This study was included 27 hypospadias cases (15 distal penile, 7 mid penile, 5 proximal penile cases) underwent TIP urethroplasty at Zagazig University Hospital in the period from April 2017 to April 2018. The using procedure as described by Snodgrass [10]. But, special type of urethral stent (Lasheen urethral stent) was used for 2 weeks. This stent was prepared by corresponding author for present study which formed of two parts. First part (hard part), formed of piece of ordinary catheter its size 8 or 10 French, its length about 2 cm, and one suture of Prolene No. 3/0 was fixed near at its distal end with long two suture limbs (15 cm). Second part (soft part), formed of soft fine plastic tube of same caliber of first part, attached to distal end of first part, and its length ranged from 5 to 10 cm figure A. This stent was put in its

place where first part in normal urethra and second part in reconstructed urethra, the excess part of stent which protruded behind neo-meatus was cutting to make stent distal end just appear from meatus. The two suture limbs were passed from normal urethra to appear at the dorsum of penis and tied on small piece of soft rubber to fixed stent in right position for 2 weeks figure B and figure C. Broad spectrum antibiotic was given to all patients for one week postoperative. Locally, promote healing agent was used twice daily for two weeks. Follow up period was 12 months for any complications. After 2 weeks, the stent was removed by cutting suture limbs from the penile skin and applied genital traction on distal end of stent at meatus. Follow up period was 12 months.

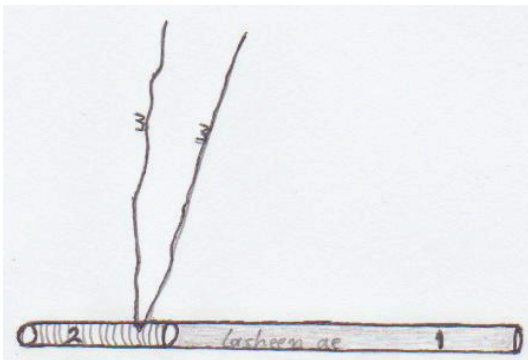


Figure 1A: Lasheen urethral stent. 1-Soft part which put in reconstructed urethra, its length ranged from 5 to 10 cm. 2- hard part which put in normal urethra and its length 2 cm. 3- Two limbs of suture (Prolene 3/0) which fixed at distal end of hard part.

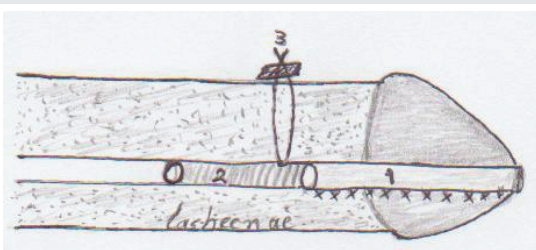


Figure 1B: 1- Soft part of stent was placed in neo-urethra to just protruded from neo-meatus and which open during micturition and collapsed after finishing. 2- Hard part of stent in normal urethra which open continuously. 3- Two limbs of suture were tied on dorsum of penis over small piece of rubber through the tissue of penis.

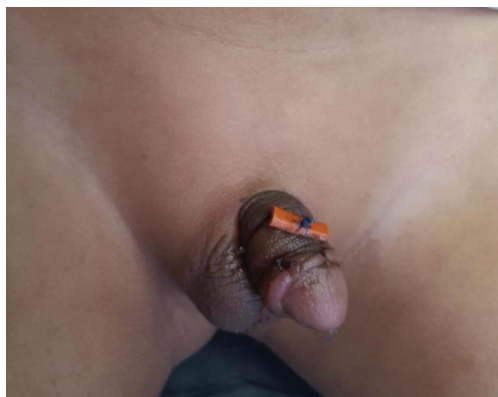

Figure 1C: Lasheen urethral stent was fixed in right position for 2 weeks after mid penile hypospadias repair.

Results

Patients ages were ranged from 1.5 to 5 years (mean was 2.7 years). There is mild bluish discoloration of penile skin, which disappear within one week postoperatively. The passage of suture limbs through normal urethra just proximal of neo-urethra by about 0.5 cm and by using needle No. 22 F. The presence of our stent is well tolerated by all patients (less pain killer consumption, normal patient behavior) without any accident as stent obstruction or removal by patient. The second (soft) part which present inside neo-urethra open during normal voiding only and collapse after finishing. The stent removal is easy, painless, and free of any complications. No urethral or meatus stenosis were observed during period of follow up.

Discussion

The aim of all hypospadias repair procedures is to reconstruct functional neo-urethra with normal anatomy of penis, the TIP method achieved this goal [11,12]. The common complications of hypospadias repair procedures are failure, fistula, and meatal stenosis in percentage ranging from 0 to 33 % [13,14]. Drainage procedures were considered beneficial in hypospadias repair, which vary from indwelling bladder catheter to suprapubic cystostomy. Today urethral stent in form rigid tube of suitable caliber (ranging 8 to 10 French) is placing to across the junction of the normal urethra and reconstructed urethra draining the urine outside during micturition. These traditionally urethral stents were fixed by external suture in glans for 2 weeks postoperatively [15]. There is much controversy about the using of urethral stent increases or decreases the incidence of complications with hypospadias repair procedures [16]. I think traditional urethral stent can increased the complications of hypospadias repair by two factors. First factor, traditional stent is rigid which producing tension on suture line of reconstructed urethra leading to ischemia of neo-urethral edges causing suturing cut-through or urethral fistula or even procedure failure. Second factor, the position of traditional urethral stent outside the new meatus and fixed on the glans causes much discomfort and irritation for patient which try to remove it leading to trauma for neo-urethra and producing complications. This explain why many studies reported that early removal of stent decrease the incidence of complications with hypospadias repair procedures [17]. Our urethral stent (Lasheen urethral stent) was putted inside the urethra where rigid part in normal urethra, soft part in neo-urethra, and extended just to neo-urethral meatus. This position is comfortable for patient. The soft part of Lasheen urethral stent open only during normal micturition and collapsed after finishing, so prevent any tension on suture line of neo-urethra. At same time, our stent prevent passage of urine on neo-urethra and open urethral plate incision until complete healing.

Conclusion

The using of Lasheen urethral stent with hypospadias repair procedures is comfortable, not need to much care and nursing, and associated with good results.

References

- Horowitz M, Salzhauer E (2006) The learning curve in hypospadias surgery. *BJU Int* 97: 593-596. [Link: http://bit.ly/31oewWr](http://bit.ly/31oewWr)
- Mouriquand P, Mure PY (2004) Current concepts in hypospadiology. *BJU Int* 93: 26-34. [Link: http://bit.ly/2YQ8JMM](http://bit.ly/2YQ8JMM)
- Kagantsov IM, Surov RV (2018) Modification of two-stage technique of bracka with preservation and tubularization of the urethral plate for repair of proximal hypospadias. *Urologia* 5: 81-87. [Link: http://bit.ly/2yHlslg](http://bit.ly/2yHlslg)
- Chua ME, Kim JK, Rivera KC, Ming JM, Flores F, et al. (2018) The use of postoperative prophylactic antibiotics in stented distal hypospadias repair: a systemic review and meta-analysis. *J pediatr Urol* 18: 30422-30424. [Link: http://bit.ly/2GT5wko](http://bit.ly/2GT5wko)
- Manuele R, Senni C, Patil K, Taghizadeh A, Garriboli M (2019) Foreskin reconstruction at the time of single-stage hypospadias repair: is it a safe procedure? *Int J Urol Nephrol* 2: 187-191. [Link: http://bit.ly/2ZJ3QBo](http://bit.ly/2ZJ3QBo)
- Kojovic V, Djordjevic ML, Vuksanovic A (2019) Single-stage repair of obliterated anterior urethral stricture using buccal mucosa graft and dorsal penile skin flap. *Int J Urol* 261: 90-95. [Link: http://bit.ly/2TcBgG9](http://bit.ly/2TcBgG9)
- Radwan M, Soliman MG, Tawfik A, Abo-Elenen M, El-Benday M (2012) Does the type of urinary diversion affect the result of distal hypospadias repair? A prospective randomized trial. *Ther Adv Urol* 4: 161-165. [Link: http://bit.ly/2YMV8Vj](http://bit.ly/2YMV8Vj)
- Ghareeb FM, Azooz MA (2001) Hypospadias repair using a modified Foley catheter (hole-end catheter). *Tech Urol* 7: 241-245. [Link: http://bit.ly/2ZMHM96](http://bit.ly/2ZMHM96)
- Chin KY, Burchette D, Uppal R (2013) Urethral stent in hypospadias repair. *J Plast Reconstr Aesthet Surg* 66 1158-1160.
- Snodgrass W (1999) Tubularized incised-plate repair of proximal hypospadias. *BJU International-Supplement* 83: 120.
- Gupta A, Gupta R, Srivastav P, Gupta A (2017) Comparison of interrupted and continuous-suture urethroplasty in tabularized incised-plate hypospadias repair: A prospective study. *Arab J Urol* 15: 312-318. [Link: http://bit.ly/2KnT9is](http://bit.ly/2KnT9is)
- Arshadi H, Sabetkish S, Kajbafzadeh AM (2017) Modified tabularized incised plate urethroplasty reduces the risk of fistula and meatal stenosis for proximal hypospadias: A report of 63 cases. *Int Urol Nephrol* 49: 2099-2104. [Link: http://bit.ly/2Tc6M6U](http://bit.ly/2Tc6M6U)
- Gapany C, Grasset N, Tercier S, Ramseyer P, Frey P, et al. (2007) A lower fistula rate in hypospadias surgery. *J Pediatr Urol* 3: 395-397. [Link: http://bit.ly/2ZHvgY7](http://bit.ly/2ZHvgY7)
- Ritch CR, Murphy AM, Woldu SL, Reiley EA, Hensle TW (2010) Overnight urethral stent after tabularized incised plate urethroplasty for distal hypospadias. *Ped Surg Intern* 26: 639-642. [Link: http://bit.ly/2ZS6ynW](http://bit.ly/2ZS6ynW)
- O'Sullivan O, Bannon CB, Flood H (2006) The Snodgrass repair: is stenting always necessary?. *Ir Med J* 99: 71-73. [Link: http://bit.ly/2GP3pxZ](http://bit.ly/2GP3pxZ)
- Lee LC, Schroder A, Bagli DJ, Lorenzo AJ, Farhat WA, et al. (2018) Stent-related complications after hypospadias repair: a prospective trial comparing silastic tubing and Koyle urethral stents. *J Pediatr Urol* 14: 423-425. [Link: http://bit.ly/2GT0Cnx](http://bit.ly/2GT0Cnx)
- Chua M, Welch C, Amir B, Silangcruz Jm, Ming J, et al. (2018) Non-stented versus stented urethroplasty for distal hypospadias repair: A systematic review and meta-analysis. *J Pediatr Urol* 14: 212-219. [Link: http://bit.ly/2Kk8258](http://bit.ly/2Kk8258)

Discover a bigger Impact and Visibility of your article publication with
Peertechz Publications

Highlights

- ❖ Signatory publisher of ORCID
- ❖ Signatory Publisher of DORA (San Francisco Declaration on Research Assessment)
- ❖ Articles archived in worlds' renowned service providers such as Portico, CNKI, AGRIS, TDNet, Base (Bielefeld University Library), CrossRef, Scilit, J-Gate etc.
- ❖ Journals indexed in ICMJE, SHERPA/ROMEO, Google Scholar etc.
- ❖ OAI-PMH (Open Archives Initiative Protocol for Metadata Harvesting)
- ❖ Dedicated Editorial Board for every journal
- ❖ Accurate and rapid peer-review process
- ❖ Increased citations of published articles through promotions
- ❖ Reduced timeline for article publication

Submit your articles and experience a new surge in publication services
(<https://www.peertechz.com/submission>).

Peertechz journals wishes everlasting success in your every endeavours.

Copyright: © 2019 Lasheen AE. This is an open-access article distributed under the terms of the Creative Commons Attribution License, which permits unrestricted use, distribution, and reproduction in any medium, provided the original author and source are credited.

Citation: Lasheen AE (2019) Internal urethral stent (Lasheen urethral stent) for hypospadias repair. *J Surg Surgical Res* 5(2): 068-070.
DOI: <http://doi.org/10.17352/2455-2968.000075>