

Sivasankaran Nachimuthu*,
Kallappan Senthil and Manickam
Ramalingam

Urology Clinic, Coimbatore, India

Received: 27 March, 2019

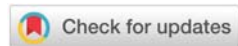
Accepted: 16 May, 2019

Published: 17 May, 2019

*Corresponding author: Sivasankaran Nachimuthu,
Urology Clinic, 3/1054, Gowtham Annexe, Avinashi
road, Coimbatore, 641018, Tel: +919446457770;
E-mail: sivanuro@yahoo.in

Keywords: Post-mortem alcohol; Brain alcohol;
Alcohol; Gastric alcohol; Alcohol

<https://www.peertechz.com>



Case Report

Large Prostatic Calculus in an Alkaptonuria patient – Caught unaware

Abstract

Alkaptonuria, a metabolic disorder with urological manifestation goes unnoticed till we are aware of it. Here we present an alkaptonuric patient with difficult catheterisation was diagnosed with a large prostatic calculus and his management.

Introduction

Alkaptonuria is a rare inherited metabolic disorder involving the serum homogentisic acid levels. Most of the people affected have varied presentations. Very rarely genitourinary system is involved. Prostatic calculi and black coloured urine are the urological presentations of this condition.

Case Report

55 years old male a known case of Alkaptonuria, recently underwent left hip replacement surgery. He developed urinary retention just after surgery. Per urethral catheterisation was attempted but could not be passed and hence cystoscopy was done. To our surprise cystoscopy showed a calculus in prostatic fossa that could not be pushed back into bladder and suprapubic catheterisation (SPC) was done. Xray Pelvis revealed speckled calcification behind pubic symphysis. Cystolitholapaxy was planned electively (Figure 1). Cystoscopy after 3 weeks revealed large prostatic urethral calculus of size of 2.5cms. As the stone could not be pushed into urinary bladder, it was fragmented with laser energy in prostatic fossa into small fragments. After 120 minutes of fragmentation, the fragments were pushed into bladder and washed out. Patient had a stable post operative period. Stone fragments were analysed which showed bilirubin and cholesterol. His urine was positive for alkaptonuria. Xray spine revealed multilevel intervertebral disc calcification with severe narrowing of the intervertebral disc spaces and associated anterior osteophytes along the lumbar vertebrae. His catheters were removed on POD 5 and was voiding with Qmax of 15ml/sec.

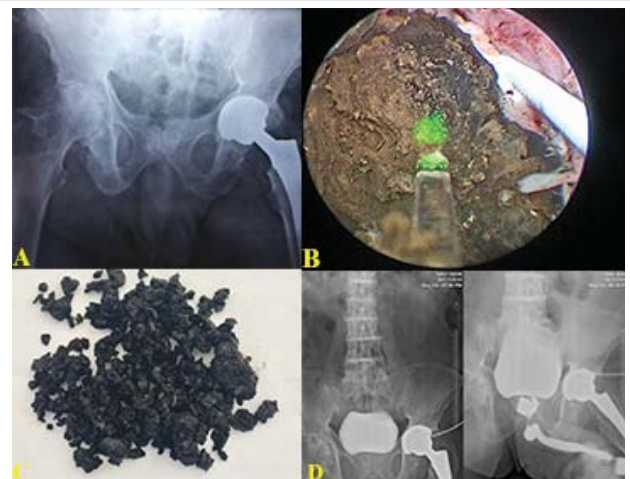

Figure 1: A. Xray Pelvis, B. Stone fragmentation with laser, C. Stone fragments, D. Post operative cysto-urethrogram.

Discussion

Alkaptonuria is a rare metabolic disorder first described by Sir Archibald Edward Garrod; who first used the expression, 'inborn errors of metabolism', to describe four rare disorders - alkaptonuria, albinism, cystinuria and pentosuria. He discovered that such disorders resulted from enzymatic defects in the catabolic pathways of aminoacids and sugars [1,2]. Autosomal recessive mutations of the homogentisic acid (HGA)oxidase gene, located on human chromosome 3q 21-q 23, results in a defect in the metabolism of homogentisic acid [2]. There is accumulation of homogentisic acid in patients with alkaptonuria. Oxidation of this acid leads to formation of a blackish melanin like pigment which is selectively deposited

in the connective tissue and cartilage. Though pediatric alkaptonuria is rare, it has been reported. Generally symptoms become apparent around third to fourth decade. The common clinical presentation for alkaptonuria include pigmentation of the sclera, pinnae and nasal ala; musculoskeletal abnormalities like narrowing of the joint spaces, cartilage degeneration and the calcifications of the disc leading to loss of lumbar lordosis; exaggerated thoracic kyphosis, ankylosis and loss of height; change of the color of the urine to black on exposure to air, renal and prostatic calculi; cardiac valve calcification and stenosis [3].

Urine excretion of homogentisic acid (alkapton) is very high and has high propensity for stone formation [2,3]. Very rarely alkaptonuria patients end up in renal failure. There have been similar reports of prostatic calculi and alkaptonuria in the past [4,5], with the detection of majority of the prostatic calculi being either incidental or with lower urinary tract symptoms. Prostatolithiasis in alkaptonuria is of two types – true prostatolithiasis with deposition of calculi in the prostatic gland and false prostatolithiasis with the location of calculi being in pars prostatica urethrae [5]. In our case the calculus was in the pars prostatica. The formation of calculi is secondary to the accumulation of homogentisic acid which precipitates the deposition of crystals. The composition of the prostatic and renal calculi is usually the standard constituents such as calcium oxalate monohydrate and dihydrate [5], but in our case it was bilirubin and cholesterol which again is very unusual. Symptomatic prostatic calculi in alkaptonuria has been reported is limited to a similar case report where the patient presented with features of chronic prostatitis [6] and was managed conservatively.

The patient discussed had cutaneous manifestations like ochronosis in the palms and sclera which were asymptomatic (Figure 2) similar to a case report [7], where patient had a hard prostate mimicking carcinoma but had extensive calculi deposition. Our patient had bothersome lower urinary tract symptoms due to large prostatic calculus but was not on treatment till he had to be catheterised in post operative period. Homogentisic acid in urine was positive to confirm the

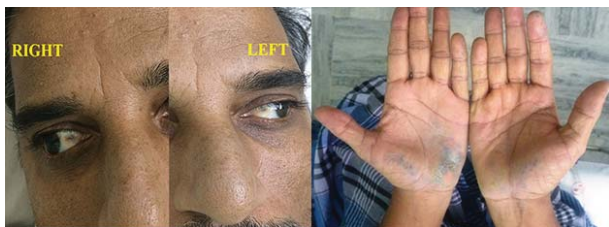

Figure 2: Ochronosis of sclera and palms.

diagnosis. He was relieved of his symptoms after the removal of the prostatic calculus. Similar case reports [8,9], have been published who were managed successfully with endourological procedures.

There are therapeutic options for patients who have been diagnosed with alkaptonuria like dietary restriction of protein, vitamin c supplementation but are not usually effective. Nitisinone a herbicide, inhibits 4- hydroxy phenyl pyruvate dioxygenase and decreases the formation of homogentisic acid. Nitisinone therapy may effectively reduce HGA levels. In addition to long term monitoring for efficacy and safety, it also requires lifelong treatment. Only symptomatic management is presently available and periodic evaluation of bone and joints, kidney, prostate and cardiac complications is advisable [3].

Conclusions

This rare case highlights the need for suspicion of prostatic calculus in an alkaptonuria patient and role for surgical management in such cases. To our knowledge this is the first report of surgical laser lithotripsy in-situ of a large alkaptonuric calculus in the prostatic urethra.

References

1. Phornphutkul C, Introne WJ, Perry MB (2002) Natural history of alkaptonuria. *N Engl J Med* 347: 2111-2121. Link: <https://tinyurl.com/y5cx434d>
2. Scriver CR (2008) Garrods Croonian lectures (1908) and the charter "Inborn Errors of Metabolism": Albinism, alkaptonuria, cystinuria and pentosuria at age 100 in 2008. *J Inher Metab Dis* 31: 580-598. Link: <https://tinyurl.com/y39c96p9>
3. Keller JM, Macaulay W, Necessian OA (2005) New developments in ochronosis: Review of the literature. *Rheumatol Int* 25: 81-85. Link: <https://tinyurl.com/y694cvbw>
4. Strimer RM, Morin LJ (1977) Renal, vesical, and prostatic calculi associated with ochronosis. *Urology* 10: 42-43. Link: <https://tinyurl.com/y5l8k52c>
5. Krizek V (1971) Urolithiasis and prostatolithiasis in alcaptonuria with ochronosis. *Int Urol Nephrol* 3: 245-250. Link: <https://tinyurl.com/y2ew2stu>
6. Decramer A, Van Der Eecken H, Vanhoucke JL (2006) Ochronosis of the prostate, a possible cause of chronic prostatitis? *Tijdschrift voor Geneeskunde* 62: 385-389. Link: <https://tinyurl.com/y4485eoe>
7. Suarez GM, Roberts JA (1983) Ochronosis of prostate presenting as advanced carcinoma. *Urology* 22: 168-171. Link: <https://tinyurl.com/y3yze3w2>
8. Sridhar FK, Mukha RP, Kumar S (2012) Lower urinary tract symptoms and prostatic calculi: A rare presentation of alkaptonuria. *Indian J Urol* 28: 219-221. Link: <https://tinyurl.com/y3gkb8c3>
9. Gaurav Sali, Appu Thomas, Nilil Kumar (2015) Extensive prostatic calculi in alkaptonuria: An unusual manifestation of rare disease. *Asian Journal of Urology* 2: 179-181. Link: <https://tinyurl.com/y6pc393f>