



**Sweta Kumari<sup>1</sup>, Savith Kumar<sup>2\*</sup> and Mugdha Timble Kamath<sup>1</sup>**

<sup>1</sup>Resident (Radiology). Department of Radiology Apollo hospitals, Bannerghatta road, Bangalore -560076, India

<sup>2</sup>Associate Consultant (Neuroradiology and Intervention). Apollo hospitals, Bannerghatta road, Bangalore-560076, India

**Received:** 05 April, 2018

**Accepted:** 28 April, 2018

**Published:** 30 April, 2018

**\*Corresponding author:** Savith Kumar, DM, Associate Consultant (Neuroradiology and Intervention). Apollo Hospitals, Bannerghatta Road, Bangalore, India. E-mail: [major.savith@gmail.com](mailto:major.savith@gmail.com)

**Keywords:** Intraventricular cavernoma; Lateral ventricle; Blooming

<https://www.peertechz.com>

**Case Report**

**Intraventricular Cavernoma**

**Abstract**

Intraventricular cavernomas (IVC) are rare entities. We report a case of incidentally detected intraventricular cavernoma (IVC) in frontal horn of the lateral ventricle in which the diagnosis was established by typical magnetic resonance imaging (MRI) features. The patient has been kept on follow up as surgical resection is not recommended in asymptomatic cavernomas. IVC should be considered in differentials of intraventricular mass to avoid unnecessary invasive diagnostic procedures and inefficient management of this benign lesion.

**Introduction**

Cerebral cavernomas are most commonly identified brain vascular malformation majority of which are located in the brain parenchyma. Intraventricular cavernomas are rare accounting for 2.5–10.8% of cerebral cavernomas [1]. They are detected incidentally or may present with a headache, seizures, hemorrhage, hydrocephalus or neurological deficits. These could be misdiagnosed as intraventricular neoplasm on imaging, and cavernomas needs to be considered in the differential of an intraventricular mass. We report a case of incidentally detected intraventricular cavernoma in which diagnosis was established on the base of key imaging features thus avoiding unnecessary intervention.

**Case Report**

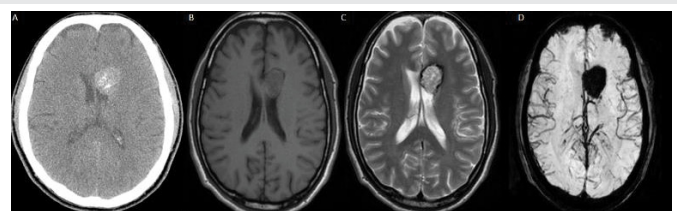
A 48-year male undergoing evaluation for right vocal cord palsy is incidental detected to have an intraventricular mass. Nonenhanced computed tomography(CT) demonstrated a mildly lobulated well circumscribed 2.5cm, hyperdense mass with foci of calcifications in the frontal horn of the left lateral ventricle (Figure 1A). On MRI the lesion appeared isointense on T1, heterogeneously hyperintense on T2 with thin hypointense rim and blooming on Gradient echo (GRE) sequence (Figure 1B–D). Contrast-enhanced images showed minimal heterogeneous enhancement. No significant diffusion restriction observed. There is no perilesional edema, associated hydrocephalus, mass effect or midline shift. No other intraparenchymal focal lesion or foci of GRE blooming artifact or other vascular malformation observed in rest of the brain.

**Discussion**

Cavernomas are benign vascular malformation, which is found in all age groups with no sex predilection. The prevalence in the general population is 0.02 to 0.13% and accounts to 5 to

13% of the central nervous system vascular malformations [2]. IVC are uncommon entities comprising 2.5–10.8% of all brain cavernous malformations [1], and only about 136 well-documented cases have been published [3]. The lateral ventricles are the most frequent site followed by third and fourth ventricle [4].

Pathologically cavernomas are discrete multilobulated berry like lesion that contains hemorrhage in various stages of evolution. Histologically cavernomas are composed of closely approximated endothelial lined sinusoidal spaces with insignificant intervening neural tissue [3]. In IVC most common symptom is due to mass effect followed by hemorrhage and seizure. Presence of hydrocephalus depends upon the location of the lesion. The estimated annual risk of hemorrhage in supratentorial cavernoma is about 0.25-0.7% [7]. In a study by Kivlev et al. 14% of IVC presented with intraventricular



**Figure 1:** Axial Non enhanced CT (A) reveals a mildly lobulated well circumscribed hyperdense mass with foci of calcifications in the frontal horn of the left lateral ventricle. MRI: Axial T1 (B) the lesion appeared isointense. Axial T2 (C) the lesion appears heterogeneously hyperintense with thin hypointense rim. Axial GRE (D) demonstrates blooming within the lesion.

hemorrhage and showed a higher tendency for rebleeding [5]. IVC attain a larger size than their parenchymal counterpart as the intraventricular location allows for unrestricted growth and their increased tendency for intralesional rebleed [2].

On imaging, IVC may appear similar to the intraparenchymal cavernoma. They are hyperdense on noncontrast CT and calcification is common. They show a core of mixed-signal intensities and a low signal rim that blooms on T2 and GRE. Contrast enhancement is variable [3].

Imaging differentials of intraventricular mass in adults includes central neurocytoma, subependymoma, meningioma, subependymal giant cell astrocytoma and metastasis [6].

Central neurocytoma is typically lateral ventricular mass attached to the septum pellucidum. It is usually hypodense on nonenhanced CT. Punctate calcifications are common. Cystic regions and intratumoral hemorrhage are common in large tumors. They demonstrate hypointense signal on T1W, and isointense to hyperintense signal with a bubbly appearance on T2W sequences and contrast enhancement is variable [6]. Intraventricular meningiomas are located in trigon of the lateral ventricle in about 85% of cases. Sharply demarcated rounded or lobulated lesions with low T2 signal intensity, intense homogeneous enhancement, and moderate diffusion restriction are key features [6]. Subependymomas are well demarcated isodense partially calcified lesions on noncontrast CT with intense contrast enhancement. Heterogeneous T1W and hyperintense T2W signal are MRI features [6]. Subependymal Giant cell astrocytoma is most common cerebral neoplasm in tuberous sclerosis appearing as enhancing mass near the foramen of Monro [6]. Renal, colon, and lung cancers are usually the most common primaries in adults causing intraventricular secondaries [6].

T2 weighted central hyperintensity representing methemoglobin, peripheral hypointense rim corresponding to the paramagnetic effect and gliotic reaction to the hemosiderin, intense GRE blooming and lack of T2/FLAIR perilesional edema suggests the diagnosis of cavernoma and limits the differentials of other neoplasms. Lack of avid contrast enhancement excludes other intraventricular vascular malformations. IVC are angiographically occult lesion which may be seen as avascular mass causing a mass effect. Occasionally a faint blush can be seen at late capillary or early venous phase [3].

Complete surgical excision is the treatment of choice. Lateral ventricle cavernomas are excised through transcortical or interhemispheric transcallosal approach. Surgical resection is not recommended for asymptomatic cavernomas especially if located in eloquent, deep and brainstem areas [7].

In our case, as the lesion was incidentally detected, and the patient was asymptomatic he was considered to be kept on follow up.

## Conclusion

IVC are uncommon entities with wide differentials. Key imaging features are peripheral hyperintense rim on T2W, and blooming artifact on susceptibility weighted imaging favor the diagnosis of intraventricular cavernomas

## References

1. Nigri F, Viana JDS, Pinto FPHDC, Simões EL, Ribeiro TCR (2018) Microsurgical Treatment of Intraventricular Cavernoma with Prior Planning Neuroendoscopy. *Case Rep Neurol* 10: 1-6. [Link: https://goo.gl/B4yS9v](https://goo.gl/B4yS9v)
2. Faropoulos K, Panagiotopoulos V, Partheni M, Tzortzidis F, Konstantinou D (2015) Therapeutic management of intraventricular cavernoma: Case series and review of the literature. *J Neurol Surg A Cent Eur Neurosurg* 76: 233-239. [Link: https://goo.gl/fzFDbc](https://goo.gl/fzFDbc)
3. Shirvani M, Hajimirzabeigi A (2017) Intraventricular Cavernous Malformation: Review of the Literature and Report of Three Cases with Neuroendoscopic Resection. *J Neurol Surg A Cent Eur Neurosurg* 78: 269-280. [Link: https://goo.gl/icKw7P](https://goo.gl/icKw7P)
4. Beechar VB, Srinivasan VM, Reznik OE, Sen A, Klisch TJ, et al. (2017) Intraventricular Cavernomas of the Third Ventricle: Report of 2 Cases and a Systematic Review of the Literature. *World Neurosurg* 105: 935-943. [Link: https://goo.gl/L2KFnm](https://goo.gl/L2KFnm)
5. Kivelev J, Niemelä M, Kivisaari R, Hernesniemi J (2010) Intraventricular cerebral cavernomas: a series of 12 patients and review of the literature. *J Neurosurg* 112:140-149. [Link: https://goo.gl/N4mCyd](https://goo.gl/N4mCyd)
6. Vandestein L, Drier A, Galanaud D, Clarençon F, Leclercq D, et al. (2013) Imaging findings of intraventricular and ependymal lesions. *J Neuroradiol* 40: 229-244. [Link: https://goo.gl/K6qBPR](https://goo.gl/K6qBPR)
7. Akers A, Dahlem K, Flemming K, Hart B, Kim H, et al. (2017) Synopsis of Guidelines for the Clinical Management of Cerebral Cavernous Malformations: Consensus Recommendations Based on Systematic Literature Review by the Angioma Alliance Scientific Advisory Board Clinical Experts Panel. *Neurosurgery* 80: 665-680. [Link: https://goo.gl/RXvG9W](https://goo.gl/RXvG9W)