

Rajvilas Anil Narkhede<sup>1\*</sup> and Snehal Ashok Naphade<sup>2</sup>

<sup>1</sup>Department of Surgical Gastroenterology, Global hospital, Lakdi Ka Pul, Hyderabad, India

<sup>2</sup>M V P Medical College, Nasik, Maharashtra, India

**Dates:** Received: 20 June, 2016; Accepted: 02 July, 2016; Published: 04 July, 2016

\*Corresponding author: Dr. Rajvilas Anil Narkhede, Pushpanjali, Shemba, Nandura, Buldana, Maharashtra, 440103, India, Tel: +918897389898; E-mail: rajvilas.narkhede@gmail.com

www.peertechz.com

ISSN: 2455-2968

**Keywords:** Pancreatic siphon; Distal spleno-renal shunt; Intra-pancreatic collaterals; Spleno-pancreatic disconnection; Selective shunt

## Review article

# Pancreatic Siphon: A Major determinant of selective shunts. Is it a Historical Entity now?

### Abstract

Surgical management of portal hypertension has changed according to time, evolving from just complete shunts to selective shunts and to liver transplantation. The outcomes also greatly improved owing to better understanding of portal hemodynamics and disease nature. Introduction of selective shunts showed promising results just to be challenged by poor outcome with development of "pancreatic siphon" which then studies in detail. This intra-pancreatic and peri-pancreatic collateral veins which connected portal and splenic veins formed basis of systemic loss of portal flow and thus ending up in failure of selectivity. Pancreatic siphon was found to be associated with increased rates of hepatic encephalopathy post selective shunting along with increased rates of hepatic failure. In addition to this pancreatic siphon led to metabolic sequel like new onset of diabetes, ischemic or compressive pancreatic ductopathy and intrapancreatic cholangiopathy. Although the shunting procedures are not that commonly done, pancreatic siphon has moved out of the limelight. It was just an attempt of recapping the existence of an unfamiliar entity forming delicate balance in the portal circulation.

## Introduction

Treatment of portal hypertension has evolved greatly over last few decades. Of these Distal spleno-renal shunt (DSRS) was found to provide long lasting solution to the problem. DSRS was based on the idea that esophageal and gastric varices will be decompressed into renal vein via short gastric vessels and spleen after disconnecting coronary vein at the same time maintaining hepatopetal flow in mesentericoportal circulation and supply of hepatotropic factors to liver [1]. But over time the shunt showed loss of this selectivity and showed increased rates of hepatic failure secondary to loss of portal flow from portal circulation to systemic circulation through peri-pancreatic and intra-pancreatic surgery. The 'pancreatic siphon' term gained its existence only after the popularisation of distal spleno-renal shunt. It was found to be the communication between mesenterico-portal and the disconnected gastrosplenic compartments. This pancreatic and peripancreatic venous collaterals decompressing portal circulation into splenic vein after DSRS is said to be "pancreatic siphon".

## What is exactly "Pancreatic siphon"?

Large collaterals leave the portal vein into the head of the pancreas, drain through the body and tail of the pancreas via intrapancreatic branches that communicate directly with the shunt distal splenic vein [2]. In 65.79 % anatomical pieces studied by Piras C et al., showed that the veins of the pancreatic tail flowed in segmentary branches of the splenic vein. These branches could be responsible for the loss of distal spleno-renal shunt selectivity [1]. Since the portal system is valve less; retrograde flow through this siphon is possible; away from portal system to the shunt (Figure 1).

## Does it exist or its a sequel?

The intra-pancreatic venous network does exist in normal healthy individuals measuring 1 - 3 mm sizes longitudinal venous

radicals connecting portal and splenic circulations [3]. Furthermore in response to pathology like portal venous thrombosis and splenic venous thrombosis these collaterals tend to dilate and decompress respective compartments [3]. So development of pancreatic siphon is natural response of persistent elevated pressure in the mesenterico-portal circulation over the intra-pancreatic and peri-pancreatic venous channels after splenic venous division and DSRS. Even such intra-pancreatic collaterals are seen in portal venous thrombosis with or without liver cirrhosis, without any clinically significant mass effect [4]. Ligation of coronary vein is a crucial step in creation of DSRS, failure of which can hasten the collateralisation and early formation of pancreatic siphon effect [5]. This intra-pancreatic collateral network along with coronary vein helps in decompressing gastrosplenic compartment in inferior mesenteric-renal shunt which is a rare type of selective shunt [2]. The alcoholic patients, cirrhotics and post hepatitis patients were found to be specially prone for the development of pancreatic siphon [6], following selective shunts and porto-splenic thrombosis.

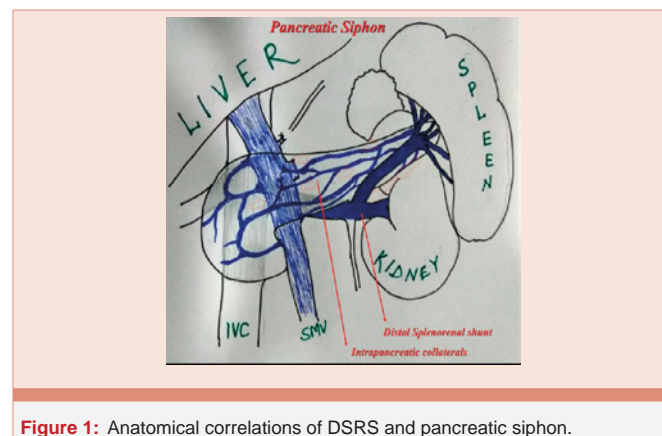


Figure 1: Anatomical correlations of DSRS and pancreatic siphon.

Disconnection of splenic vein from portal circulation in the form of portal thrombus extending to splenic vein also led to formation of intra-pancreatic and peri-pancreatic cavernous collaterals in similar manners like DSRS [7].

### Systemic effects of “Pancreatic Siphon”

Portal circulation is a delicate system affected by even minor changes in the pressure dynamics. Development of pancreatic siphon leads to many metabolic and portal circulatory changes.

**Loss of hepatotrophic factors:** Loss of hepatotropic factors, including insulin, was found to be one of the factors responsible for development of hepatic insufficiency over time. Warren et al., estimated significant loss of arginine stimulated insulin in patients who developed pancreatic siphon following selective shunt [5]. Loss of the pancreatic hormones, which are having important contribution in hepatic regeneration and the prevention of hepatic atrophy; thus predisposing for early hepatic atrophy and deranged hepatic regeneration [2].

**Hepatic function:** Liver functional status also showed changes over time following changes in portal hemodynaemics. Quantitative hepatic function per unit blood flow assessed by galactose clearance, also showed significant decrease in patients who lost portal flow due to pancreatic siphon effect [5]. Also the decrease in quality of blood perfusing liver, containing hepatotropic factors, insulin and pancreatic hormones was observed in alcoholics only; whereas non-alcoholic cirrhotics were refractory for such changes [5].

**Portal flow:** Loss of portal flow is seen frequently in alcoholics and cirrhotics (60% to 91%) by 1-2yrs of selective shunt like DS [6,8-11]. This loss of portal flow was attributed to decompression through intra pancreatic and peri-pancreatic venous collaterals to systemic circulation through renal vein and was associated with decreased survival in such patients [5].

**Portal vein diameter:** Portal venous diameter showed remarkable narrowing by 1 year of DSRS (8% - 30% patients) whereas 50% patients had significant narrowing by 5 years [12]. Orozco, H et al., observed reduction in the diameter of the portal vein in 8% patients with portal hypertension operated by selective shunt who developed the so-called pancreatic siphon with striking occurrence in patients of alcoholic cirrhosis (33%) [2].

### Consequences of pancreatic siphon

**Loss of selectivity:** This loss of selectivity of the DSRS in alcoholic was attributed to loss of portal perfusion from the so called “pancreatic siphon’ was proven in multiple studie [8]. Over period selective shunts starts behaving as complete shunts as a consequence of pancreatic siphon. Thus interruption of this pancreatic siphon forms an integral component in maintaining selectivity of shunt. On the other hand results of selective shunts in hetrogenous population showed nature of underlying liver disease and cirrhosis was responsible for this loss of portal perfusion and in turn the shunt selectivity rather than the decompression from the intra-pancreatic collaterals [13].

**Decreased survival in alcoholics and cirrhotic patients:** The 4-year survival in alcoholics after standard DSRS has varied from 40% to 65%, noticed by Henderson et al. 1989 [9], which was worse as

compared to non-alcoholics. Similarly mortality and actual survival was better in non-alcoholics as compared to alcoholic patients in accordance to studies by Warren et al., and Zeppa et al. [14,15], but there was no significant difference between nonalcoholic cirrhotics and alcoholic cirrhosis. Subsequently cirrhosis was found to be one of the dominating determinant of long term prognosis in these patients [11].

**Portal venous thrombosis:** Although DSRS was designed to maintain portal perfusion, portal thrombosis was not an uncommon squeal, with an incidence of about 10% - 14% [16,17], secondary to loss of portal flow, stasis and flow reversal.

**Hepatic encephalopathy:** The incidence of clinically significant post shunt hepatic encephalopathy was 16% in a study by J. Albertus Myburgh, but surprisingly nonalcoholic cirrhotics had increased incidence of porto-systemic encephalopathy as compared to alcoholic cirrhotic patients (19% Vs 16%) [13]. Hence we can consider increased encephalopathy rates after selective shunt were more dependent on the cirrhotic status of the liver than the alcoholic etiology of the portal hypertension. But sparingly reported cases of persistent porto-systemic encephalopathy secondary to loss of portal perfusion attributed to pancreatic siphon, showed improvement of encephalopathy status immediately after ligation of pancreatic siphon and shunt itself [18]. Also loss of portal flow through pancreatic siphon led to portal hypoperfusion and portal venous thrombosis which was found to be precipitating factor for porto-systemic encephalopathy.

**Progressive Diabetes mellitus:** Nozoki et al., observed occurrence new onset diabetes mellitus along with encephalopathy after DSRS which reversed on shunt ligation [18]. This could be explained by inability of pancreatic insulin, pancreatic hepatotropic factors reaching the liver and in turn inability of the liver to utilize the glucose.

**Other uncommon complications:** Even such long standing intra-pancreatic collateralisation can lead to cavernous transformation and may present rarely as pancreatic ductopathy or cholangiopathy because of ischemic or mass effect [19]. Decompensation in orthotrophic liver transplantation does occur in patients with selective shunt secondary to decreased portal flow; frequently complicated by portal venous thrombosis [16]. This dilated pancreatic venous collaterals can be confused as cystic neoplasm which can be easily differentiated on Doppler scan.

### Management

Assessment of pathophysiology of the disease, portal hemodynamics and the condition of the liver needs special attention in the management of patients with portal hypertension. Pancreatic siphon is a sequel which is easy to prevent than to treat. In the era where shunt surgery are on the decline, liver transplantation has taken over largely as a treatment of portal hypertension with liver cirrhosis when decompensation is frequent. Still porto-systemic shunts do have role in when liver function is fairly intact and can form a bridge to transplant when the indications are not sufficient. Even properly selected shunt when timely done in properly chosen patient can give a long term survival.

## Distal splenorenal shunt with splenopancreatic disconnection (DSRS + SPD)

Addition of splenopancreatic disconnection to DSRS reduced the incidence of decompression to portal circulation through peripancreatic and intra-pancreatic collaterals and in turn reduced the incidence of hepatic encephalopathy and liver failure in short term. The occurrence of loss of selectivity of DSRS was more commonly seen in alcoholic patients as high as 75% by the end of 1 year [20], which DSRS + SPD showed to reduce. But study by J. Albertus Myburgh, showed increased incidence of loss of prograde portal perfusion after 1 year in alcoholics (23%) consistent with previous studies [13]. But addition of SPD to DSRS was not shown to improve this loss of prograde portal perfusion [13].

In patients with schistosomal etiology, DSRS + SPD showed long term relief from variceal bleeding, hepatic encephalopathy and additionally they had statistically significant less chronic hyperbilirubinemia as compared to DSRS alone [21].

### Modified DSRS

DSRS with external iliac vein graft without spleno-pancreatic disconnection was done with minimal splenopancreatic dissection and with relatively easier technique. It was found more suitable in maintain the hepatopedal prograde portal flow and in turn maintaining the selectivity of the shunt [22]. This selectivity was even long lasting when gastric disconnection was added, further reducing diversion of portal flow from gastric wall [23].

### Radiological embolization

With advancements of interventional radiology, obliteration of these collaterals forming the pancreatic siphon was done successfully with aid of transhepatic catheterization which showed good results [14,24].

### Low diameter meso-caval interposition shunt (LDMIS)

LDMIS was developed as a partial shunt, maintain the prograde portal perfusion and was proved to maintain prograde portal perfusion in long duration with bleeding free follow up [5,25]. This can be adopted in selected cases where suitability of DSRS is doubtful.

### Liver transplantation and pancreatic siphon

Patients with failed selective shunt, especially DSRS, secondary to pancreatic siphon and progressive deterioration of liver function can be treated with Liver transplantation successfully and such shunts do not hinder the transplant reconstructions [17] provided that intraoperative dismantling of shunt is done [16].

### Conclusion

Surgical management of portal hypertension needs a combined thought over clinical condition of patient including liver status, pattern of collateralisation, presence of thrombosis and its pattern and proper selection of shunt. Case selection and individualisation of shunting procedure are the key to successful long term management of portal hypertension.

## References

1. Piras C, Paulo DNS, Paulo ICAL, Rodrigues H, Silva AL da (2010) Venous drainage from the tail of the pancreas to the lienal vein and its relationship with the distal splenorenal shunt selectivity. *Acta Cir Bras* 25: 105-110.
2. Warren WD, Millikan Jr. WJ, Henderson JM, Rasheed ME, Salam AA (1984) Selective variceal decompression after splenectomy or splenic vein thrombosis. With a note on splenopancreatic disconnection. *Ann Surg* 199: 694-702.
3. Hongo N, Mori H, Matsumoto S, Okino Y, Ueda S, et al. (2010) Anatomical variations of peripancreatic veins and their intrapancreatic tributaries: Multidetector-row CT scanning. *Abdom Imaging* 35: 143-153.
4. Durualp E, Bekta G, Ergin D, Karaca E, Topçu E (2011) Annelerin Sigara Kullanımı ile Yenidoğanın Doğum Kilosu, Boyu ve Baş Çevresi Arasındaki İlişkinin İncelenmesi 64: 119-126.
5. Wright AS, Rikkers LF (2005) Current management of portal hypertension. *J Gastrointest Surg* 9: 992-1005.
6. Orozco H, Takahashi T, Mercado MA, Gonzalez-Lopez-Lira A, Hernandez-Ortiz J (1992) Intermittent changes in portal venous flow in relation with spleno-pancreatic collaterals--"the pancreatic siphon"--after a selective shunt in a patient with idiopathic portal hypertension: case report. *Surgery* 111: 105-108.
7. Vilgrain V, Condat B, O'Toole D, Plessier A, Ruszniewski P, et al. (2009) Pancreatic portal cavernoma in patients with cavernous transformation of the portal vein: MR findings. *Eur Radiol* 19: 2608-2613.
8. Warren WD, Millikan Jr. WJ, Henderson JM, Abu-Elmagd KM, Galloway JR, et al. (1986) Splenopancreatic disconnection. Improved selectivity of distal splenorenal shunt. *Ann Surg* 204: 346-355.
9. Henderson J, Warren W (1986) A method of measuring quantitative hepatic function and hemodynamics in cirrhosis: The changes following distal splenorenal shunt. *Surg Today*. Springer Japan 16: 157-168.
10. Warren WD, Whitehead JB (1986) Recent advances in the management of variceal bleeding. *Surg Today* 16: 77-83.
11. Ezzat FA, Abu-Elmagd KM, Sultan AA, Aly MA, Fathy OM, et al. (1989) Schistosomal versus nonschistosomal variceal bleeders. Do they respond differently to selective shunt (DSRS)? *Ann Surg* 209: 489-500.
12. Isomatsu T (1983) Loss of selectivity of warren shunt in long-term observation. *Surg Today* 13: 202-206.
13. Myburgh JA (1990) Selective shunts: The Johannesburg experience. *Am J Surg* 160: 67-74.
14. Warren WD, Henderson JM, Millikan WJ, Galambos JT, Brooks WS, et al. (1986) Distal splenorenal shunt versus endoscopic sclerotherapy for long-term management of variceal bleeding. Preliminary report of a prospective, randomized trial. *Ann Surg* 203: 454-462.
15. Zeppa R, Hensley GT, Levi JOEU, Bergstresser PR, Hutson DG, et al. (1976) The Comparative Survivals of Alcoholics Versus Nonalcoholics After Distal Splenorenal Shunt 510-513.
16. Shapiro RS, Varma C V, Schwartz ME, Miller CM (1997) Splenorenal shunt closure after liver transplantation: intraoperative Doppler assessment of portal hemodynamics. *Liver Transpl Surg* 3: 641-642.
17. Orozco H, Mercado MA, Granados JG, Hernandez-Ortiz J, Tielve M, et al. (1997) Selective shunts for portal hypertension: Current role of a 21-year experience. *Liver Transplant Surg* 3: 475-480.
18. Nozaki H, Shimada T, Fukushima Y, Inou T, Takeda Y (1998) Successful surgical treatment for hepatic encephalopathy caused by a pancreatic siphon: Report of a case. *Surg Today*. Springer Japan 28: 1069-1072.
19. Sharma M, Rameshbabu CS (2014) Portal cavernoma cholangiopathy: An endoscopic ultrasound based imaging approach. *J Clin Exp Hepatol*. Elsevier Ltd 4: S53-61.



20. Collins JC, Rypins EB, Sarfeh IJ (1994) Narrow-diameter portacaval shunts for management of variceal bleeding. *World J Surg.* Springer New York 18: 211–215.
21. Abu-Elmagd KM, Ezzat FA, Fathy OM, El-Ghawby NA, Aly MA, et al. (1991) Should both schistosomal and nonschistosomal variceal bleeders be disconnected? *World J Surg.* Springer New York 15: 389–397.
22. Kato K, Kondo S, Morikawa T, Okushiba S, Katoh H (1999) Selective distal splenorenal shunt without requiring splenopancreatic disconnection with the use of the external iliac vein graft: A preliminary report. *Surgery Mosby* 126: 577–580.
23. Katoh H, Shimozawa E, Kojima T, Tanabe T (1989) Modified splenorenal shunt with splenopancreatic disconnection. *Surgery* 106: 920–924.
24. Warren WD, Millikan WJ, Henderson JM, Wright L, Kutner M, et al. (1982) Ten years portal hypertensive surgery at Emory. Results and new perspectives. *Ann Surg* 195: 530–542.
25. Paquet K, Mercado M, Klingele H, Klingele R (1991) Investigation of the portal perfusion index after low diameter mesocaval interposition and distal splenorenal shunt — a prospective study. *Surg Endosc* 5: 204–208.

**Copyright:** © 2016 Narkhede RA, et al. This is an open-access article distributed under the terms of the Creative Commons Attribution License, which permits unrestricted use, distribution, and reproduction in any medium, provided the original author and source are credited.

**Citation:** Narkhede RA, Naphade SA (2016) Pancreatic Siphon: A Major determinant of selective shunts. Is it a Historical Entity now?. *J Surg Surgical Res* 2(1): 039-042. DOI: 10.17352/2455-2968.000029