

Ahmed E Lasheen\*, Ramadan Mahmoud, Osama abd Elaziz, Mohammed Alkilany, Tamer Alnaimy and Tamer Rushdy

General and Laparoscopic Surgery Department, Faculty of Medicine, Zagazig University, 44519, Egypt

**Dates:** Received: 29 April, 2016; Accepted: 03 June, 2016; Published: 04 June, 2016

\***Corresponding author:** Ahmed E Lasheen, MD, General and Laparoscopic Surgery Department, Zagazig University Hospital, Zagazig City, Egypt, Tel: + 20552343035; Fax: +20552307830; E-mail: lasheenahmed@yahoo.com

[www.peertechz.com](http://www.peertechz.com)

**ISSN:** 2455-2968

**Keywords:** Skin sparing fistulectomy; Special sutures; High perianal fistula

## Case Report

# Skin Sparing Fistulectomy with Primary Sphincters Repair by Special Sutures for Management of High Perianal Fistula

### Abstract

**Background:** Fistula in ano is a common disease seen in the surgical outpatient department. Many procedures are advocated for the treatment of fistula in ano. However, none of the procedures is considered the gold standard. Aim of this study was to evaluate our procedure in the managing high perianal fistula.

**Methods:** Between February 2014 and September 2015, 71 patients with high perianal fistula were managed by skin sparing fistulectomy and special sutures for primary repair of anal sphincters. The clinical outcome was assessed in terms of time for healing, continence and recurrence for follow-up period (ranged from 4 to 24 months).

**Results:** Anorectal wounds were healed within 3 to 4 weeks. Complications included urine retention 9 patients (12.7 %), superficial wound infection 29 patients (40.9 %), and transient incontinence 33 patients (46.5 %) for flatus for period ranged from 2 to 3 weeks. No deep infection, no permanent incontinence were recorded. Recurrence was in one patient (1.4 %).

**Conclusion:** Our technique is less invasive, rapid healing, maintain on normal configuration of anus, and associated with good results for high perianal fistula management.

## Introduction

Perianal abscess and fistulas represent two stages of same disease. The main etiology is cryptoglandular. Perianal abscess and fistulas are two of the oldest human surgical entities [1]. A fistula in ano is a common perianal condition that is associated with appreciable morbidity and inconvenience to the patient [2]. The objectives of treatment are to achieve fistula healing, prevent recurrences and maintain on anal sphincter function. The risk of incontinence associated with treatment ranged from 10% to 57% [3]. The disease has an incidence of 8.6 per 100 000 people and nearly 20 000 to 25000 fistulas are treated annually in the United States [1]. The incidence of fistula after perianal abscess is 27% to 60% [4]. Conventional classification and treatment depends on the level of the internal opening and extent of involvement of the external sphincter by the fistulous tract [5,6]. Traditionally, a “complex fistula” is defined by a high risk of recurrence or incontinence following treatment. Broadly, complex fistulas are those that are not low trans-sphincteric or inter-sphincteric fistulas. The surgical options for these fistulas include fibrin application, plug placement, endorectal advancement flap, fistulectomy with primary sphincter repair, partial fistulectomy seton placement, ultra-low anterior resection and coloanal anastomosis, the ligation of the inter-sphincteric fistula tract and video assisted fistula tract procedure [7]. In this study, skin sparing fistulectomy and repair of anal sphincters by special sutures in high perianal fistula management, surgical procedure and clinical results were discussed.


## Patients and Methods

Between February 2014 and September 2015, seventy one patients (54 males and 17 females) with high perianal fistula were included in this study. This research was discussed and approved from Ethical Committee of Zagazig University in January 2014. All information about this technique was discussed with all patients, and all patients gave writing consent for inclusion of their data in this study. The median age was 43.7 years (range 21 to 63 years). Eleven patients (15.5%) had previously undergone one or more repair attempts before referral for this technique (all patients subjected to core fistulectomy and endorectal advancement flap, and 5 patients trial to use fibrin injection after recurrence). Every patient was subjected to careful digital examination and trans-rectal endosonography to determine the number and site of fistula tract. All patients were continent before our technique. The patients were underwent a mechanical bowel preparation, and received systemic antibiotic preoperative and continue for 7 days postoperative. Under general or spinal anesthesia, the patient was placed in the lithotomy position. The external, internal openings, and fistula tract were located. Injection of colored material (Methylene blue) through the external opening is helping to detect the fistula tract and internal opening. Skin sparing fistulectomy was done through multiple transverse incisions. First incision is around the external opening, the opening and fistula tract were dissected until reaching highest possible point. Then, another transverse incision is made and dissection of fistula tract resumed until reaching

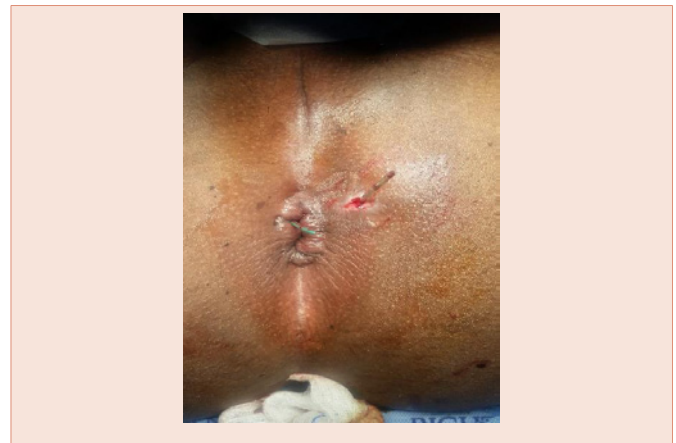the mucocutaneous junction. From the mucocutaneous junction to internal opening, fistulectomy was done through longitudinal incision in anorectal mucosa and anal sphincters close and complete. Then, repair of anal sphincters and wound was done from endoanal by multiple double incomplete circular sutures (buried sutures) by using Vicryl No. 2/0 on round needle. The needle with Vicryl was passed from one edge of wound through the sphincters muscles, under the wound floor, and another edge of sphincters muscles until reaching to other wound edge. Then, returned in opposite direction to starting point by same manner with distance between two sutures limbs about 0.5 cm. Now, one suture becomes complete and two suture limbs were held by tissue forceps (Figures 1a-c and Figures 2a-e). The distance between each suture and other was about 0.5 cm. to put both edges of sphincters and wound close to each other when tying them. Number of sutures were used according the length of the wound, where were tied them making the wound and muscles edges in contact to each other. So, primary repair of the anal sphincters and wound was achieved by buried sutures without forming closed space, which allows for free drainage of the wound through all length and depth. Local wound care was continuous in form of wound cleaning and application of topical ointment contains local anesthetic and promotes healing agents. The follow up period was ranged from 4 to 24 months (mean was 18 months) for any anal complications.

**Results**

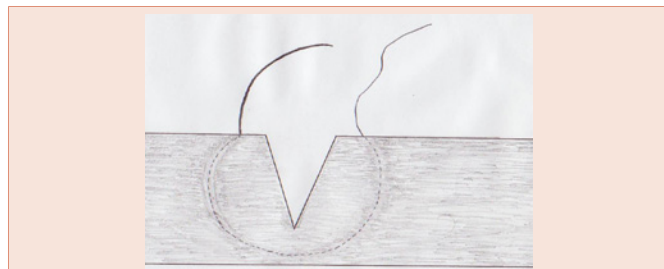
This technique was done under general anesthesia in 60 patients and 11 patients under spinal anesthesia. The selection of the type of



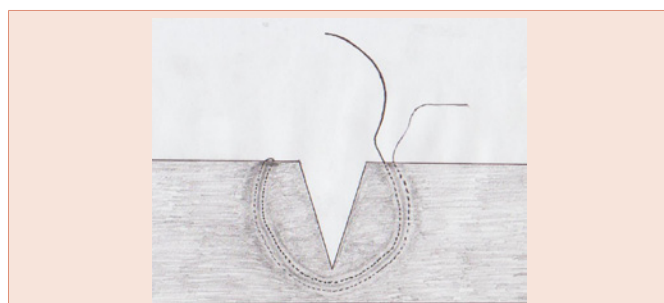
**Figure 1c:** The buried suture was tied. The both muscles sphincters ends are in contact to each other without producing closed space. This repair is allowing to drain the wound through all length and depth of the wound.



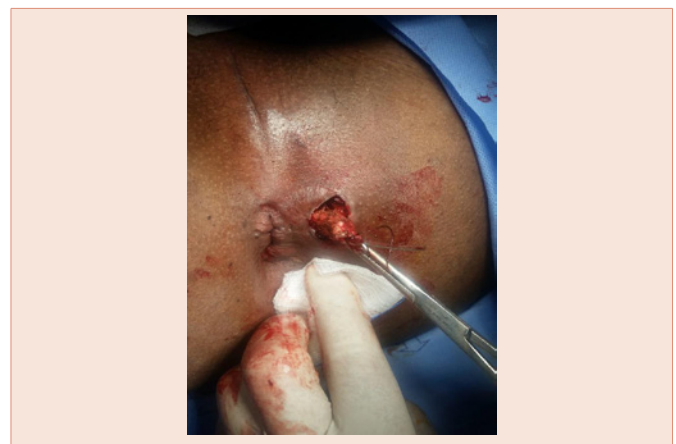**Figure 2a:** One patient suffering from recurrent high perianal fistula in lithotomy position. The fistula tract was identified and small plastic tube inside it through external opening and appeared from internal opening.



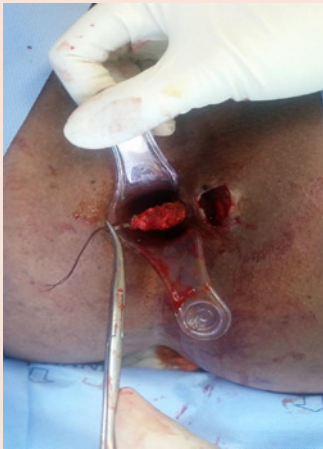**Figure 1a:** The needle with Vicryl No. 2/0 were passed from one wound side, through one muscles sphincters end, under the wound floor and other muscles sphincters end to appear from another side of wound.



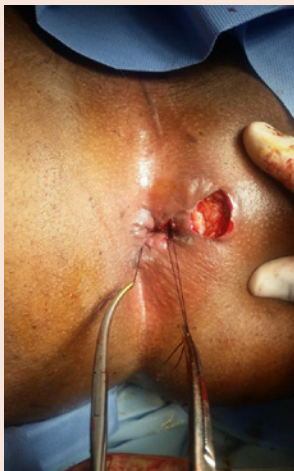**Figure 1b:** The needle with the Vicryl return in opposite direction by same manner to put the other limb of suture beside the first limb with about 5 mm distance between them. The two sutures limbs were hold by tissue forceps before putting next suture.



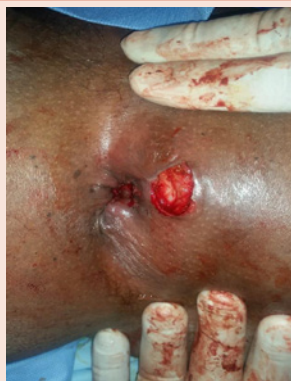**Figure 2b:** The dissection of the tract started by curved incision around external opening and advanced high as possible.



**Figure 2c:** Second incision at the mucocutaneous junction was made and the tract was pushed to come from this incision. Then, the fistula tract dissection was continuous until internal opening through dividing muscles fibers.



**Figure 2d:** Primary repair of muscles sphincters by multiple buried sutures were achieved.



**Figure 2e:** The buried sutures were tied, producing good repair of anal sphincters without forming closed wound.

anesthesia was related to factors other than the high perianal fistula. The primary repair of anal sphincters and wound by buried sutures must be started at the upper end and finished at lower outer end. The two limbs of each suture must be passed at big distance about 3 cm from both edges of anal sphincters muscles and just under the wound floor. The sutures were tied only after finishing of putting all needed sutures and their ting start with sutures present at upper end of wound. The anorectal wound and anal sphincters were healed within 3 to 4 weeks. Early complications included urine retention in 9 patients (12.7%), superficial infection in 29 patients (40.9%), and transient incontinence in 33 patients (46.5%) for flatus for period ranged from 2 to 3 weeks. No permanent or deep infection or abscess formation were recorded during period of follow up. One (1.4%) patient from 11 recurrent cases showed recurrent perianal fistula after 2 months of operation, which treated by same technique after three months of recurrence.

## Discussion

Fistula in ano produces a constant strain on the patient as well as on the surgeon. The most widely used classification for fistula in ano is the Park classification, which distinguishes four kinds of fistula: intersphincteric, transsphincteric, suprasphincteric and extrasphincteric [8]. Fistulae are also be classified as low fistula and high fistula, depending on the level of the internal opening below or above the anorectal ring [9]. There are many surgical procedures advocated for fistula in ano, ranging from simply laying open the tract to colostomy. Fistulectomy and fistulotomy are the most widely accepted procedures performed for the management of low perianal fistula with minimal involvement of the anal sphincter [10]. But, fistulectomy or fistulotomy produces longitudinal wound at the perianal skin which take more time to heal and may be leading to keyhole deformity. The treatment of high perianal fistula is directed at identification of the fistulous tract and internal opening, excision of the fistulous tract and closure of internal opening [10]. The use of fibrin glue injection for treatment of fistula in ano is described with advantages of its reproducibility. The long-term success rates range from 14% to 69% [9,11]. The transanal rectal advancement flap technique is described for treatment of high perianal fistula. This procedure is intended to preserve the continence mechanism by avoiding sphincter injury. It is a complex procedure with florid recurrence rates that range from 6% to 41% in various studies [12,13]. The rate of postoperative anal incontinence from these techniques is reported to be around 9% to 38% [14,15]. Ligation of intersphincteric fistula tract comprises ligation and division of the fistulous tract in the intersphincteric space, curettage of the tract, and suture ligation of the external opening. The success rate reported in various studies range from 57% to 94.5%. There was no reported morbidity in the form of fecal incontinence [16-18]. The use of stem cells derived from adipose tissue in conjunction with the fibrin plug for the treatment of high anal fistula has also been described, with a reported success rate of 71% [19]. Video-assisted anal fistula treatment was reported with recurrence rate 26.5% [20]. Seton is other optional treatment for high perianal fistula, the seton placement has been advocated either loose, to control infection, or cutting through the sphincter muscle gradually [21]. Incontinence still continues to complicate seton

treatment, through it is projected as sphincter saving procedure and the reasons for this could be hard gutter shaped scars, loss of anal sensations. The use of seton in modern day practices is restricted [22]. Successful management of high perianal fistula depends on complete and close fistulectomy and good management of internal opening. Fistulectomy can be done by minimally invasive technique plus closure of internal opening [13], which is difficult especially in branched or curved fistula tract leading to high recurrence rate with low incidence of incontinence. Some researchers reported hematoma after fistulectomy [23,24], but this complication not recorded with our study because the buried sutures produced good hemostasis and not leading to closed wound allowing for free drainage. Fistulectomy can be achieved by open technique which is easy to follow all fistula tracts producing extensive perianal wound, with much injury for anal sphincters leading to low recurrence rate and high incidence of incontinence. Primary repair of anal sphincters is essential with open fistulectomy, but repair by traditional method needs to fecal diversion (colostomy) and produces closed space leading to extensive wound infection. In our technique, fistulectomy is done by open technique, but through skin sparing technique producing minimal perianal wound. Also, primary repair of anal sphincters is done by special sutures (buried suture) which putting the sphincters muscles ends in contact without producing closed space and no need for fecal diversion. In spite the rate of incontinence was 46.5 % in our technique, but this type of incontinence was temporary for gas only and complete cured within 2 to 3 weeks. All patients were continence after this healing period. Also, the rate of wound infection was 40.9%, but this infection was superficial not associated by deep infection or abscess formation and not affect the final outcomes of our technique. In our technique, the fistulectomy is achieved through special technique (skin sparing technique) producing minimal perianal wound and primary sphincters repair by buried sutures leading to rapid healing without need to fecal diversion.

## Conclusion

Our technique offers novel technique for management of high perianal fistula associated with good results in form of rapid healing, less recurrence rate and no permanent incontinence.

## References

- Blumetti J, Abcarian A, Quinteros F, Chaudhry V, Prasad L, et al. (2012) Evolution of treatment of fisula in Ano. *World J Surg* 36: 1162-1167.
- Mishra A, Shah S, Nar AS, Bawa A (2013) The role of fibrin glue in the treatment of high and low fistulas in Ano. *J Clinical and Diagnostic Research* 5: 876-879.
- Jacob TJ, Perakath B, Keighley MR (2010) Surgical intervention for anorectal fistula. *Cochrane Database Syst Rev* 5: 6319.
- Abcarian H (2011) Anorectal infection: abscess-fistula. *Clin Colon Rectal Surg* 24: 14-21.
- Lewis A (1986) Excision of fistula in ano. *Int J Colorectal Dis* 4: 265-267.
- Kodner IJ, Mazor A, Shemesh EI, Fry RD, Fleshman JW, et al. (1993) Endorectal advancement flap repair of rectovaginal and other complicated anorectal fistulas. *Surgery* 114: 682-689.
- Vergara-Fernandez O, Espino-Urbina LA (2013) Ligation of intersphincteric fistula tract: What is the evidence in a review? *World J Gastroenterology* 40: 6805-6813.
- Parks AG, Gordon PH, Hardcastle JD (1976) A classification of fistula in ano. *Br J Surg* 63: 1-12.
- Kochhar G, Saha S, Andley M, Kumar A, Saurabh G, et al. (2014) Video-assisted anal fistula treatment. *JLS* 18: 127-132.
- Sentovich SM (2003) Fibrin glue for anal fistulas: long-term results. *Dis Colon Rectum* 46: 498-502.
- Sonoda T, Hull T, Piedmonte MR, Fazio VW (2002) Outcomes of primary repair of anorectal and rectovaginal fistulas using the endorectal advancement flap. *Dis Colon Rectum* 45: 1622-1628.
- Lashen AE (2004) Partial fistulectomy and fistular wall flap for the treatment of high perianal fistulas. *Surg Today* 11: 977-980.
- Schouten WR, Zimmermann DD, Briel JW (1999) Transanal advancement flap repair of transsphincteric fistulas. *Dis Colon Rectum* 42: 1419-1423.
- Mizrahi N, Wexner SD, Zmora O, Da Silva G, Efron J, et al. (2002) Endorectal advancement flap: are there predictors of failure? *Dis Colon Rectum* 45: 1616-1621.
- Rojanasakul A (2009) LIFT procedure: a simplified technique for fistula-in-ano. *Tech Coloproctol* 13: 237-240.
- Bleier JI, Moloo H, Goldberg SM (2010) Ligation of the intersphincteric fistula tract: an effective new technique for complex fistulas. *Dis Colon Rectum* 53: 43-46.
- Shanwani A, Nor AM, Amri N (2010) Ligation of the intersphincteric fistula tract (LIFT): a sphincter-saving technique for fistula-in-ano. *Dis Colon Rectum* 53: 39-42.
- Garcia-Olmo D, Herreros D, Pascual I, Pascual JA, Del-Valle E, et al. (2009) Expanded adipose-derived stem cells for the treatment of complex perianal fistula: a phase II clinical trial. *Dis Colon Rectum* 52: 79-86.
- Meinero P, Mori L (2011) Video-assisted anal fistula treatment (VAAFT): a novel sphincter-saving procedure for treating complex anal fistulas. *Tech Coloproctol* 4: 417-422.
- Nwaejike N, Gilliland R (2007) Surgery for fistula-in-ano: an audit of practice of colorectal and general surgeons. *Colorectal Dis* 8: 749-753.
- Ege B, Leventoglu S, Menten BB, Yilmaz U, Oner AY (2014) Hybrid seton for the treatment of high anal fistulas: results of 128 consecutive patients. *Tech Coloproctol* 18: 187-193.
- Akhar M (2012) Fistula in Ano - An Overview. *JIMSA* 1: 53-55.
- Jivapaisarnpong P (2009) Core out fistulectomy, anal sphincter reconstruction and primary repair of internal opening in the treatment of complex anal fistula. *J Med Assoc Thai* 5: 638-642.
- Hirschburger M, Schwandner T, Hecker A, Kierer W, Weinel R, et al. (2014) Fistulectomy with primary sphincter reconstruction in the treatment of high transsphincteric anal fistulas. *Int J Colorectal Dis* 2: 247-252.

**Copyright:** © 2016 Lasheen AE, et al. This is an open-access article distributed under the terms of the Creative Commons Attribution License, which permits unrestricted use, distribution, and reproduction in any medium, provided the original author and source are credited.

**Citation:** Lasheen AE, Mahmoud R, abd Elaziz O, Alkilany M, Alnaimy T, et al. (2016) Skin Sparing Fistulectomy with Primary Sphincters Repair by Special Sutures for Management of High Perianal Fistula. *J Surg Surgical Res* 2(1): 035-038. DOI: 10.17352/2455-2968.000028