



## Case Study

# Hematocolpos on imperforated hymen and acute urinary retention A rare disease About seven observations and literature reviews

M Lahfaoui\*, H Benhaddou and F Ettaybi

Department of Pediatric Urovisceral Surgery, Faculty of Medicine and Pharmacy, Mohamed-Premier University, CHU Mohamed VI, Oujda, Morocco

Received: 24 April, 2020

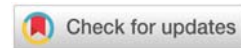
Accepted: 04 May, 2020

Published: 05 May, 2020

\*Corresponding author: M Lahfaoui, Department of Pediatric Urovisceral Surgery, Faculty of Medicine and Pharmacy, Mohamed-Premier University, CHU Mohamed VI, Oujda, Morocco, E-mail: mohammedlahfaoui@gmail.com

Keywords: Hematocolpos; Hymenal imperforation; Acute urinary retention

<https://www.peertechz.com>



## Abstract

Hymenal imperforation is a fairly rare malformation, and severe when ignored. Based on the literature data on this malformation, a retrospective study was conducted on 7 cases of haematocolpos on imperforated hymen, collected to the uro-visceral pediatric surgery departments, Children's Hospital, Oujda-Rabat (MOROCCO), over a period from January 2011 to January 2019. It appears from this work that this anomaly is the prerogative of patients in the peripubertal period. The clinical signs is dominated by abdominal and pelvic pain. The existence of an abdominal-pelvic tumefaction in all our patients and by urinary complications such as acute urine retention in 3 of our 7 cases. The diagnosis is mainly clinical and is oriented by ultrasound. Hymene imperforation remains the most frequent etiology, it is found in our 7 patients, The surgical treatment is simple carried out on an incision of the obturating diaphragm, and a drainage of the collection.

## Introduction

Hymenal imperforation is a relatively rare but the most common congenital malformation of the female genital tract (1). It is often isolated but sometimes associated with malformations of the urogenital tract (2).

Painful cryptomenorrhoea by parapubertal hymenorrhoea is the most classic telltale picture (3). Non-gynecologic symptoms sometimes mislead the diagnosis.

Hymenal imperforation is easily diagnosed by inspection of the external genitalia. Ultrasonography has simplified the analysis of this rare pathology, and is the best method for early diagnosis thanks to in utero ultrasound.

Hymenotomy is the treatment of hematocolpos by hymenal imperforation. For hematocolpos revealing malformations, the treatment of the causal malformation is more complex.

Early diagnosis and treatment of hymeal imperforation is

important in order to improve the prognosis and avoid any tubal sequelae.

In our work, we report a series of seven Hymenal imperforations.

## Case reports

### a) Case 1

13 year old patient, admitted for management of an acute abdominal picture with the notion of cyclic pain for five months. She has not had her menarche, but has developed sexual characteristics (breasts at S4 and pubic hair at P5). Examination showed a slight bulging of the hymen and the recto-vaginal septum. Ultrasound showed hematocolpos. Surgical incision of the Y-shaped hymen allowed 600 milliliters of black blood to be drained. The evolution is favourable at the follow-up examination of the patient after three weeks. A forensic certificate of medical loss of virginity is given to the family.

### b) Case 2

15-year-old patient admitted to pediatric emergency department for cyclical pelvic pain for 9 months with exacerbation of pain for 7 days without urinary signs with pelvic mass of 12cm, at ultrasound the uterus is in place measuring 9.3/5.1 cm regular with endocavitary fluid retention finely echogenic communicating via the cervical os with hematosalpinx. Treated through an O incision, it consists of excising a small central collar of the hymen through which a Foley catheter is inserted. The balloon of the catheter is inflated to 10 cm<sup>3</sup> and the catheter is removed after 2 weeks. Drain 1200cc of black blood. The evolution is satisfactory. A medical-legal certificate of medical loss of virginity is given to the family.

### c) Case 3

A 14-year-old patient admitted to the pediatric emergency department with pelvic pain 9 days prior to admission with complicated acute urinary retention since 18:00 on abdominal and pelvic examination, there was a 12-cm mobile renal pelvic mass with a bladder globe (Figure 1), good external genital development and secondary sexual characteristics with a bluish, bulging, imperforate hymen (Figure 2). An emergency ultrasound scan was performed to show a hematocolpos with right hematosalpinx (Figure 3). a Y-shaped incision of the hymen with drainage of 500 cc of blackish blood plication of the flaps with vicryl 6(0) to the wall placement of a 16ch bladder catheter in the vagina for 7 days .evolution without stenosis .the orifice was dilated once a week for 1 month then once every two weeks then once every three months. A medical-legal certificate of medical loss of virginity is given to the family.

### d) Case 4

Patient, 13 years and 6 months old, admitted for management of an acute abdominal picture with the notion of

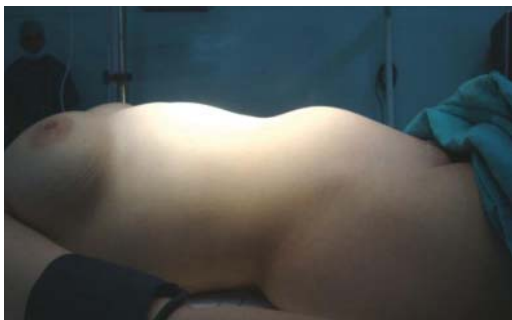


Figure 1: The preoperative clinical aspect of the abdominal vaulting.

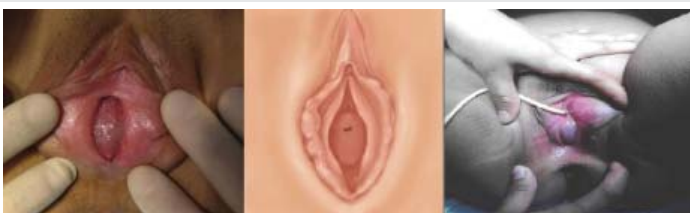

Figure 2: Pre-operative photos of an imperforate hymen with a bulging hymen.

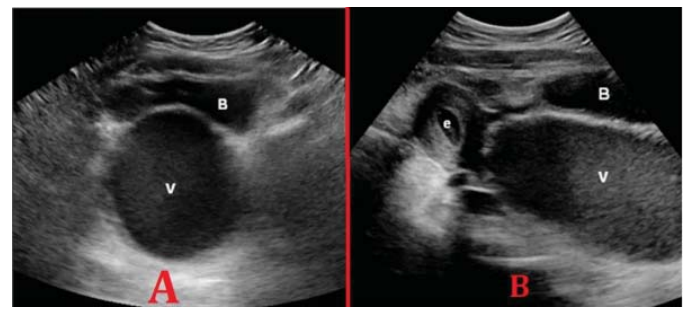


Figure 3: Ultrasound aspect of hematocolpos.

Axial (A) and longitudinal (B) ultrasound images of the lower abdomen of a 13-year-old patient with abdominal and back pain, showing a thin-walled cystic mass (V) anterior to the bladder (B) of 13.7 (long axis) × 5.6 (short axis) × 5.2 (front-to-back) cm and containing echogenic fluid, representing a distended vagina. There is also fluid containing echogenic material in the distended endometrial cavity (e). The results are typical of the hematocolpometre due to obstruction of the vagina, leading to retrograde menstruation.

cyclic pain for four months. She has not had her menarche, but has developed sexual characteristics, with a first-degree (sister) family history of hematocolpos.

Examination showed a slight bulging of the hymen and the recto-vaginal septum. Ultrasound revealed hematocolpos. Surgical incision of the Y-shaped hymen allowed 500 milliliters of blackish blood to be drained. Dilatation was performed every 10 days after discharge, once a week, then once a fortnight, then once a month. The evolution is favourable at the time of the patient's follow-up examination after three months. A medical-legal certificate of loss of virginity is given to the family.

### e) Case 5

A 14-year-old patient admitted to the pediatric emergency department for pelvic pain dating back 2 days before her complicated admission with acute urinary retention for 12 hours on examination of the abdomen showed an oval-shaped suprapubic swelling, with a large upper extremity, regular contours, fluctuating or renal consistency, sensitive, matt to percussion, and plunging down behind the pubic symphysis. Inspection of the vulva allows recognition of imperforation by showing a bluish translucent membrane protruding between the labia minora with good development of the external genitalia and secondary sexual characteristics. An ultrasound scan performed urgently to show a haematocolpos. A Y incision of the hymen with drainage of 600 cc of blackish blood plication of the flaps with vicryl 7(0) to the wall placement of a bladder probe 18ch in the vagina for 7 days .an evolution without stenosis .the orifice was dilated once a week for 1 month then once every two weeks then one every three months. A medical-legal certificate of medical loss of virginity is given to the family.

### f) Case 6

Thirteen-year-old patient admitted to the pediatric emergency department for pelvic pain dating back 4 days before her admission with complicated acute urine retention since 12 hours. On abdominal and pelvic examination, there

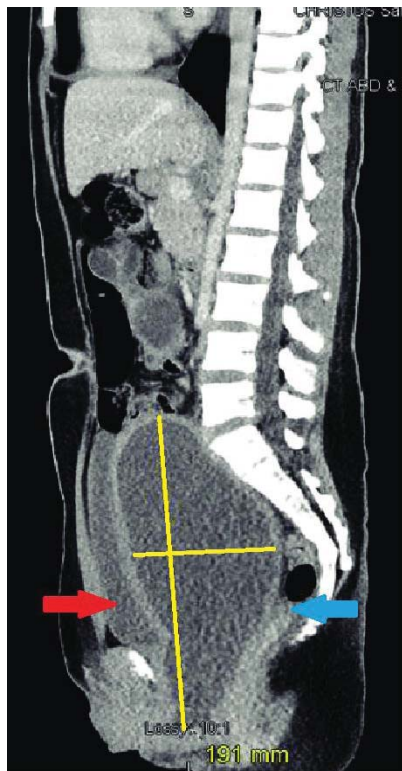
was a 10 cm mobile renal pelvic mass with a bladder globe, a good development of the external genitalia and secondary sexual characteristics with a bluish imperforated and bulging hymen, and an ultrasound scan performed urgently to show a hematocolpos. An O-shaped incision of the hymen with drainage of 400 cc of blackish blood and placement of a 16ch bladder catheter in the vagina for 15 days, with no stenosis. A forensic certificate of medical loss of virginity is given to the family.

### g) Case 7

14-year-old patient admitted to pediatric emergency department for cyclical pelvic pain for 5 months with exacerbation of pain for 4 days without urinary signs with pelvic mass of

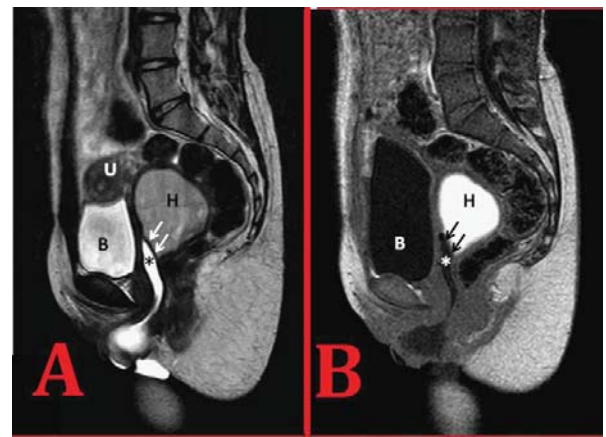
13cm, at ultrasound the uterus is in place measuring 9.7/5.6 cm regular with endocavitary fluid retention finely echogenic communicating via the cervical os, retro bladder collection finely echogenic with 9.5/5.1 cm thickened wall. O-shaped incision. 500cc drainage of blackish blood (Figures 4-6), passage of a catheter into the vagina. This catheter is then removed after 2 weeks. The evolution was satisfactory. A forensic certificate of medical loss of virginity is given to the family.

The evolution of our patients was judged on the functional and morphological state, a complete cure was obtained in our seven patients without relapse.

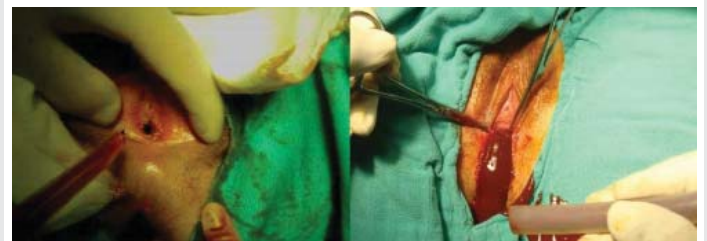

**Figure 4:** CT scan appearance :

Sagittal section of the abdomen and pelvis showing the size of the uterus with a fluid density compatible with a haematocolpos of 191 mm cranio-caudal length, with compression of the rectum (blue arrow) and bladder (red arrow) .



**Figure 5:** MRI: (A) Sagittal T2 section and (B) T1 image at the vaginal axis. Intravaginal fluid shows high and low signal intensity on T2 and T1 images, respectively, and the distal vagina is shown in detail(\*). Signs of hematocolpos (H; intermediate low and high signal on images T2 and T1, respectively) are noted in the distended structure upstream of the vaginal septum (indicated by arrows). B:bladder, more distended on a delayed T1 image; U:uterus.



**Figure 6:** Intraoperative photos: drainage of a haematocolpos.

## Results and discussion

The hymen is a remnant of the mesodermal leaflet that normally perforates during the later stages of embryonic development [4]. Hymenal imperforation is a rare event estimated at 1 in 2000 female births, but the most common congenital malformation of the female genital tract [1,4,5]. The incidence reported in the literature is widely variable, depending on whether it is assessed globally, according to age or according to the type of anatomical lesion [6]. In typical cases, the age of discovery of hematocolpos is between 12 and 15 years (the age of menarche) [7,8]. In our series of 7 hematocolpos cases, the age of our patients varies between 13 and 15 years (the pubertal period). The majority of cases reported in the literature are sporadic, however, a few familial cases have been described suggesting a probable genetic predisposition [5,9]. Only one patient among the cases we have presented has a family history of hymenal imperforation.

The diagnosis of hymenal imperforation is possible in utero when a hydrometrocolpos is found on ultrasound [10,11]. The in utero diagnosis also has the added advantage of looking for associated renal malformations. This diagnosis can be made by systematic screening at birth but also in front of a hydrometrocolpos of the newborn female baby [12]. Most often, this malformation is discovered at puberty. The diagnosis should be suspected in a girl with primary amenorrhea with normally developed secondary sexual characteristics. Patients usually consult for recurrent pelvic pain secondary to blood





accumulation in the vagina or hematocolpos [13]. The cyclical nature of the painful attacks may be missed because of the usual irregularity of the menstrual cycle in the peripubertal period [14]. Pain may be misleading, pseudopendicular and may induce 'overdoing' procedures on suspicion of acute appendicitis [15]. Haematocolpos can compress the urethra and cause dysuria, complete bladder retention and even bilateral ureterohydronephrosis [13,16-19,20]. Einsenberg [21] reported 7 cases of bladder retention in a series of 44 haematocopos observations [13,16-19,20]. Constipation is due to the same compressive mechanism [22]. In our series all the patients were not yet menarche. All patients have good development of external genitalia and secondary sexual characteristics.

Five patients presented with cyclic pain before. Abdominal-pelvic pain dominated the functional picture, it was observed in all cases. Three of our patients reported urinary signs of acute urinary retention. None of our patients showed signs of vascular, nervous or digestive compression. Blood is retained first in the vagina, then in the uterus (hematometry) and eventually in the fallopian tubes. Its volume varies from one patient to another and can even reach 3 litres [9]. Retrograde menstrual flow can alter the fallopian tubes or lead to endometriosis lesions that can impair fertility later [23]. However, this is rare if the diagnosis is made early and fertility is usually maintained [24-26]. Clinical diagnosis of this malformation is usually easy. Examination of the abdomen reveals an oval-shaped suprapubic swelling, with a large upper end, regular contours, fluctuating or renal consistency, sensitive, dull to percussion, and plunging down behind the pubic symphysis. Inspection of the vulva allows imperforation to be recognized by showing a bluish translucent membrane protruding between the labia minora. The digital rectal examination reveals a median, anterior swelling of fluid consistency, renal, extending with the abdominal mass and descending close to the anal sphincter.

In our series The genital examination shows the existence of a hymen imperforation with a bulging imperforated hymen in the 7 patients, palpation was able to objectify the existence of a mass in all the patients.

In case of diagnostic uncertainty, ultrasonography may be useful in showing the hematocolpos as a median, retrovesical fluid tone image containing some heterogeneous echoes. It also makes it possible to assess the impact upstream of menstrual retention by looking for haematometry, haematosalpinx and intraabdominal effusion [27]. MRI is used to explore pelvic masses and utero-vaginal malformations. These advantages are especially valid in cases where ultrasound diagnosis is difficult. Laparoscopy makes it possible to establish a precise assessment of the lesions upstream and to treat possible endometriosis and perianxillary adhesions secondary to chronic inflammation [10]. It is especially indicated in the case of significant haematocolpos which gives rise to fears of upstream repercussions [10,11,12,28].

In our study, abdominopelvic ultrasound was performed in all patients; the ultrasound was complementary to the clinically confirmed diagnosis. It revealed uterine and intravaginal fluid collection in favour of haematocolpos.

The objectives of this treatment are surgical:

- To restore the permeability of the genital tract.
- Ensure normal sexual function.
- Attempt to preserve future fertility.

It must be undertaken in all cases, never rely on spontaneous regression of retentions. Abstinence, even in mild forms, could lead to the development of genital and urinary tract infections, which are more frequently encountered in late-onset forms. In many cases, treatment is limited to simple drainage of the retained pouch. Total circumferential excision of the hymen may lead to sclerosis and orifice dyspareunia [28,29]. It should therefore be avoided. Hymenotomy must allow normal menstrual flow, trying to respect the virginity of these young patients as much as possible, especially in our social context, and to ensure a normal sexual life later on by avoiding restenosis. To do this, it is necessary to respect the orifices of the Bartholin glands at 5 o'clock and 7 o'clock and to make an incision at 11 o'clock in the gynaecological position in order to free the lower bank of the urinary meatus and to ensure meatohymenal dissociation. Several surgical techniques are proposed in the literature. Salvat [30], recommends the technique of radial star-shaped hymenal incisions, which is simple but does not guarantee virginity. Another technique has been described by Ali, et al. [31]. It consists of excising a small central collar of the hymen through which a Foley probe is inserted. The balloon of the catheter is inflated to 10 cm<sup>3</sup> and the catheter is then removed after 2 weeks. We found this technique interesting because it is simple, less invasive than other methods and preserves the normal architecture of the hymen. The only disadvantage of this technique is the secondary discomfort of wearing the catheter for 2 weeks. This technique is practiced in 3 of our patients. The results of this technique are rather encouraging: only 2 patients out of 65 have presented secondary hymenal stenosis in the Acar series [31]. In all cases, a postoperative clinical check-up must be systematic to verify the absence of secondary stenosis. This said, the best treatment remains preventive, based on early diagnosis of the malformation and on surgery undertaken after development of the genital organs but before the appearance of haematocolpos [32].

In our series, the 7 patients with hematocolpos on a hymeneal imperforation benefited from a Y and O incision of the hymen, evacuation of the hematic collection, and drainage by a catheter left in place for 7-10 days for the Y incision, and 15 days for the O incision. All patients were put under a bi-antibiotherapy, local care several times a day, and dilatation sessions according to the evolution.

The evolution in the 7 cases of hymeneal imperforation was satisfactory without postoperative stenosis.

## Conclusion

Hymenal imperforations are a group of genital malformations. It is an often benign condition, with a favourable evolution, if diagnosed and treated early. On the other hand, its lack of knowledge exposes it to serious complications, threatening its vital prognosis and seriously



compromising its obstetrical future. Ultrasonography remains the examination of choice to confirm the diagnosis, and makes it possible to identify possible upstream repercussions and possible associated urogenital anomalies. Systematic screening at birth and early treatment are the best guarantee of preventing complications of this pathology. We observed 7 hematocolpos cases secondary to a lack of knowledge of an imperforate hymen. As delivery rooms in our country cannot be accompanied by paediatricians, the training of midwives, insisting on the systematic examination of newborns, will make it possible to recognize malformations at birth, including imperforation of the hymen. This would avoid emergency situations that sometimes lead to inappropriate treatment. The treatment is exclusively surgical and the routes of access are different. Most often, it remains remarkably simple and leads to a definitive cure.

## References

- Messina M, Severi FM, Bocchi C, Ferrucci E, Di Maggio G, et al. (2004) Voluminous prénatal masse: a case f congénital hydrometrocolpos. *J Matern Fetal Neonatal Med* 15: 135-137. [Link: https://bit.ly/3c2Y4k3](https://bit.ly/3c2Y4k3)
- Yanza MC, Sepou A, Nguembi E, Ngale R, Gaunefet C, et al. (2003) Hymen imperforé, diagnostic négligé à la naissance, urgence chirurgicale à l'adolescence. *Schweiz Med Forum* 44: 1063-1065.
- Salvat J, Slamani L (1998) Hématocolpos. *J Gynécol Obstet Biol Reprod (Paris)* 27: 396-402. [Link: https://bit.ly/2yr7Cqr](https://bit.ly/2yr7Cqr)
- Heger AH, Ticson L, Guerra L, Lister J, Zaragoza T, et al. (2002) Appearance of the genitalia in girls selected for nonabuse: review of hymenal morphology and nonspecific findings. *J Pediatr Adolesc Gynecol* 15: 27-35. [Link: https://bit.ly/2YUaZTy](https://bit.ly/2YUaZTy)
- Walsh B, Shih R (2006) An unusual case of urinary retention in a competitive gymnast. *J Emerg Med* 31: 279-281. [Link: https://bit.ly/3fjS8Fh](https://bit.ly/3fjS8Fh)
- Batran VC (1983) Mullerian anomalies and their management. *Fertil steril* 40: 159-163. [Link: https://bit.ly/2z6AO6k](https://bit.ly/2z6AO6k)
- Hall DJ (1999) An usual case of urinary retention due to imperforate hymen. *J Accid Emerg Med* 16: 232-233. [Link: https://bit.ly/3c1nxKF](https://bit.ly/3c1nxKF)
- Letts M, Haasbeek J (1990) Hematocolpos as a case of back pain in premenarchal adolescents. *J Pediatr Orthop* 10: 731-732. [Link: https://bit.ly/2Yv0unB](https://bit.ly/2Yv0unB)
- Sakalkale R, Samarakkody U (2005) Familial occurrence of imperforate hymen. *J Pediatr Adolesc Gynecol* 18: 427-429. [Link: https://bit.ly/35uFS0g](https://bit.ly/35uFS0g)
- Salvat J, Slamani L (1998) Hématocolpos. *J Gynécol Obstet Biol Reprod* 27: 396-402. [Link: https://bit.ly/3b0jsVR](https://bit.ly/3b0jsVR)
- Winderl LM, Silverman PK (1995) Prenatal diagnosis of congenital imperforate hymen. *Obstet Gynecol* 85: 857-860. [Link: https://bit.ly/3ce3hFG](https://bit.ly/3ce3hFG)
- Rochet Y (1986) les principales malformations génitales: Aspects thérapeutiques. *Rev Fr Gyn Obstet* 81: 315-317.
- Adali E, Kurdoglu M, Yildizhan R, Kulusari A (2009) An overlooked cause of acute urinary retention in an adolescent girl: a case report. *Arch Gynecol Obstet* 279: 701-703. [Link: https://bit.ly/2xwmjlq](https://bit.ly/2xwmjlq)
- Paniel BJ, Truc JB, Beuzit JM, Pelissier C (1987) Diagnostic des malformations congénitales de la vulve et du vagin. *Ann Pédiatr* 34: 11-25. [Link: https://bit.ly/2z9gdxY](https://bit.ly/2z9gdxY)
- Emans SJ, Laufer MR, Goldstein DP (2004) Dysmenorrhea, pelvic pain, and the premenstrual syndrome. In: Emans SJ, Laufer MR, Goldstein DP, eds. *Pediatric and Adolescent Gynecology* 5<sup>th</sup> ed. Philadelphia : Lippincott-Raven 376-384.
- Loscalzo IL, Catapano M, Loscalzo J, Sama A (1995) Imperforate hymen with bilateral hydronephrosis: an unusual emergency department diagnosis. *J Emerg Med* 13: 337-339. [Link: https://bit.ly/3deX9gA](https://bit.ly/3deX9gA)
- Yu T J, Lin MC (1993) Acute urinary retention in two patients with imperforate hymen. *Scand J Urol Nephrol* 27: 43-44. [Link: https://bit.ly/2Sw71ul](https://bit.ly/2Sw71ul)
- Dane C, Dane B, Erginbas M, Cetin A (2007) Imperforate hymen-a rare cause of abdominal pain: two cases and review of the literature. *J Pediatr Adolesc Gynecol* 20: 245-247. [Link: https://bit.ly/35ybQJg](https://bit.ly/35ybQJg)
- Wort SJ, Heman-Ackah C, Davies A (1995) Acute urinary retention in the young female. *Br J Urol* 13: 337-339.
- Chang JW, Yang LY, Wang HH, Wang JK, Tiu CM (2007) Acute urinary retention as the presentation of imperforate hymen. *J Chin Med Assoc* 70: 559-561. [Link: https://bit.ly/2ytePX0](https://bit.ly/2ytePX0)
- Einsenberg E, Faber M, Mitchell GW Jr, Turksoy RN, Rule AH (1982) Complete duplication of the uterus and cervix with unilaterally imperforate vagina. *Obst Gynecol* 60: 259-262. [Link: https://bit.ly/2YuD024](https://bit.ly/2YuD024)
- Wang W, Chen MH, Yang W, Hwang DL (2004) Imperforate hymen presenting with chronic constipation and lumbago: report of one case. *Acta Paediatr Taiwan* 45: 340-342. [Link: https://bit.ly/3fidsex](https://bit.ly/3fidsex)
- Olive DL, Henderson DY (1987) Endometriosis and mullerian anomalies. *Obstet Gynecol* 69: 412-415. [Link: https://bit.ly/3c5h2Xe](https://bit.ly/3c5h2Xe)
- Rock JA, Zacur HA, Dlugi AM, Jones HW Jr, TeLinde RW (1982) Pregnancy success following surgical correction of imperforate hymen and complete transverse vaginal septum. *Obstet Gynecol* 59: 448-451. [Link: https://bit.ly/35vQTPa](https://bit.ly/35vQTPa)
- Liang CC, Chang SD, Soong YK (2003) Long-term followup of women who underwent surgical correction for imperforate hymen. *Arch Gynecol Obstet* 269: 5-8. [Link: https://bit.ly/2xxz0mh](https://bit.ly/2xxz0mh)
- Joki-Erkilä MM, Heinonen PK (2003) Presenting and longterm clinical implications and fecundity in females with obstructing vaginal malformations. *J Pediatr Adolesc Gynecol* 16: 307-312. [Link: https://bit.ly/2YvwMPn](https://bit.ly/2YvwMPn)
- Robberecht E, Smets A, Wincker MV, Delens F (1996) Radiological case of the month hematocolpos due to imperforate hymen. *Arch Pediatr Adolesc Med* 150: 993-994. [Link: https://bit.ly/3aVb2z6](https://bit.ly/3aVb2z6)
- Chelli D, Kehila M, Sfar E, Zouaoui B, Chelli H, et al. (2008) Imperforation hyménéale : peut-on la traiter en préservant la virginité. *Santé* 18: 83-87. [Link: https://bit.ly/2Wmolhe](https://bit.ly/2Wmolhe)
- Salvat J, Slamani L (1998) Hématocolpos. *J Gynécol Obstet Biol Reprod (Paris)* 27: 396-402. [Link: https://bit.ly/2yr7Cqr](https://bit.ly/2yr7Cqr)
- Ali A, Cetin C, Nedim C, Kazim G, Cemalettin A (2003) Treatment of imperforate hymen by application of Foley catheter. *Eur J Obstet Gynecol Reprod Biol* 106: 72-75. [Link: https://bit.ly/3ce5ile](https://bit.ly/3ce5ile)
- Acar A, Balci O, Karatayli R, Capar M, Colakoglu MC (2007) The treatment of 65 women with imperforate hymen by a central incision and application of Foley catheter. *BJOG* 114: 1376-1379. [Link: https://bit.ly/3b0zrTX](https://bit.ly/3b0zrTX)
- Ramsiss H, Harrak H, Amrani S, Elyoussfi M, Bargach S (2015) Hematocolpos Sur Imperforation Hymeneale a Propos De 3 Cas. *Global Journals Inc.* [Link: https://bit.ly/2xBVq64](https://bit.ly/2xBVq64)

**Copyright:** © 2020 Lahfaoui M, et al. This is an open-access article distributed under the terms of the Creative Commons Attribution License, which permits unrestricted use, distribution, and reproduction in any medium, provided the original author and source are credited.