

Case Report

Oral Bisoprolol for the treatment of non-resolving central serous chorioretinopathy: A case report

Vingolo EM, Napolitano G*, Rigoni E, De Rosa V

Department of Ophthalmology, University La Sapienza of Rome, Polo Pontino, Ospedale Alfredo Fiorini, Terracina, Italy

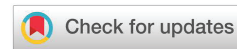Received: 27 December, 2019

Accepted: 11 June, 2020

Published: 12 June, 2020

*Corresponding author: Napolitano Giuseppe, Department of Ophthalmology, University La Sapienza of Rome, Polo Pontino, Ospedale Alfredo Fiorini, Terracina, via Vittorio Veneto 183, 97011 Acate (RG), Italy, Tel: +393407130590; E-mail: giuseppenapolitano7@gmail.com

<https://www.peertechz.com>



Abstract

Purpose: To evaluate the effect of the beta blocker Bisoprolol in the treatment of chronic central serous chorioretinopathy (CSC).

Methods: Five patients with non-resolving CSC were treated with oral Bisoprolol 2,5 mg once a day for three months. The best-corrected visual acuity (BCVA), central macular thickness (CMT) and sub-retinal fluid (SRF) horizontal diameter recorded at baseline and at 1, 2, and 3 months by optical coherence tomography (OCT) were analyzed.

Results: All the patients achieved a full visual recovery after 3 months of treatment and there was no evidence of SRF at the last OCT follow-up. No side effect was recorded.

Conclusions: These results suggest that oral Bisoprolol may be effective in the treatment of chronic CSC and could be considered as a potential therapy choice in those cases at risk of diffuse retina pigment epitheliopathy.

Introduction

Central serous chorioretinopathy (CSC) is a spontaneous serous detachment of neurosensory retina localized in the macular region which typically affects males between 20 and 40 years of age [1]. The pathophysiology of CSC remains obscure, although disorders in both the choroidal circulation and the retinal pigment epithelium (RPE) seem to be involved [2]. It seems that a choroidal vascular hyperpermeability leads to an increase in tissue hydrostatic pressure under the RPE which can eventually result in an interruption of his continuity [3]. The symptoms depend on the amount of sub-retinal fluid (SRF) and may include reduction of visual acuity, metamorphopsia and perception of blind spots [4]. While acute CSC generally resolves spontaneously with a full visual recovery within one to four months, [5] the chronic form, also known as “diffuse retina

pigment epitheliopathy”, [6] may lead to a permanent loss of visual acuity due to the changes in the neurosensory retina [7]. The diagnosis is based on fundus exam combined with imaging of retina and choroid through optical coherence tomography (OCT), fluorescein angiography (FA) and indocyanine green angiography (ICGA). It has been reported that the prevalence of CSC is higher among patients taking glucocorticoids [8]. Other risk factors allegedly involved in the development of CSC are type A personality, [9] hypertension, pregnancy, sleeping apnea, Helicobacter pylori infection, autoimmune disease and psychopharmacologic medication use [10].

Since acute CSC is generally self-limiting, management involves observation and, when possible, risk factors modification [8]. On the other hand, long stand retinal detachment and persistent reduced visual acuity, represent

potential indications for treatment. To date, available treatments for CSC include photodynamic therapy (PDT) [11], laser photocoagulation [12], subthreshold micropulse laser treatment [13] and several systemic medications like carbonic anhydrase inhibitors [14] and aldosterone antagonists [15]. The high adrenergic activity observed in patients with type-A personality led to assume a positive effect of beta-blockers in the treatment of CSC [16]. However, only few studies investigated this treatment modality for recurrent CSC. We report two cases of non-resolving CSC and chronic epitheliopathy successfully treated with oral Bisoprolol 2,5 mg once a day for three months.

Materials and methods

Five patients, three males and two women, mean age 32 ± 5 , followed up in our retinal disease unit, presented with monolateral non-resolving CSC with persistent SRF. Visual symptoms and OCT follow-up were consistent with chronic CSC for more than 5 months of duration with no spontaneous reduction of SRF. They underwent a complete ophthalmological examination including a best-corrected visual acuity measurement with the Early Treatment Diabetic Retinopathy Study (ETDRS) charts, anterior segment and fundus examination. We also performed Fluorescein, ICG angiography and spectral-domain OCT (SD-OCT) (Heidelberg Spectralis, Heidelberg, Germany) which confirmed the presence of SRF. After signing the informed consent, all the patients were treated with oral Bisoprolol, a selective β_1 adrenergic receptor blocker, 2,5 mg once a day for three months.

The best-corrected visual acuity (BCVA), central macular thickness (CMT) and SRF horizontal diameter, recorded at baseline and at 1, 2, and 3 months after the beginning of therapy were analyzed.

Results

Baseline

At baseline, the mean BCVA at 4 m was 62 ETDRS letters (20/60).

SD-OCT measurements included a volume scan centered on the fovea and comprising 25 horizontal B-scans, covering a $20^\circ \times 20^\circ$ field. Central macular thickness (CMT) was measured from RPE to the internal limiting membrane in the central field of an ETDRS grid projected onto the thickness map using the built-in Spectralis OCT software. Mean CMT was 412,8 microns. The SRF diameter was manually measured on a scan centered on the fovea by two operators and mean SRF diameter was 5662,4 microns. Figure 1A shows the OCT of 2 patients.

1-month follow-up

At first follow-up, there was no improvement in BCVA. Mean CMT decreased from 412,8 to 310,8 microns. Mean SRF diameter was 2541 microns, showing a mean reduction of 3121,4 microns. Figure 1B shows the OCT of 2 patients.

2-month follow-up

At month 2, the patients achieved a greater improvement in

visual acuity, with a mean of 68 ETDRS letters (20/32). Mean CMT showed a decrease to 261 microns and mean SRF diameter measured 723 microns, achieving total reabsorption of fluid in 3 cases of 5. Figure 1C shows the OCT of 2 patients.

3-month follow-up

All the patients achieved a full visual recovery after 3 months of treatment with a mean BCVA of 84 ETDRS letters (20/20). There was no evidence of SRF at OCT follow-up in all of the 5 patients treated and the mean CMT was 232 microns. Figure 1D shows the OCT of 2 patients.

Discussion

In our non-resolving CSC patients treated with oral Bisoprolol 2,5 mg once a day for three months, a significant functional and anatomical improvement was achieved with no side effects. Figures 2,3 shows the improvements by means of reduction of mean CMT and mean SRF. Bradycardia, nausea, vomiting and constipation are commonly reported side effects of bisoprolol, but we didn't notice any of those in our short case – series. Less frequently encountered side effects are exacerbation of peripheral diseases such as the Raynaud phenomenon, bronchoconstriction, and hypoglycemia.

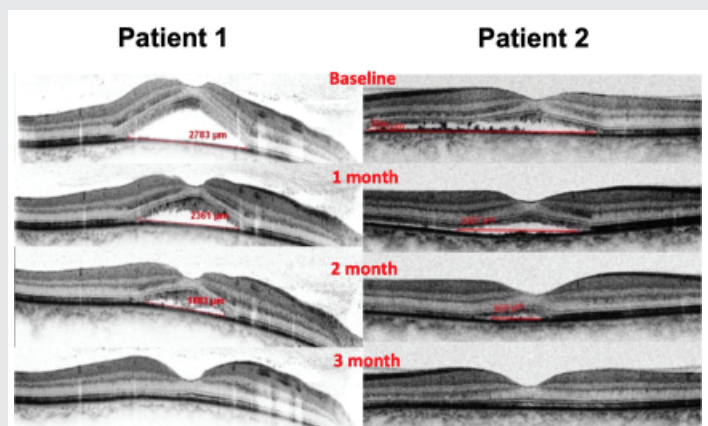


Figure 1: OCT images of two patients with central serous chorioretinopathy presenting subretinal fluid at baseline (A) and their follow-up at 1 month (B), 2 months (C) and 3 months (D) under treatment with oral Bisoprolol 2,5 mg once a day for 3 months.

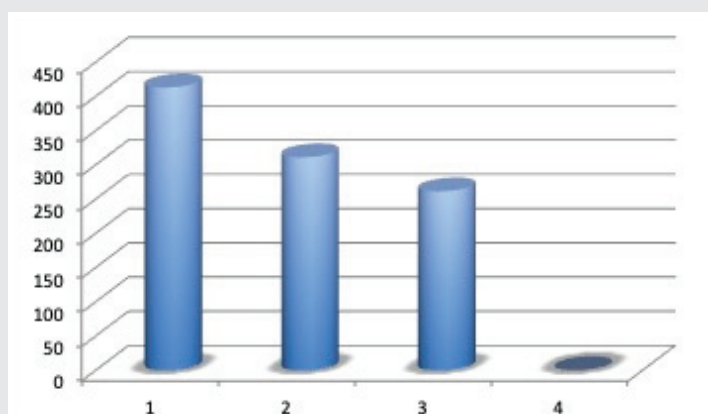


Figure 2: Trend of CMT at baseline, at 1 month, 2 months and 3 months under treatment with oral Bisoprolol 2,5 mg once a day for 3 months.

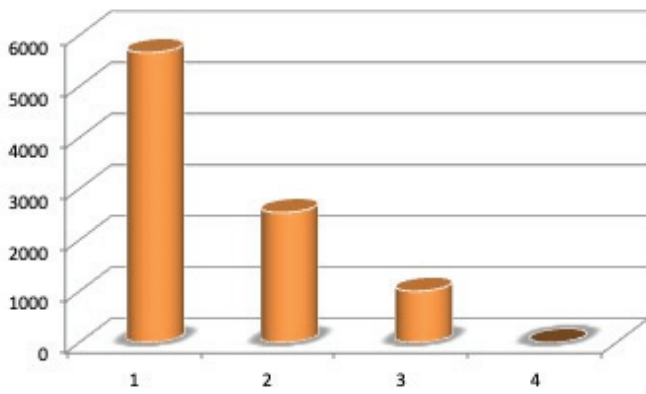


Figure 3: Trend of SRF at baseline, at 1 month, 2 months and 3 months under treatment with oral Bisoprolol 2,5 mg once a day for 3 months.

In people affected by DM Mask hypoglycemia may be a serious side effect [17].

Both the patients presented a full visual recovery and a complete resolution of SRF at treatment completion. These results suggest that oral Bisoprolol may be effective in the treatment of chronic CSC and could be considered as a potential therapy choice in those cases at risk of diffuse retina pigment epitheliopathy. Considering the fact that a significant percentage of patients with chronic CSC presents bilateral disease [18], oral therapies may be more effective and less invasive than treatments targeting specific areas of the retina such as laser photocoagulation or PDT.

Previous studies investigated the effect of beta-blockers in CSC. Avci noted that one patient with CSC, who was on therapy with metoprolol for hypertension, developed a recurrence of CSC three weeks after the cessation of metoprolol treatment. In the light of this recognition, he decided to start this treatment modality in 6 CSC patients reporting a positive experience [16]. In 1998, Fabianova et al. divided their CSC patients into two groups: 21 patients were treated with 2 x 10 mg/day of Trimepranol, a β -non selective blocker, and 30 patients received 2 x 50 mg/day of Metoprolol, a β_1 selective blocker. In all cases, they achieved a complete remission of the disease and no difference was found in the action of β_1 selective and non-selective blockers [19]. Later, in 2002, also Chrapek et al. used Trimepranol for the treatment of 13 CSC patients, but compared to Fabianova, they used a lower dose. They found that 5 mg of Trimepranol twice a day were ineffective as a medicamentous treatment of CSC [19]. Tatham and Macfarlane demonstrated that recovery, remission, and subsequent recovery of the signs and symptoms in one patient with CSC coincided with the commencement, cessation, and retreatment with oral propranolol, 40 mg twice a day. Therefore they confirmed that the blockage of β -adrenergic receptors may play a role in chronic CSC [20]. However Chrapek again, in a recent clinical trial conducted on 23 patients, investigated the effect of 10 mg of metipranolol twice a day compared to placebo and he demonstrated no effect on the duration of CSC [22].

Based on these arguments, it is clear that further studies with a greater number of patients are needed to prove the

value of β -blockers in the treatment of CSC. However from our perspective, it seems to be appropriate to recommend Bisoprolol 2,5 mg one a day for patients suffering from CSC without signs of resolution within the first 8–12 weeks. Our work has some limitations: first it is a case series, and also a short number of case are provided. However, based on the interesting findings of our case series other clinical studies with larger amount of patients may be advantageous, in order to confirm our results and understand whether bisoprolol may be a real game changer in the treatment of CSC.

References

- Liew G, Quin G, Gillies M, Fraser-Bell S (2013) Central serous chorioretinopathy: a review of epidemiology and pathophysiology. *Clin Exp Ophthalmol* 41: 201-214. [Link: https://bit.ly/2YonOSp](https://bit.ly/2YonOSp)
- Prunte C, Flammer J (1996) Choroidal capillary and venous congestion in central serous chorioretinopathy. *Am J Ophthalmol* 121: 26-34. [Link: https://bit.ly/3fiWD2l](https://bit.ly/3fiWD2l)
- Uyama M, Matsunaga H, Matsubara T, Fukushima I, Takahashi K, et al. (1999) Indocyanine green angiography and pathophysiology of multifocal posterior pigment epitheliopathy. *Retina* 19: 12-21. [Link: https://bit.ly/3dR2ZFS](https://bit.ly/3dR2ZFS)
- Wang M, Munch IC, Hasler PW, Prunte C, Larsen M (2008) Central serous chorioretinopathy. *Acta Ophthalmol* 86: 126-145. [Link: https://bit.ly/37k9VJ2](https://bit.ly/37k9VJ2)
- Nicholson B, Noble J, Forooghian F, Meyerle C (2013) Central serous chorioretinopathy: update on pathophysiology and treatment. *Surv Ophthalmol* 58: 103-126. [Link: https://bit.ly/2MQihig](https://bit.ly/2MQihig)
- Yannuzzi LA, Slakter JS, Kaufman SR, Gupta K (1992) Laser treatment of diffuse retinal pigment epitheliopathy. *Eur J Ophthalmol* 2: 103-114. [Link: https://bit.ly/3fqwXB1](https://bit.ly/3fqwXB1)
- Baran NV, Gürlü VP, Esgin H (2005) Long-term macular function in eyes with central serous chorioretinopathy. *Clin Exp Ophthalmol* 33: 369-372. [Link: https://bit.ly/3ffTGQ4](https://bit.ly/3ffTGQ4)
- Bouzas EA, Karadimas P, Pourmaras CJ (2002) Central serous chorioretinopathy and glucocorticoids. *Surv Ophthalmol* 47: 431-448. [Link: https://bit.ly/2YqVm2o](https://bit.ly/2YqVm2o)
- Yannuzzi LA (1987) Type-A behavior and central serous chorioretinopathy. *Retina* 7: 111-131. [Link: https://bit.ly/2C0hoS9](https://bit.ly/2C0hoS9)
- Liu B, Deng T, Zhang J (2016) Risk factors for central serous chorioretinopathy. *Retina* 36: 9-19.
- Chan WM, Lai TYY, Lai RYK, Liu DTL, Lam DSC, et al. (2008) Half-dose verteporfin photodynamic therapy for acute central serous chorioretinopathy: one-year results of a randomized controlled trial. *Ophthalmology* 115: 1756-1765. [Link: https://bit.ly/2UBphDX](https://bit.ly/2UBphDX)
- Robertson DM, Ilstrup D (1983) Direct, indirect, and sham laser photocoagulation in the management of central serous chorioretinopathy. *Am J Ophthalmol* 95: 457-466. [Link: https://bit.ly/3dTnMZ7](https://bit.ly/3dTnMZ7)
- Sun Z, Huang Y, Nie C, Wang Z, Pei Z, et al. (2019) Efficacy and safety of subthreshold micropulse laser compared with threshold conventional laser in central serous chorioretinopathy. *Eye*. [Link: https://bit.ly/2MQBtwm](https://bit.ly/2MQBtwm)
- Pikkel J, Beiran I, Ophir A, Miller B (2002) Acetazolamide for central serous retinopathy. *Ophthalmology* 109: 1723-1725. [Link: https://bit.ly/2XR2sOm](https://bit.ly/2XR2sOm)
- Bousquet E, Beydoun T, Zhao M, Hassan L, Offret O, et al. (2013) Mineralocorticoid receptor antagonism in the treatment of chronic central serous chorioretinopathy: a pilot study. *Retina* 33: 2096-2102. [Link: https://bit.ly/2Yp4F2D](https://bit.ly/2Yp4F2D)
- Avci R, Deutman AF (1993) Treatment of central serous choroidopathy with the



beta receptor blocker metoprolol (preliminary results) Klin Monbl Augenheilkd 202: 199-205. [Link: https://bit.ly/30yBpcK](https://bit.ly/30yBpcK)

17. Bazroon AA, Alrashidi NF (2020) Bisoprolol. [Link: https://bit.ly/3cZ8bGw](https://bit.ly/3cZ8bGw)

18. Daruich A, Matet A, Dirani A, Gallice M, Nicholson L, et al. (2016) Oral Mineralocorticoid-Receptor Antagonists: Real-Life Experience in Clinical Subtypes of Nonresolving Central Serous Chorioretinopathy With Chronic Epitheliopathy. Transl Vis Sci Technol 5: 2. [Link: https://bit.ly/2XWskZz](https://bit.ly/2XWskZz)

19. Fabianová J, Porubská M, Cepilová Z (1998) Central serous chorioretinopathy treatment with beta blockers. Cesk Slov Oftalmol 54: 401-404.

20. Chrapek O, Spacková K, Reháč J (2002) Treatment of central serous chorioretinopathy with beta blockers. Cesk Slov Oftalmol. 58: 382-386

21. Tatham A, Macfarlane A (2006) The use of propranolol to treat central serous chorioretinopathy: an evaluation by serial OCT. J Ocul Pharmacol Ther 22: 145-149. [Link: https://bit.ly/37nnNC8](https://bit.ly/37nnNC8)

22. Chrapek O, Jirkova B, Kandrnal V, Rehak J, Sin M, et al. (2015) Treatment of central serous chorioretinopathy with beta-blocker metipranolol. Biomed Pap Med Fac Univ Palacky Olomouc Czech Repub 159: 120-123. [Link: https://bit.ly/30vWc0h](https://bit.ly/30vWc0h)

Discover a bigger Impact and Visibility of your article publication with Peertechz Publications

Highlights

- ❖ Signatory publisher of ORCID
- ❖ Signatory Publisher of DORA (San Francisco Declaration on Research Assessment)
- ❖ Articles archived in worlds' renowned service providers such as Portico, CNKI, AGRIS, TDNet, Base (Bielefeld University Library), CrossRef, Scilit, J-Gate etc.
- ❖ Journals indexed in ICMJE, SHERPA/ROMEO, Google Scholar etc.
- ❖ OAI-PMH (Open Archives Initiative Protocol for Metadata Harvesting)
- ❖ Dedicated Editorial Board for every journal
- ❖ Accurate and rapid peer-review process
- ❖ Increased citations of published articles through promotions
- ❖ Reduced timeline for article publication

Submit your articles and experience a new surge in publication services (<https://www.peertechz.com/submit>).

Peertechz journals wishes everlasting success in your every endeavours.

Copyright: © 2020 Vingolo EM, et al. This is an open-access article distributed under the terms of the Creative Commons Attribution License, which permits unrestricted use, distribution, and reproduction in any medium, provided the original author and source are credited.

Citation: Vingolo EM, Napolitano G, Rigoni E, De Rosa V (2020) Oral Bisoprolol for the treatment of non-resolving central serous chorioretinopathy: A case report. J Clin Res Ophthalmol. 7(1): 031-036. DOI: <https://dx.doi.org/10.17352/2455-1414.000070>