

**Priyanka<sup>1\*</sup>, Amber Kumar<sup>2</sup>, Mahesh Maheshwari<sup>3</sup> and Jyotirmay Biswas<sup>4</sup>**

<sup>1</sup>Senior Resident, Department of Ophthalmology, AIIMS, Bhopal, India

<sup>2</sup>Assistant Professor, Department of Pediatrics, AIIMS, Bhopal, India

<sup>3</sup>Associate Professor, Department of Pediatrics, AIIMS, Bhopal, India

<sup>4</sup>Director of Uveitis and Ocular Pathology department, Sankara Nethralaya, Chennai, India

Received: 11 June, 2019

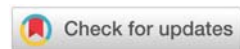
Accepted: 11 July, 2019

Published: 12 July, 2019

\*Corresponding author: Priyanka, Senior Resident, Department of Ophthalmology, AIIMS, Saket Nagar, Bhopal-462020, India, Tel: 9555571355; Email: priyankapmch1@gmail.com

Keywords: Antitubercular therapy; Immunosuppressive; Paradoxical worsening; Tubercular choroiditis; Steroid

<https://www.peertechz.com>



**Case Report**

**Paradoxical worsening of presumed tubercular serpiginous like choroiditis on anti-tubercular therapy**

**Annotation**

Choroidal tuberculosis may present as multifocal progressive or serpiginous like choroiditis. It is important to recognize these presentations as these eyes show good response to systemic antitubercular therapy. Paradoxical reaction in tuberculosis can occur in patients receiving anti tuberculous therapy (ATT). It consists of clinical or radiological worsening of pre-existing tuberculous lesions or the development of new lesions in patients who initially improved on treatment. Intraocular tuberculosis presents most commonly as posterior uveitis, either as choroidal tubercles, choroidal tuberculoma, subretinal abscess or serpiginous-like choroiditis; however, it can also present, in order of decreasing prevalence, as granulomatous anterior uveitis, panuveitis and intermediate uveitis. We report, a case of paradoxical worsening of presumed tubercular serpiginous like choroiditis on antitubercular therapy. Through this interesting case we try to highlight the fact that continued progression of lesions may be noted inspite of ATT and systemic steroids but it is important to be aware of paradoxical worsening, so that one doesn't interrupt ATT.

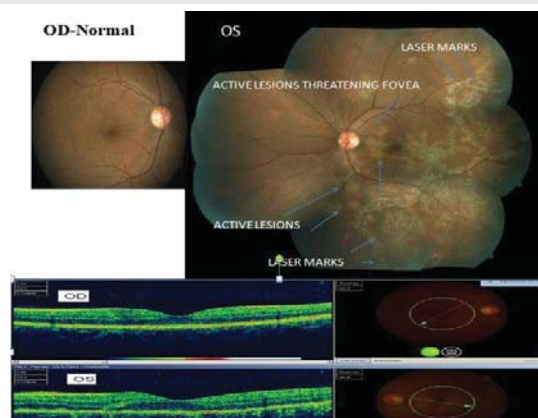
**Introduction**

Serpiginous like choroiditis (SLC) and serpiginous choroiditis (SC) are uveitic entities on the same spectrum but with different clinical morphologic features. Serpiginous choroiditis is believed to be an autoimmune disease and responds well to systemic steroids; in contrast, treating serpiginous-like choroiditis with steroids can lead to serious local and systemic complications if not accompanied by anti-tubercular therapy (ATT). Paradoxical reaction to anti-tubercular therapy has been observed in various forms of ocular tuberculosis including serpiginous-like choroiditis, granulomatous anterior uveitis, intermediate uveitis, panuveitis, retinal vasculitis and has been documented frequently in extrapulmonary tuberculosis (TB) [1-3]. It is believed to be mediated by the host's immune system due to an enhanced delayed hypersensitivity of the host, decreased suppressor mechanisms, and as a response to mycobacterial antigens.

**Case Report**

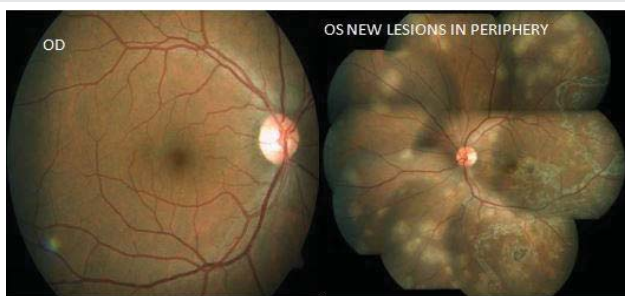
A man of age 37 year presented with complaints of diminution of vision in left eye since 15 days. He was previously diagnosed and treated by his local ophthalmologist, as acute retinal necrosis, had received 600 mg Acyclovir intravenous thrice daily for 1 week followed by oral Valacyclovir 1 gm thrice daily and oral steroid (60 mg for first week followed

by weekly tapering) along with laser barrage. On examination he had best corrected visual acuity of 6/6 in right eye and 6/9 in his left eye. Slit lamp examination revealed quiet anterior chamber in right eye and AC cells 1+ along with vitreous cells 1+ in left eye. Intraocular pressure measured was normal in both eyes. Fundus examination showed active choroidal lesion threatening fovea along with laser mark in left eye. Right eye was within normal limit (Figure1). His investigation revealed

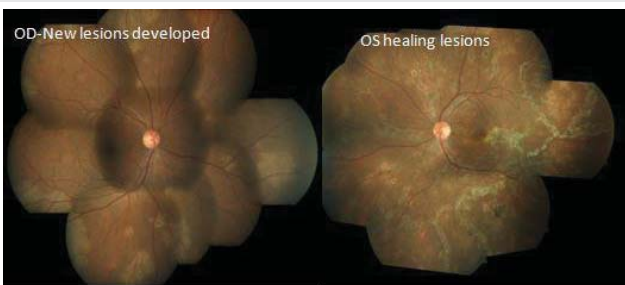


**Figure 1:** At presentation; Fundus examination showed active choroidal lesion threatening fovea along with laser mark in left eye. Right eye was within normal limit. OCT left eye showed foveal thickness of 234 micron and normal thickness of right eye (202 micron).

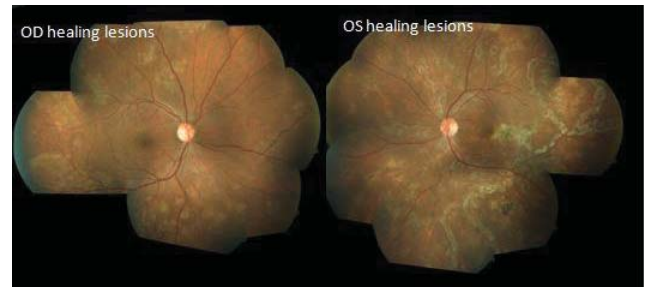
strongly positive tuberculin skin test with ulceration (24 mm induration); positive Quantiferon TB-Gold Test and contrast enhanced computed tomography chest revealed mediastinal lymphadenopathy (necrotic lymph nodes without calcification suggestive of tubercular etiology). Biopsy of lymphnode for confirmation was not attempted in this case in view of positive tuberculin test and Quantiferon TB-Gold test. However, other investigations for syphilis, toxoplasmosis, HIV was negative. Left eye anterior chamber tap was done for PCR of CMV/HSV/VZV/MTB but it was negative. He was started with intravenous methyl prednisolone (1 gm) for 3 days followed by systemic steroid (60 mg prednisolone with weekly tapering). The patient was referred to a chest physician, who initiated 4 drugs ATT (Isoniazide, rifampicin, pyrazinamide, ethambutol). After 1 week left eye fundus examination showed healing lesion. At 1 month of follow up, slit lamp examination revealed quiet anterior chamber with no vitreous cell in both eye. Fundus examination showed healing lesions at centre with peripheral active lesion. Right eye was within normal limit (Figure 2). Dose of systemic steroid was increased to 60 mg from 30 mg and advised to continue ATT. Steroid was tapered again after 1 week. At 2 month of follow up, slit lamp examination revealed quiet anterior chamber with no vitreous cell in both eye. Fundus examination showed healing choroidal lesion in left eye but active new lesion in right eye (Figure 3). He was advised to continue ATT along with tapering dose of oral steroid. Azathioprine 50 mg thrice daily was added. At 3 month of follow up, fundus examination revealed healing lesion of choroiditis in both eyes (Figure 4). He was advised to continue same treatment. At 5 month of follow up, he had best corrected visual acuity 6/6 in both eyes. Slit examination revealed quiet anterior chamber with fundus showing healed choroidal lesion in both eyes (Figure 5). ATT completed at 6 months. Steroid



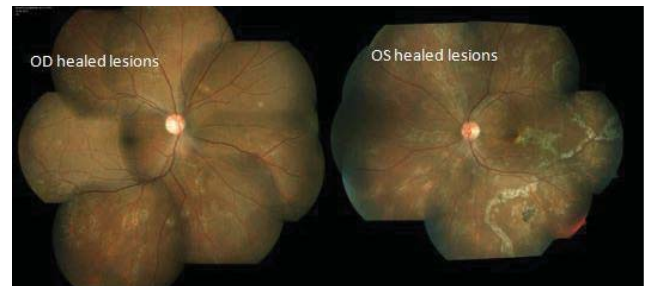
**Figure 2:** One month follow-up; Fundus examination showed healing lesions at centre with peripheral active lesion.



**Figure 3:** Two month follow-up; Fundus examination showed healing choroidal lesion in left eye but active new lesion in right eye.



**Figure 4:** Three month follow-up; Fundus examination revealed healing lesion of choroiditis in both eyes.



**Figure 5:** Five month follow-up; Fundus examination showing healed choroidal lesion in both eyes.

and immunosuppressive were also stopped at 6 month. At one year follow-up, there was no recurrence.

## Discussion

Choroidal tuberculosis may present as multifocal progressive or serpiginous like choroiditis. Tubercular serpiginous-like choroiditis is considered as an immune-mediated hypersensitivity reaction to the tubercular bacilli sequestered in the retinal pigment epithelium layer. These eyes show good response to ATT [4]. Resolution of lesions in patients with serpiginous choroiditis can occur with combination therapy of systemic steroids and immunosuppressive agents [5]. In patients with tuberculous choroiditis, ATT accelerates the process of healing and reduces recurrence risk by decreasing the number of bacilli. In some patients, the rapid destruction of bacilli after initiation of ATT may cause existing lesions to worsen and new lesions to form. This paradoxical phenomenon occurs more often during the treatment of systemic TB infections, but has also been found in ocular TB. Paradoxical worsening may even occur in patients initiated on simultaneous ATT and systemic steroid. One reason for this may be very severe inflammation and inadequate suppression. Another reason may be that rifampicin increases steroid metabolism [6]. In that case, increasing the steroid dose or adding immunosuppressive therapy may resolve the issue. The factor that could have contributed to the paradoxical reaction in our case was that our patient was also on rifampicin, which is reported to reduce the bioavailability of corticosteroids. Hawkey *et al.* found that a higher bacillary load or a persistent antigenic stimulus that is poorly cleared from the diseased site may be responsible for the development of paradoxical worsening [7]. The RPE shares many features with the macrophages, including phagocytosis of bacteria and expression of toll-like and complement receptors and

perturbed RPE produces a variety of inflammatory substances, including interleukin-1 and granulocyte-macrophage colony-stimulating factor [8]. Therefore, the RPE cells that have engulfed Mycobacteria may release cytokines triggered by mycobacterial LAM (lipoarabinomannan) thus causing continued progression.

## Conclusion

The possibility of the paradoxical phenomenon upon ATT initiation should be kept in mind, so that one does not interrupt anti-tubercular treatment and think of drug-resistant tubercular serpiginous-like choroiditis or investigate for other possible non tubercular aetiologies. To monitor the disease progression, recurrences, and involvement of the other eye, serial examination at regular intervals is recommended. Systemic steroid and/or immunosuppressive therapy is useful to suppress inflammation and control progression.

## References

- Gupta V, Gupta A, Arora S, Bambery P, Dogra MR, et al. (2003) Presumed tubercular serpiginous like choroiditis: Clinical presentations and management. *Ophthalmology* 110: 1744-1749. [Link: http://bit.ly/2G86wke](http://bit.ly/2G86wke)
- Basu S, Nayak S, Padhi TR, Das T (2013) Progressive ocular inflammation following anti-tubercular therapy for presumed ocular tuberculosis in a high-endemic setting. *Eye (Lond)* 27: 657-662. [Link: http://bit.ly/2JGmMJZ](http://bit.ly/2JGmMJZ)
- Gupta M, Bajaj BK, Khwaja G (2003) Paradoxical response in patients with CNS tuberculosis. *J Assoc Physicians India* 51: 257-260. [Link: http://bit.ly/2XzQCd0](http://bit.ly/2XzQCd0)
- Rao NA, Saraswathy S, Smith RE (2006) Tuberculous uveitis: distribution of *Mycobacterium tuberculosis* in the retinal pigment epithelium. *Arch Ophthalmol* 124: 1777-1779. [Link: http://bit.ly/2XJQrK](http://bit.ly/2XJQrK)
- Abrez H, Biswas J, Sudharshan S (2007) Clinical profile, treatment, and visual outcome of serpiginous choroiditis. *Ocular Immunology and Inflammation* 15: 325-335. [Link: http://bit.ly/2G8wns9](http://bit.ly/2G8wns9)
- McAllister WA, Thompson PJ, Al-Habet SM, Rogers HJ (1983) Rifampicin reduces effectiveness and bioavailability of prednisolone. *Br Med J (Clin Res Ed)* 286: 923-925. [Link: http://bit.ly/2XJEEsG](http://bit.ly/2XJEEsG)
- Hawkey CR, Yap T, Pereira J, Moore DA, Davidson RN, et al. (2005) Characterization and management of paradoxical upgrading reactions in HIV-uninfected patients with lymph node tuberculosis. *Clin Infect Dis* 40: 1368-1371. [Link: http://bit.ly/2G8yRa3](http://bit.ly/2G8yRa3)
- Planck SR, Huang XN, Robertson JE, Rosenbaum JT (1993) Retinal pigment epithelial cells produce interleukin-1 and granulocyte-macrophage colony-stimulating factor in response to interleukin-1. *Curr Eye Res* 12: 205-212. [Link: http://bit.ly/2YNb1YT](http://bit.ly/2YNb1YT)

### Discover a bigger Impact and Visibility of your article publication with Peertechz Publications

#### Highlights

- ❖ Signatory publisher of ORCID
- ❖ Signatory Publisher of DORA (San Francisco Declaration on Research Assessment)
- ❖ Articles archived in worlds' renowned service providers such as Portico, CNKI, AGRIS, TDNet, Base (Bielefeld University Library), CrossRef, Scilit, J-Gate etc.
- ❖ Journals indexed in ICMJE, SHERPA/ROMEO, Google Scholar etc.
- ❖ OAI-PMH (Open Archives Initiative Protocol for Metadata Harvesting)
- ❖ Dedicated Editorial Board for every journal
- ❖ Accurate and rapid peer-review process
- ❖ Increased citations of published articles through promotions
- ❖ Reduced timeline for article publication

**Submit your articles and experience a new surge in publication services**  
(<https://www.peertechz.com/submission>).

*Peertechz journals wishes everlasting success in your every endeavours.*

**Copyright:** © 2019 Priyanka, et al. This is an open-access article distributed under the terms of the Creative Commons Attribution License, which permits unrestricted use, distribution, and reproduction in any medium, provided the original author and source are credited.