



**JR Vijay Kumar, HS Natraj Setty*,
Rajiv Ananthkrishna, Rahul Patil,
Seetharama PS Bhat and CN
Manjunath**

Sri Jayadeva Institute of Cardiovascular Sciences and Research, Bengaluru, Karnataka, India

Dates: Received: 01 January, 2017; **Accepted:** 21 February, 2017; **Published:** 24 February, 2017

***Corresponding author:** Natraj Setty HS, Doctor, Sri Jayadeva Institute of Cardiovascular Sciences and Research Bangalore, #493, 4th Cross, 7th Main, JP. Nagar, 3rd Phase, Bangalore – 69, Karnataka, India, Tel: + 9845612322; + 080-26580051; Fax: + 080-22977261; E-Mail: drnatrajsetty75@gmail.com

Keywords: Left ventricular aneurys; Dor procedure; 2D Echo

<https://www.peertechz.com>

Case Report

Surgical Ventricular Restoration for Post infarction Left Ventricular Aneurysm

Abstract

Surgical ventricular restoration is a procedure designed to restore or remodel the left ventricle. Surgical ventricular restoration by means of the Dor procedure is a surgical option in patients with coronary artery disease, postinfarction left ventricular aneurysm (LV aneurysm) or ischemic dilated cardiomyopathy with or without ventricular tachycardia. Postinfarction left ventricular remodeling is characterized by LV dilatation and abnormal geometry leading to systolic and diastolic dysfunction. Development of a left ventricular aneurysm is a serious long-term complication of Acute Myocardial Infarction. We report a 69 year old male presented with haemodynamically significant ventricular tachycardia, successfully underwent DOR Procedure with complete recovery.

Case Profile

A 69 year- old- male, presented with hemodynamically significant ventricular tachycardia. His past history was significant for Ischemic heart disease, anterior wall myocardial infarction and PCI to LAD one year back. Electrocardiogram revealed evolved anterior wall myocardial infarction. Routine blood investigations were normal. Echocardiogram and cardiac MRI showed a true left ventricular apical aneurysm with severe left ventricular systolic dysfunction (Figure 1 A–D, Video-1). He successfully underwent Dor procedure prompt recovery on follow up (Figure 2 E–H, Video-2).

Discussion

Heart failure is a major health problem with increasing prevalence due to an aging population and more patients surviving acute myocardial infarction. Patients with moderate or severe heart failure have a poor prognosis, and despite major advances, long-term medical management alone may be insufficient. Cardiac transplantation and ventricular assist devices are definite or temporary surgical therapies [1]. Post infarction left ventricular remodelling is characterized by LV dilatation and abnormal geometry leading to systolic and diastolic dysfunction.

Development of a left ventricular aneurysm is a long-term complication of acute myocardial infarction, often leading to heart failure, ventricular tachycardia and thromboembolic events [2]. Surgical ventricular restoration (SVR) as described

by Dor and colleagues [3]. Was introduced to improve geometric reconstruction with respect to standard linear repair in Left ventricle aneurysm. Subsequently, Dor and colleagues [4]. Described that the technique was applicable not only to the classic aneurysm but also to large akinetic ventricles [5]. Dor and

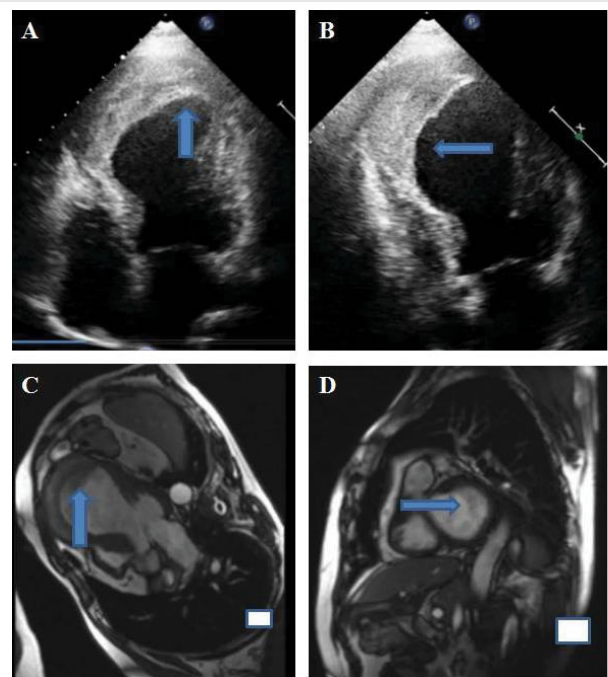
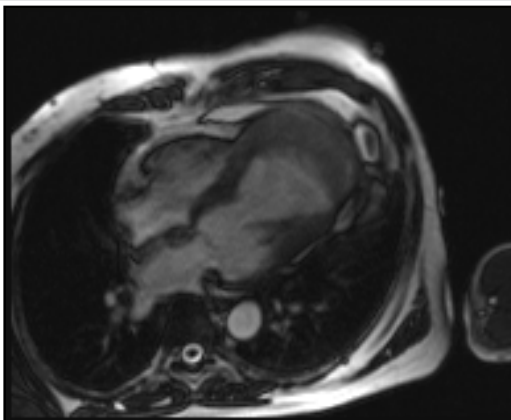


Figure 1: A and B: 2D Echo showing large LV aneurysm with organized clot C and D: Cardiac MRI in coronal and coaxial views showing large LV aneurysm with clot.

associates have reported excellent clinical and hemodynamic results of this procedure in several number of patients [6]. The Dor procedure excludes akinetic or dyskinetic portions of the anterior wall and septum, reshapes the Left ventricular with a stitch that encircles the transitional zone between contractile myocardium and aneurysmal tissue, and uses a patch to re-establish ventricular wall continuity [7]. By this technique, the operation improves size and geometry of the Left ventricle, reduces wall tension and paradox movement and enhances overall systolic function. In addition, the procedure may treat the ventricular arrhythmia complication and also allows for removal of intracavitary thrombi. Myocardial revascularization is almost always performed, Left ventricular reconstruction by the Dor procedure has subsequently been applied to patients with large akinetic ventricles [8].

Several surgical and device-based therapies have emerged in an attempt to reverse LV remodeling by restoring normal LV architecture and reducing LV volumes and wall stress. The parachute device (Cardiokinetix, Inc, Menlo Park,) emerged as a percutaneous device with the purpose of excluding the dysfunctional area of the LV, leading to a geometric reconfiguration and corresponding reductions in LV volumes.



Video 1: MRI showing large LV aneurysm with clot.

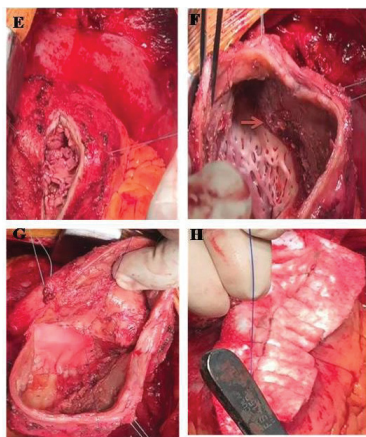
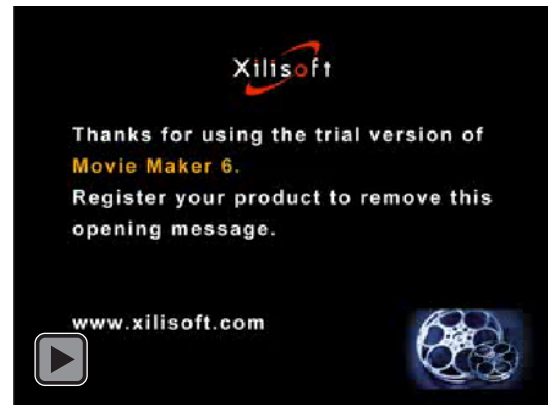

Figure 2: E: Incision over LV Aneurysm, F: Arrow showing Demarcation between LV and wall of aneurysm. G: Patch closure of Aneurysm cavity, H: Exteriorisation of aneurysm cavity



Video 2: Steps of Dors surgical procedure demonstration.

Conclusion

The Dor procedure is a reproducible surgical option for treatment of ischemic dilated cardiomyopathy or post-infarction left ventricular aneurysm. Left ventricular reconstruction by the Dor procedure has been applied to patients with large akinetic ventricles. We report a 69 year- old- male, presented with hemodynamically significant ventricular tachycardia he successfully underwent Dor procedure prompt recovery on follow up.

References

- Rose EA, Gelijns AC, Moskowitz AJ, Heitjan DF, Stevenson LW, et al. (2001) The randomized evaluation of mechanical assistance for the treatment of congestive heart failure (REMATCH) study group. Long-term use of a left ventricular assist device for end- heart failure. *N Engl J Med* 20: 1435–1443. [Link: https://goo.gl/JwvkbP](https://goo.gl/JwvkbP)
- Moss AJ, Zareba W, Hall WJ, Klein H, Wilber DJ, et al. (2002) The Multicenter Automatic Defibrillator Implantation Trial II Investigators. Prophylactic implantation of a defibrillator stage in patients with myocardial infarction and reduced ejection fraction. *N Engl J Med* 12: 877–883. [Link: https://goo.gl/73UyYc](https://goo.gl/73UyYc)
- Dor V, Saab M, Coste P, Kornaszewska M, Montiglio F (1989) Left ventricular aneurysm: a new surgical approach. *J Thorac Cardiovasc Surg* 37: 11–19. [Link: https://goo.gl/rPnfgO](https://goo.gl/rPnfgO)
- Dor V, Sabatier M, Montiglio F, Coste P, Di Donato M (1999) Endoventricular patch reconstruction in large ischemic wallmotion abnormalities. *J Card Surg* 14: 46–52. [Link: https://goo.gl/XG1NwQ](https://goo.gl/XG1NwQ)
- Donato DM, Sabatier M, Dor V, Toso A, Maioli M, et al. (1997) Akinetic versus dyskinetic postinfarction scar: relation to surgical outcome in patients undergoing endoventricular circular patch plasty repair. *J Am Coll Cardiol* 29: 1569–1575. [Link: https://goo.gl/cGkDc4](https://goo.gl/cGkDc4)
- Dor V, Di Donato M, Sabatier M, Montiglio F, Civaia F, et al. (2001) Left ventricular reconstruction by endoventricular circular patch plasty repair: a 17-year experience. *Semin Thorac Cardiovasc Surg* 14: 435–447. [Link: https://goo.gl/OMOhBd](https://goo.gl/OMOhBd)
- Bogaert J, Bosmans H, Maes A, Suetens P, Marchal G, et al. (2000) Remote myocardial dysfunction after acute anterior myocardial infarction: impact of left ventricular shape in regional function. *J Am Coll Cardiol* 35: 1525–1534. [Link: https://goo.gl/m9zQo8](https://goo.gl/m9zQo8)
- Di Donato M, Sabatier M, Dor V, Toso A, Maioli M, et al. (1997) Akinetic versus dyskinetic postinfarction scar: relation to surgical outcome in patients

undergoing endoventricular circular patch plasty repair. *J Am Coll Cardiol* 7: 1569–1575. [Link: https://goo.gl/88x3eF](https://goo.gl/88x3eF)

9. Mazzaferri EL Jr, Gradinac S, Sagic D, Otasevic P, Hasan AK, et al. (2012)

Percutaneous left ventricular partitioning in patients with chronic heart failure and a prior anterior myocardial infarction: Results of the Percutaneous Ventricular Restoration in Chronic Heart failure Patients Trial. *Am Heart J* 163: 812–820. [Link: https://goo.gl/u4hHwR](https://goo.gl/u4hHwR)

Copyright: © 2017 Vijay Kumar JR, et al. This is an open-access article distributed under the terms of the Creative Commons Attribution License, which permits unrestricted use, distribution, and reproduction in any medium, provided the original author and source are credited.

Citation: Vijay Kumar JR, Natraj Setty HS, Ananthakrishna R, Patil R, Seetharama PSB, et al. (2017) Surgical Ventricular Restoration for Post infarction Left Ventricular Aneurysm. *Int J Vasc Surg Med* 3(1): 017-019. DOI: <http://doi.org/10.17352/2455-5452.000022>