

Miron Fasoulakis¹, Alexandros Blionas¹, Evridiki Karanikola¹, George Galyfos^{2*}, Emannuel Barbaressos¹ and Konstantinos Filis²

¹Vascular Surgery Unit, Elpis General Hospital, Athens, Greece

²1st Department of Propaedeutic Surgery, University of Athens Medical School, Hippocraton Hospital, Athens, Greece

Dates: Received: 10 August, 2015; Accepted: 28 September, 2015; Published: 30 September, 2015

*Corresponding author: George Galyfos, 6 Melinas Merkouri Street, Neon Iraklion, 14122, Athens, Greece. Tel.: +30-213-2086343; Fax: +30-210-7707574; E-mail: georgegalyfos@hotmail.com

www.peertechz.com

ISSN: 2455-5452

Keywords: Isolated common iliac artery aneurysm; Contralateral deep vein thrombosis; Open surgery; Endovascular repair

Case Report

Management of a Common Iliac Artery Aneurysm Causing Contralateral Iliac Venous Thrombosis

Abstract

A 73-year-old male patient was diagnosed with thrombotic obstruction of the left common iliac vein (LCIV). Computed tomography imaging revealed a known -under follow-up- isolated aneurysm of the right common iliac artery that seemed to directly obstruct the LCIV. Given the patient's renal insufficiency as well as the size and anatomy of the aneurysm, the patient underwent open repair. The decision between open and endovascular repair, given the proximal DVT, is a dilemma, considering the risk for pulmonary embolism perioperatively as well as the venous thrombosis outcome postoperatively. Therefore, we present such an unusual case and discuss proper management.

Introduction

Aneurysms of the common iliac artery are rare, consisting less than 2% of all aneurysms [1]. Rarely, iliac artery aneurysms of significant size can obstruct venous outflow, manifesting as deep venous thrombosis (DVT). In these cases, DVT usually involves the ipsilateral, to the iliac artery aneurysm, iliac vein [2-5]. To our knowledge, there has been no case report to date referring to an isolated unilateral iliac artery aneurysm causing contralateral deep venous thrombosis due to iliac vein compression. Our aim is to present such an unusual case and make useful conclusions regarding proper management.

Case Report

A 73-year-old male patient presented in the emergency department complaining of pain and oedema in his left lower extremity for the last three days. His medical history revealed coronary artery disease under treatment, a recent percutaneous coronary angioplasty and renal insufficiency (serum creatinine: 2.2 mg/dl, clearance: 29.61 ml/min). The patient reported a known right common iliac artery aneurysm as well, followed-up closely with computed tomography (CT) imaging every year, for the last two years, in another institution. The patient reported that he had refused aneurysm treatment.

The previous CT evaluations revealed a steady increase in maximum aneurysm diameter: 5.5 cm at the beginning, 5.8 cm after one year, and finally, 6.2 cm with a 2.8 cm true lumen diameter on patient's admission CT (Figure 1). Ultrasound examination, as well as CT imaging, confirmed his clinical picture by illustrating a thrombosis of the left common iliac vein (CIV). Coloured duplex ultrasonography revealed a complete left CIV thrombosis extending from the iliac vein bifurcation to the origin of the left CIV. No floating thrombus extending proximally into the inferior vena cava, and no thrombosis of the right iliac veins were observed either. According to CT 3D-reconstruction analysis, there was a direct pressure effect from

the right common iliac artery on the left common iliac vein, which was the primary cause for iliac vein thrombosis and subsequent iliac vein obstruction (Figure 2). The aneurysm extended from precisely below the aortic bifurcation until just proximal to the right common iliac artery bifurcation, without affecting the aorta or the internal/external iliac arteries.

The patient was admitted to the vascular surgery unit, and systemic anticoagulation with subcutaneous fondaparinux (7,000 units per day) was initiated promptly. The patient was scheduled for open surgical repair. The decision to undergo open surgery rather than endovascular treatment was based on the following factors: (a) renal insufficiency, (b) size of the aneurysm and (c) lack of sufficient proximal and distal neck for placement of endovascular graft. Moreover, by open surgery, the aneurysm sac is evacuated and iliac vein compression is relieved. Finally, preoperative insertion of an inferior vena cava filter would be an option in this case. However, iliac vein thrombus was detected adherent to vein wall without any movement of a floating part, and therefore, the insertion of a filter could add the risk of migration during the infra-renal aortic dissection.

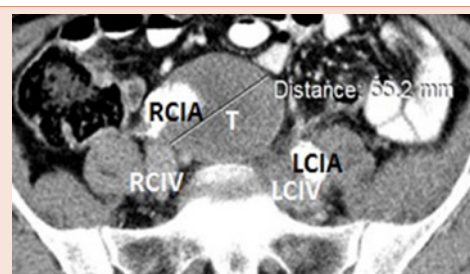


Figure 1: The aneurysm is shown close to its longest diameter. The right common iliac artery lumen (RCIA) is shown along with its thrombus (T) forming the aneurysm, and the left common iliac artery (LCIA) and vein (LCIV) are shown to be in close proximity to the aneurysm.

Regarding the surgical technique, a specific meticulous approach to the aneurysm, infra-renal aorta and iliac arteries was performed: a) Dissection was limited to the anterolateral walls of the arteries, no umbilical tapes or vessel loops were used to encircle their posterior walls in order not to dissect or get in proximity of the iliac veins; b) The patient was placed in 10 degrees anti-Trendelenburg position during the aneurysm dissection; c) A positive peep pulmonary pressure was initiated by the anesthesiologist during aneurysm clamping.; d) Evacuation of the aneurysm thrombus was completed very smoothly by irrigation with heparinized saline and using the surgeon's hand, taking into consideration not to apply any pressure on the left CIV or smash any thrombus by hand.

The internal iliac artery orifice was found obstructed, and an aorto-femoral bypass was performed, using an 8 mm Dacron graft (Figure 3). The proximal anastomosis was located almost 5 cm above the aortic bifurcation, and the distal anastomosis at the level of the common femoral artery bifurcation. Intraoperatively, the patient received intravenous unfractionated heparin as well. Surgical thrombectomy of the left CIV with an additional venous fistula was also an option. However, the patient had no strong indication for it (no leg phlegmasia) and the whole operative invasiveness would increase dramatically this way.

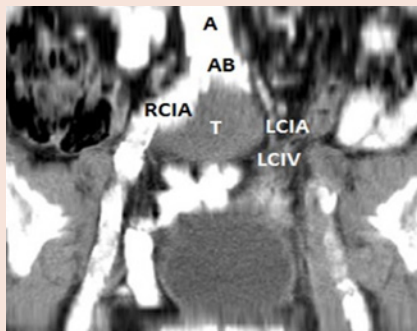


Figure 2: 3D reconstruction showing the iliac aneurysm, consisted of the right common iliac artery (RCIA) and thrombus (T). Its position and the pressure applied by the aneurysm to contralateral structures including the left common iliac vein (LCIV) and artery (LCIA) are clearly shown. The aorta (A) and the aortic bifurcation (AB) are clearly depicted to pinpoint aneurysm position.

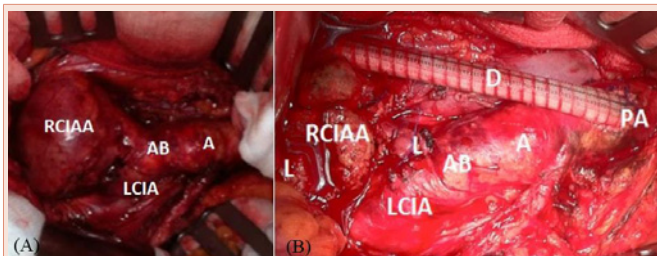


Figure 3: (A) The right common iliac artery aneurysm (RCIAA) is shown prior to resection. The aortic bifurcation (AB) is intact. The left common iliac artery (LCIA) is also visible, along with the aorta (A). (B) Proximal anastomosis (PA) of the aorto-femoral bypass with a dacron graft (D), 5cm above the aortic bifurcation (AB). The right common iliac artery aneurysm (RCIAA) is visible with ligations (L). The Left common iliac artery (LCIA) is also visible, as well as the aorta (A).

Finally, postoperative graft patency was optimal, with pulses palpated above the superficial and deep femoral arteries, and significant arterial blood flow peripherally confirmed by linear ultrasonography. Five months after surgery, patient's follow-up remains unremarkable. He has a complete iliac vein recanalization and he will discontinue fondaparinux in one month.

Discussion

Aneurysms of the common iliac arteries present therapeutic and surgical challenges [6]. In most cases, complex surgical techniques are required in order to restore proper vascular function [7]. In this case report, the aneurysm was of considerable size, significantly larger than the average sizes at which common iliac artery aneurysms are first diagnosed [8]. The delayed diagnosis could be easily explained as the diagnosis of isolated iliac artery aneurysm on physical examination is extremely difficult because of the deep pelvic location of these aneurysms and likely accounts for the high incidence of symptomatic or ruptured aneurysms in the past [9]. It is highly suggested that iliac artery aneurysms above 5 cm require prompt surgical repair since there is considerable risk of rupture [10,11]. The increasing size of the aneurysm and the absence of sufficient neck at the common iliac artery classified it as a suitable candidate for open surgical repair [1,8,12].

Although this aneurysm remained 3 years untreated with a considerable risk of rupture, it alternatively commenced applying pressure to contralateral structures leading to venous thrombosis. The expansion of this right iliac artery aneurysm from 5.5cm to 6.2cm should be considered as the main reason for left CIV thrombosis, and therefore DVT in this case might have been the result of non-optimal management.

Furthermore, it would be interesting to correlate this case report with the well-known May-Thurner syndrome. May-Thurner is a relatively rare syndrome and is defined by the pressure phenomenon caused by the right iliac artery towards the left iliac vein [13-15]. However, this case cannot be classified as May-Thurner syndrome for two main reasons: (i) In the case of May-Thurner, there is constant pressure applied by the right iliac artery, causing long term effects, such as left lower limb oedema, pain and recurrent deep venous thrombosis. In our patient, the right iliac artery had presumably been dilated at least 3 years since the first diagnosis, concurring with the natural history of iliac artery aneurysms [8]. Moreover, the patient had remained asymptomatic with no other episode of deep venous thrombosis reported before, excluding the existence of May-Thurner syndrome [16,17]. (ii) May-Thurner syndrome excludes cases of right common iliac artery aneurysms, since pressure dynamics and nutcracker effect, which is the key-point for May-Thurner syndrome is greatly altered in these cases [18,19].

Regarding proper management, the current consensus is that elective repair should be considered in good risk patients for isolated iliac artery aneurysms greater than 3 to 4 cm in maximal transverse diameter [8,20]. However, there are no official guidelines supporting either open or endovascular technique. Although, endovascular repair of isolated common iliac artery aneurysms has proved to be safe and effective, especially for high-risk patients [21,22], the traditional preferable choice for treatment of common iliac artery aneurysms, in standard risk patients, is open interposition graft repair [20].

Especially for common iliac aneurysms with compressive symptoms, Huang et al conclude in a large retrospective study that open repair is preferred [8]. Possibly, aneurysm sac evacuation during open repair decreases aneurysm compression on the vein, and therefore, promotes rapid vein recanalization and prevents post-thrombotic syndrome.

Abdominal surgery in the presence of acute DVT remains a debatable issue. Perioperative management should be modified in order to prevent pulmonary embolism. Conventional treatment is often not an option in the perioperative period, as surgical bleeding may be equally life threatening as a pulmonary embolism [23]. However, our patient was fully anticoagulated before, during and post-surgery, with satisfying results. Additionally, it is common practice to insert an inferior vena cava filter in such cases of higher risk for DVT preoperatively [24], especially if one is planning to perform a vein thrombectomy. However, this could further complicate the procedure, given the unfavorable morphology of the vein thrombus as shown in ultrasonography. Finally, aneurysm resection was mandatory for the good outcome of the venous thrombosis in our case, given that special measures would have been taken during surgery. A non-traumatic surgical approach, proper positioning of patient and positive peep pressure during mechanical ventilation are imperative.

Furthermore, chronic pressure of a common iliac artery aneurysm on a venous structure could lead not only to venous thrombosis but to arterio-venous fistula (AVF) formation as well [25]. Open repair seems to offer the advantage of fistula control within the aneurysmal sac, avoiding pulmonary embolization of debris from the aneurysm sac, although successful repair of AVFs using endovascular repair has also been reported [25]. However, open repair seems to be associated with a higher incidence of early postoperative complications, including cardiac events, and the risk of pulmonary embolism [8].

Conclusions

Large isolated common iliac artery aneurysms should be promptly treated after initial diagnosis. Deep vein thrombosis is a possible but rare complication of extensively postponing a common iliac artery aneurysm repair. Open surgery under proper intraoperative anesthesia and non-traumatic dissections could have satisfying results, even when no cava filter insertion or venous thrombectomy are performed.

References

- Melas N, Saratzis A, Dixon H, Saratzis N, Lazaridis J, et al. (2011) Isolated common iliac artery aneurysms: a revised classification to assist endovascular repair. *J Endovasc Ther* 18: 697–715.
- Cauley K, Wright P (2005) Iliac vein compression and pulmonary embolism in a long distance runner: computed tomography and magnetic resonance imaging—a case report. *Angiology* 56: 87–91.
- Rosenthal D, Matsuura JH, Jerius H, Clark MD (1998) Iliofemoral venous thrombosis caused by compression of an internal iliac artery aneurysm: a minimally invasive treatment. *J Endovasc Surg* 5: 142–145.
- Janczak D, Ruciński A, Skóra J, Szyber P (2000) [Iliac-femoral vein thrombosis as a first symptom of the isolated common and internal iliac artery aneurysm]. Article in Polish *Wiad Lek* 53: 458–461.
- Secil M, Sarisoy HT, Hazan E, Goktay AY (2003) Iliac artery aneurysm presenting with lower extremity deep vein thrombosis. *J Emerg Med* 24: 65–67.
- Bacharach JM, Slovut DP (2008) State of the art: management of iliac artery aneurysmal disease. *Catheter Cardiovasc Interv* 71: 708–714.
- Leon LR, Mills JL, Psalms SB, Goshima K, Duong ST, et al. (2007) A novel hybrid approach to the treatment of common iliac aneurysms: antegrade endovascular hypogastric stent grafting and femorofemoral bypass grafting. *J Vasc Surg* 45: 1244–1248.
- Huang Y, Gloviczki P, Duncan AA, Kalra M, Hoskin TL, et al. (2008) Common iliac artery aneurysm: expansion rate and results of open surgical and endovascular repair. *J Vasc Surg* 47: 1203–1210.
- Dix FP, Titi M, Al-Khaffaf H (2005) The isolated internal iliac artery aneurysm – a review. *Eur J Vasc Endovasc Surg* 30: 119–129.
- Kasirajan V, Hertzner NR, Beven EG, O'Hara PJ, Krajewski LP, et al. (1998) Management of isolated common iliac artery aneurysms. *Cardiovasc Surg* 6: 171–177.
- Buckley CJ, Buckley SD (2008) Technical tips for endovascular repair of common iliac artery aneurysms. *Semin Vasc Surg* 21: 31–34.
- Lee WA (2009) Branched endograft for aortoiliac artery aneurysms. *Vascular* 17: 111–118.
- Roebuck DJ, Barnacle AM (2011) May-Thurner syndrome. *Pediatr Blood Cancer* 57: 701.
- Suwanabol PA, Tefera G, Schwarze ML (2010) Syndromes associated with the deep veins: phlegmasia cerulea dolens, May-Thurner syndrome, and nutcracker syndrome. *Perspect Vasc Endovasc Ther* 22: 223–230.
- Dhillon RK, Stead LG (2010) Acute deep vein thrombus due to May-Thurner syndrome. *Am J Emerg Med* 28: 254.
- Dogan OF, Boke E. (2005) Three cases with May-Thurner syndrome: a possibly under-reported disorder. *Vasa* 34: 147–151.
- Cil BE, Akpınar E, Karcaaltincaba M, Akinci D. (2004) Case 76: May-Thurner syndrome. *Radiology* 233: 361–365.
- Mousa AY, AbuRahma AF. (2013) May-Thurner syndrome: update and review. *Ann Vasc Surg* 27: 984–995.
- Brazeau NF, Harvey HB, Pinto EG, Deipolyi A, Hesketh RL, et al. (2013) May-Thurner syndrome: diagnosis and management. *Vasa* 42: 96–105.
- Patel NV, Long GW, Cheema ZF, Rimar K, Brown OW, et al. (2009) Open vs. endovascular repair of isolated iliac artery aneurysms: A 12-year experience. *J Vasc Surg* 49: 1147–1153.
- Kim MD, Lee do Y, Lee M, Won JY, Lee SJ, et al. (2014) Single-center experience in the endovascular management of isolated iliac artery aneurysm. *Acta Radiol* 55: 195–200.
- Boules TN, Selzer F, Stanziale SF, Chomic A, Marone LK, et al. (2006) Endovascular management of isolated iliac artery aneurysms. *J Vasc Surg* 44: 29–37.
- Hall D (2013) Perioperative pulmonary embolism: detection, treatment, and outcomes. *Am J Ther*. 20: 67–72.
- Ozturk C, Ganiyusufoglu K, Alanay A, Aydogan M, Onat L, et al. (2010) Efficacy of prophylactic placement of inferior vena cava filter in patients undergoing spinal surgery. *Spine (Phila Pa 1976)*. 35: 1893–1896.
- Kopp R, Weidenhagen R, Hoffmann R, Waggerhauser T, Meimarakis G, et al. (2006) Immediate endovascular treatment of an aortoiliac aneurysm ruptured into the inferior vena cava. *Ann Vasc Surg* 20: 525–528.

Copyright: © 2015 Fasoulakis M, et al. This is an open-access article distributed under the terms of the Creative Commons Attribution License, which permits unrestricted use, distribution, and reproduction in any medium, provided the original author and source are credited.

Citation: Fasoulakis M, Blionas A, Karanikola E, Galyfos G, Barbaressos E, et al. (2015) Management of a Common Iliac Artery Aneurysm Causing Contralateral Iliac Venous Thrombosis. *Int J Vasc Surg Med* 1(1): 009-011. DOI: 10.17352/2455-5452.000004