



**Received:** 25 March, 2022

**Accepted:** 09 April, 2022

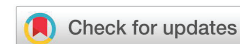**Published:** 11 April, 2022

**\*Corresponding author:** Deepak Jaiswal, MBBS, MS, MCH, CVTS, Assistant Professor, Department of CVTS Grant Government Medical College and sir JJ group of Hospitals, Mumbai-08, India, E-mail: born2savelives@gmail.com

**Keywords:** Subclavian artery; Pseudoaneurysm; Stab injury

**Copyright License:** © 2022 Jaiswal D. This is an open-access article distributed under the terms of the Creative Commons Attribution License, which permits unrestricted use, distribution, and reproduction in any medium, provided the original author and source are credited.

<https://www.peertechzpublications.com>



**Case report**

# Excision of delayed presented giant pseudoaneurysm of left subclavian artery post stab injury

**Deepak Jaiswal\***

MBBS, MS, MCH, CVTS, Assistant Professor, Department of CVTS Grant Government Medical College and sir JJ group of Hospitals, Mumbai-08, India

**Abstract**

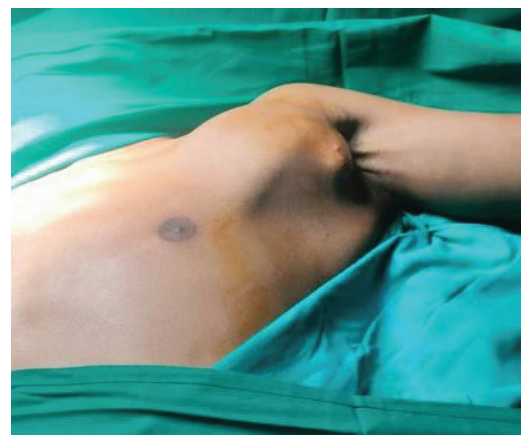Post-traumatic pseudoaneurysms involving the subclavian artery are uncommon and whenever diagnosed they should be repaired early because of the risk of complications such as thrombosis, gangrene, limb disability, and rupture may result in death if not reached the hospital early. Presenting a case report of a 20-year-old male who presented with a left subclavian artery pseudoaneurysm following a stab injury to the left axilla. He was referred to our institute, 20 days after the alleged assault. The presentation, diagnosis, and management of this injury are discussed.

**Introduction**

Penetrating Subclavian artery injuries account for less than 2% of all civilian vascular traumas [1,2]. Complicated local anatomy makes these injuries challenging even for experienced surgeons. Post-traumatic Subclavian artery pseudoaneurysm is rare. The most common site of post-traumatic pseudoaneurysm is the femoral artery, followed by the radial and brachial artery [3]. We are presenting a case of pseudoaneurysm of the left subclavian artery presented after 20 days of stab injury and was successfully treated by surgical excision of pseudoaneurysm with interposition grafting using PTFE graft for injured left subclavian artery.

**Case summary**

A 20-year-old male patient presented with an alleged history of stab injury to the left axillary region 20 days back that was treated primarily at a local hospital with skin suturing (Figure 1). There was no swelling when he visited the local hospital after his stab injury. After 10 days of stab injury, the patient noticed a pulsatile swelling in the left armpit which was initially small in size but increased rapidly within 10



**Figure 1:** Swelling in left deltopectoral region extending to left axilla.

days. The patient presented to our hospital after 20 days of stab injury with complaints of pain and swelling over the left shoulder region. On clinical examination swelling of 12cm×9cm over the left deltopectoral region extending into the left axilla. Left axillary, brachial, radial, and ulnar artery pulsations were palpable.

Upper limb computed tomography angiography revealed pseudoaneurysm from the third part of the left Subclavian artery with maximum anteroposterior and transverse length of pseudoaneurysm 78mm and 57mm respectively. The neck of the pseudoaneurysm was 3.4mm. The subclavian artery is 1.3cm proximal to the neck of the pseudoaneurysm and the first part of the axillary artery shows faint contrast opacification due to the external pressure effect of the pseudoaneurysm (Figure 2).

After a short preoperative work-up, the patient underwent surgical intervention under general anesthesia. Initially for distal vascular control left axillary artery was exposed and looped in the upper arm with a separate incision. Considering the CT angiography findings and the huge size of the aneurysm, the decision of mini sternotomy up to 4th intercostals space with left lateral extension (reverse J) was taken for proximal control of the subclavian artery. Thus, better exposure and the control of the proximal subclavian artery were done. After proximal and distal vascular control was secured, the pseudoaneurysm was dissected with a horizontal incision of 6 cm approximately extending over the left deltopectoral groove and the left anterior axillary fold. Dissection deepened, pectoralis major was divided partially and complete division of pectoralis minor was done to reach the pseudoaneurysm. Intravenous heparin (100IU/kg) was administered and after 3 minutes, the Proximally subclavian and distal axillary arteries were clamped. Pseudoaneurysm opened and a large number of clots, equivalent to 300–400ml removed. Dissection and separation of pseudoaneurysm followed by excision of the pseudoaneurysm sac (Figure 3) was done. A Rent of about 3 mm was noted in the third part of the subclavian artery. The subclavian arterial wall proximal and distal to the rent was unhealthy and friable, most likely due to the delayed presentation of the pseudoaneurysm. Left-sided supraclavicular incision taken to control left distal subclavian artery. Fogarty catheter of 4 French passed proximal and distal through the rent and there was no evidence of thrombus. After confirming adequate flow from both sides, an interposition grafting was done with a 6mm ring PTFE graft between the first part of the subclavian artery and proximal axillary artery in an end to side fashion (Figure 3a,3b). After achieving hemostasis two 14Fr Romovac drains were placed in the pseudoaneurysm cavity and a 28Fr chest drain tube in the pericardial cavity. Divided ends of the Pectoralis major muscle approximated. Sternum closed with steel wires, subcutaneous tissue and skin closed in layers.

Brachial, Radial, and ulnar artery pulsations were palpable and confirmed with a handheld Doppler. His postoperative recovery was uneventful. Pericardial drain and romovac drains were removed on the 2nd and 3rd Postoperative Day (POD) respectively and on the 5<sup>th</sup> postoperative day, patients were discharged. After two weeks of surgery on clinical examination, the wound was healthy and the arterial pulsations of the left upper limb were palpable. Also, there were signs of any neurological impairment. Doppler study was done on follow-up visit was found to be normal.

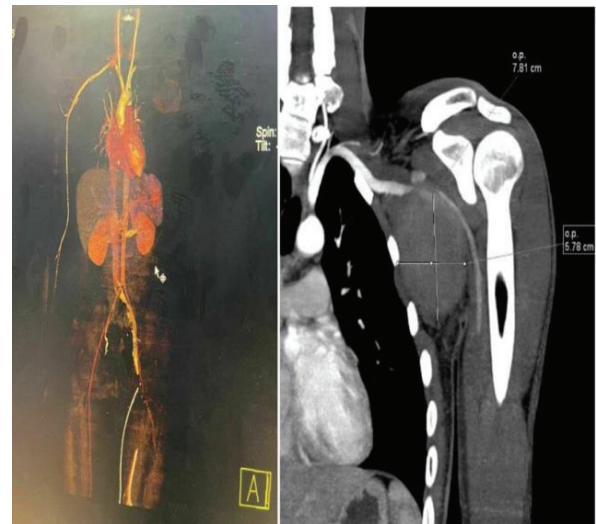

Figure 2: Computed tomography angiography showing subclavian artery pseudoaneurysm with 3 d reconstruction image.

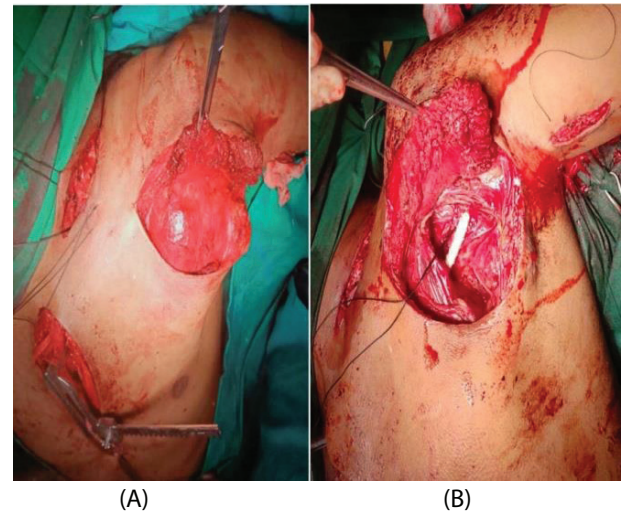


Figure 3: (A) Exposed Pseudoaneurysm. (B) Subclavian artery repaired with interposition graft with PTFE.

## Discussion

The most common cause of the post-traumatic pseudoaneurysm is invasive procedures such as post AV fistula dialysis needle puncture, central line insertion, and percutaneous coronary interventions. Inadvertent arterial puncture occurs in around 1% and 2.7% of jugular and subclavian approaches, respectively [4,5]. Penetrating stab injuries involving Subclavian arteries may become catastrophic because mortality of these cases prior to the hospitalization is about 75% and long-term morbidity of limb impairment due to brachial plexus injuries [6,7]. The clinical scenario of the Subclavian artery aneurysm depends on the aneurysm site and size. Extrathoracic pseudoaneurysm presents usually with pulsatile swelling over the deltopectoral region. Pseudoaneurysm rarely may erode the apex of the lung might cause hemoptysis, and may compress recurrent laryngeal nerves resulting in hoarseness of voice. There are also reports of dysphagia and Horner's syndrome as well.



Angiography is extremely helpful to diagnose the site of injury, the extent of the injury, and most importantly for planning the surgical approach. In our case, we used computed tomography angiography of the upper limb to confirm the size, and extent of the injury and to decide surgical approach for the operative procedure. In the management of subclavian artery pseudoaneurysm, recent literature confirms that the use of a subclavian artery stent to close the connection between the subclavian artery and pseudoaneurysm is not superior to surgical excision because there is a high risk for infection in an already formed pseudoaneurysm sac. A more delayed presentation may necessitate repair of subclavian artery rent with interposition grafting because delayed presentation may damage the artery in the pseudoaneurysm cavity. Excision of that pseudoaneurysm is mandatory [9].

Various surgical approaches have been mentioned in the literature for the management of Subclavian artery pseudoaneurysms like midline sternotomy, and anterolateral thoracotomy (trap door incision) [8,9]. In our case, we used the combination of mini sternotomy, a left-sided clavicular incision, and an incision in the left deltopectoral groove with excellent exposure to take adequate vascular control and to deal with the injuries with minimal risk of perioperative bleeding. When necessary, branch vessels of the aortic arch are supposed to be clamped or the operation should be performed in a profound hypothermic circulatory arrest with extracorporeal circulation. It is strongly recommended not to open the aneurysm sac if the aneurysm sac is found adherent to the surrounding tissues along with rich collateral circulation. In this scenario ligation of bilateral ends is effective as well.

There were no postoperative vascular and neurological complications in our patient. Concerning the brachial plexus injuries studies mentioned earlier, were encountered in 12% of cases and neurological impairment and disability remain the leading cause of morbidity in those cases.

## Conclusion

Proximal and distal control of the artery is a must for the safe management of any pseudoaneurysm. Early management is important to prevent complications such as infection, gangrene, and even death if a pseudoaneurysm ruptured. The recently published meta-analysis also suggests no superiority of subclavian artery stenting in such a giant pseudoaneurysm because even after closing the connection between the Subclavian artery with the pseudoaneurysm, the already formed pseudoaneurysm cavity is at a high risk of infection [10]. So excision of the Subclavian artery pseudoaneurysm is a must for good long-term results.

## References

- Wall MJ, Granchi T, Liscum K, Mattox KL (1996) Penetrating Thoracic Vascular Injuries. *Surg Clin North Am* 76: 749-761. [Link: https://bit.ly/3JmYlJa](https://bit.ly/3JmYlJa)
- Demetriades D, Rabinowitz B, Pezikis A, Franklin J, Palexas G (1987) Subclavian Vascular Injuries. *Br J Surg* 74: 1001-1003. [Link: https://bit.ly/3Kxx2T9](https://bit.ly/3Kxx2T9)
- Muller DW, Shamir KJ, Ellis SG, Topol EJ (1992) Peripheral Vascular Complications after Conventional and Complex Percutaneous Coronary Interventional Procedures. *Am J Cardiol* 69: 63-68. [Link: https://bit.ly/3xilu1p](https://bit.ly/3xilu1p)
- Eisen LA, Narasimhan M, Berger JS, Mayo PH, Rosen MJ, et al. (2006) Mechanical complications of central venous catheters. *J Intensive Care Med* 21: 40-46. [Link: https://bit.ly/3Ktyxlu](https://bit.ly/3Ktyxlu)
- Blaivas M, Adhikari S (2009) An unseen danger: frequency of posterior vessel wall penetration by needles during attempts to place internal jugular vein central catheters using ultrasound guidance. *Crit Care Med* 37: 2345-2349. [Link: https://bit.ly/3E3KxYy](https://bit.ly/3E3KxYy)
- McKinley AG, Carrim AA, Robbs JV (2000) Management of Proximal Axillary and Subclavian Artery Injuries. *Br J Surg* 87: 79-85. [Link: https://bit.ly/3LS2z2v](https://bit.ly/3LS2z2v)
- Aksoy M, Tunca F, Yanar H, Guloglu R, Ertekin C, et al. (2005) Traumatic Injuries to the Subclavian and Axillary Arteries: A 13-Year Review. *Surg Today* 35: 561-565. [Link: https://bit.ly/3KxYDUc](https://bit.ly/3KxYDUc)
- Demetriades D, Chahwan S, Gomez H, Peng R, Velmahos G, et al. (1999) Penetrating Injuries to the Subclavian and Axillary Vessels. *J Am Coll Surg* 188: 290-295. [Link: https://bit.ly/3030Lpa](https://bit.ly/3030Lpa)
- Koreny M, Riedmüller E, Nikfardjam M, Siostrzonek P, Müllner M (2004) Arterial Puncture Closing Devices Compared with Standard Manual Compression after Cardiac Catheterization: Systematic Review and Meta-Analysis *JAMA* 291: 350-357. [Link: https://bit.ly/3vbymEM](https://bit.ly/3vbymEM)
- Koreny M, Riedmüller E, Nikfardjam M, Siostrzonek P, Müllner M (2004) Arterial puncture closing devices compared with standard manual compression after cardiac catheterization: systematic review and meta-analysis. *JAMA* 291: 350-357. [Link: https://bit.ly/3vbymEM](https://bit.ly/3vbymEM)

Discover a bigger Impact and Visibility of your article publication with Peertechz Publications

### Highlights

- ❖ Signatory publisher of ORCID
- ❖ Signatory Publisher of DORA (San Francisco Declaration on Research Assessment)
- ❖ Articles archived in worlds' renowned service providers such as Portico, CNKI, AGRIS, TDNet, Base (Bielefeld University Library), CrossRef, Scilit, J-Gate etc.
- ❖ Journals indexed in ICMJE, SHERPA/ROMEO, Google Scholar etc.
- ❖ OAI-PMH (Open Archives Initiative Protocol for Metadata Harvesting)
- ❖ Dedicated Editorial Board for every journal
- ❖ Accurate and rapid peer-review process
- ❖ Increased citations of published articles through promotions
- ❖ Reduced timeline for article publication

Submit your articles and experience a new surge in publication services (<https://www.peertechz.com/submission>).

Peertechz journals wishes everlasting success in your every endeavours.