

Clinical Image

Exclusive Image Gallery on Human Spinal Cord Regeneration

Giselher Schalow*

MD, PhD, Untere Kirchmatte 6, CH-6207 Nottwil, Switzerland

Received: 22 May, 2019

Accepted: 15 June, 2019

Published: 16 June, 2019

*Corresponding author: Giselher Schalow, Professor, Untere Kirchmatte 6, CH-6207 Nottwil, Switzerland, E-mail: g_schalow@hotmail.com

<https://www.peertechz.com>

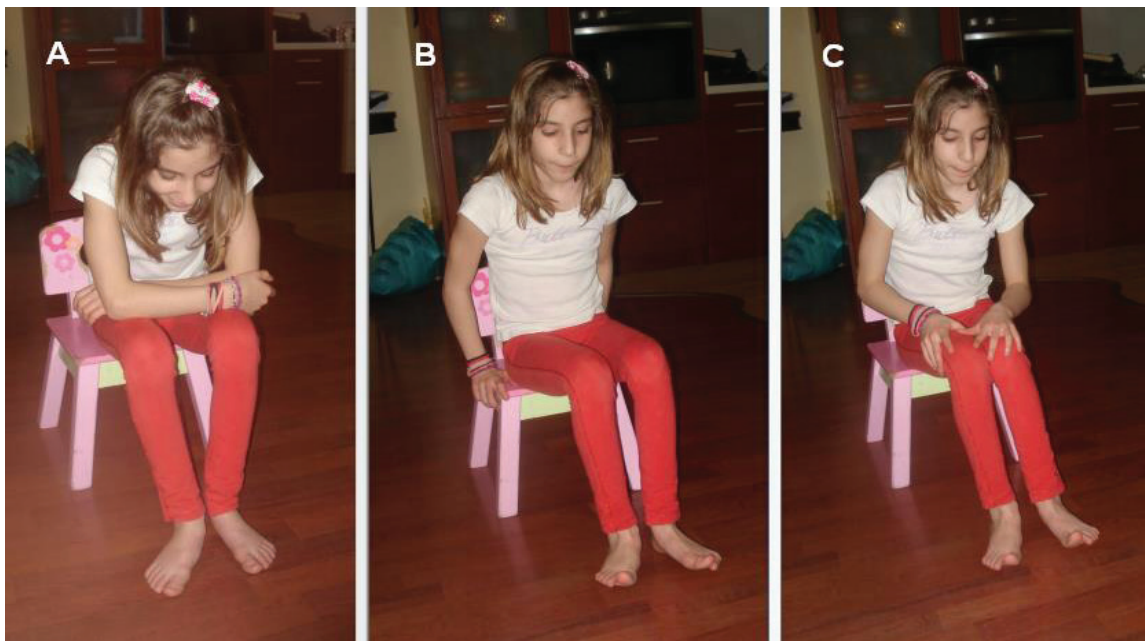


Figure 62: Ten-year-old Nefeli can move again the big toe separately four years after the accident and following 10.5 months of coordination dynamics therapy. In A she does not activate foot muscles and is relaxed. In B,C she concentrates and visualizes the task to activate the dorsal flexion of the big toe, which indicates that the spinal cord repair has reached with the activation of the hallucus longus the spinal cord segment L5.

Copyright: © 2019 Schalow G. This is an open-access article distributed under the terms of the Creative Commons Attribution License, which permits unrestricted use, distribution, and reproduction in any medium, provided the original author and source are credited.