

Clinical Image

Exclusive Image Gallery on Human Spinal Cord Regeneration

Giselher Schalow\*

MD, PhD, Untere Kirchmatte 6, CH-6207 Nottwil, Switzerland

Received: 22 May, 2019

Accepted: 15 June, 2019

Published: 16 June, 2019

\*Corresponding author: Giselher Schalow, Professor, Untere Kirchmatte 6, CH-6207 Nottwil, Switzerland, E-mail: [g\\_schalow@hotmail.com](mailto:g_schalow@hotmail.com)

<https://www.peertechz.com>

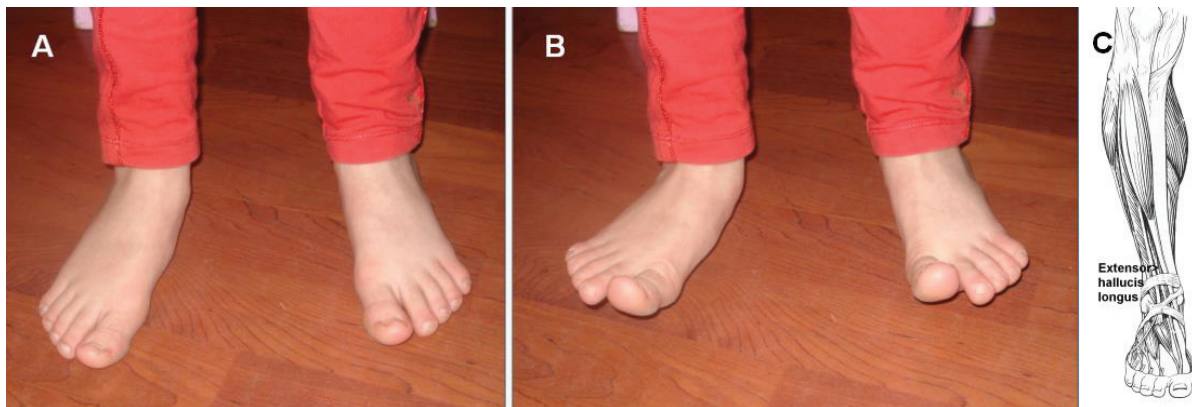


Figure 38: Activation of the hallucis longus muscle (C) when dorsal flexing the big toes separately (B). Spinal cord regeneration reached the L5 level.

Copyright: © 2019 Schalow G. This is an open-access article distributed under the terms of the Creative Commons Attribution License, which permits unrestricted use, distribution, and reproduction in any medium, provided the original author and source are credited.