

**Clinical Image**

**Exclusive Image Gallery on Human Spinal Cord Regeneration**

**Giselher Schalow\***

MD, PhD, Untere Kirchmatte 6, CH-6207 Nottwil, Switzerland

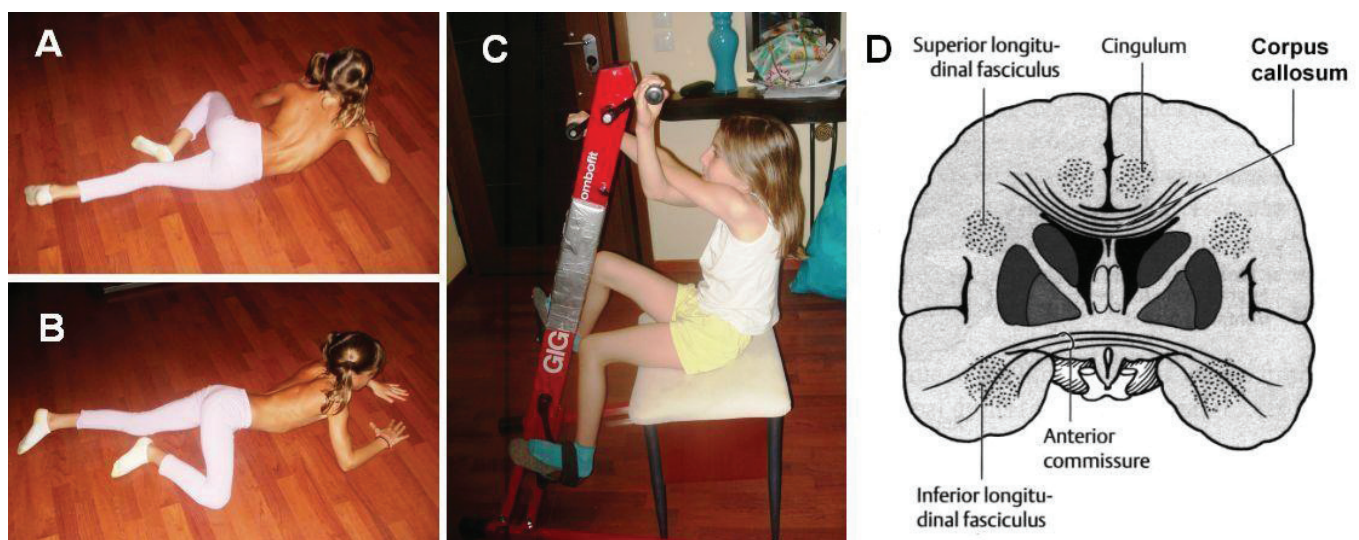
Received: 22 May, 2019

Accepted: 15 June, 2019

Published: 16 June, 2019

\*Corresponding author: Giselher Schalow, Professor, Untere Kirchmatte 6, CH-6207 Nottwil, Switzerland, E-mail: [g\\_schalow@hotmail.com](mailto:g_schalow@hotmail.com)

<https://www.peertechz.com>



**Figure 33:** A, B. Ten-year-old patient with an incomplete spinal cord injury at the Th10 level during creeping. Note, because of the severe scoliosis, the creeping is not symmetrical. The rotation to the left is limited because of the scoliosis. C. Training of right-left symmetry via the corpus callosum (D) when exercising on the special CDT device with crossed arms.

**Copyright:** © 2019 Schalow G. This is an open-access article distributed under the terms of the Creative Commons Attribution License, which permits unrestricted use, distribution, and reproduction in any medium, provided the original author and source are credited.