

Clinical Image

Exclusive Image Gallery on Human Spinal Cord Regeneration

Giselher Schalow*

MD, PhD, Untere Kirchmatte 6, CH-6207 Nottwil, Switzerland

Received: 22 May, 2019

Accepted: 15 June, 2019

Published: 16 June, 2019

*Corresponding author: Giselher Schalow, Professor, Untere Kirchmatte 6, CH-6207 Nottwil, Switzerland, E-mail: g_schalow@hotmail.com

<https://www.peertechz.com>

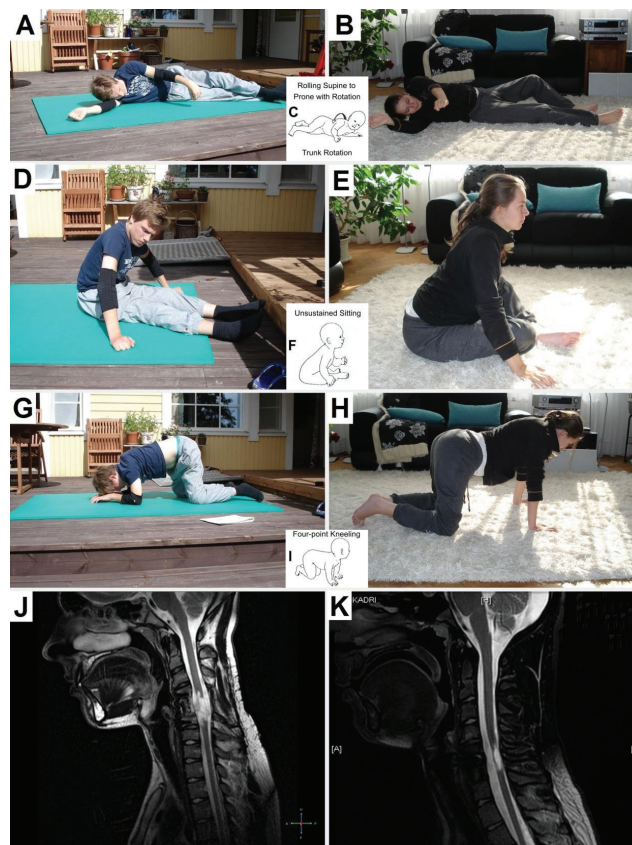


Figure 22: Comparison between development and the repair of an almost complete cervical spinal cord injury upon one year (A,C,G) (therapy started at an age of 15.5 years) and 5 years of coordination dynamics therapy (B,E,H) (CDT started with 17 years). The MRI of the SCI of the patient of the left panel is shown in 'J' and those one of the right panel in 'K'. Trunk rotation (A,B,C), un-sustained sitting (D,E,F), and four-point kneeling (G,H,I) is compared between one year and 5 years of CDT and with the positioning of an infant.

Copyright: © 2019 Schalow G. This is an open-access article distributed under the terms of the Creative Commons Attribution License, which permits unrestricted use, distribution, and reproduction in any medium, provided the original author and source are credited.