

Clinical Image

Exclusive Image Gallery on Human Spinal Cord Regeneration

Giselher Schalow*

MD, PhD, Untere Kirchmatte 6, CH-6207 Nottwil, Switzerland

Received: 22 May, 2019

Accepted: 15 June, 2019

Published: 16 June, 2019

*Corresponding author: Giselher Schalow, Professor, Untere Kirchmatte 6, CH-6207 Nottwil, Switzerland, E-mail: g_schalow@hotmail.com

<https://www.peertechz.com>

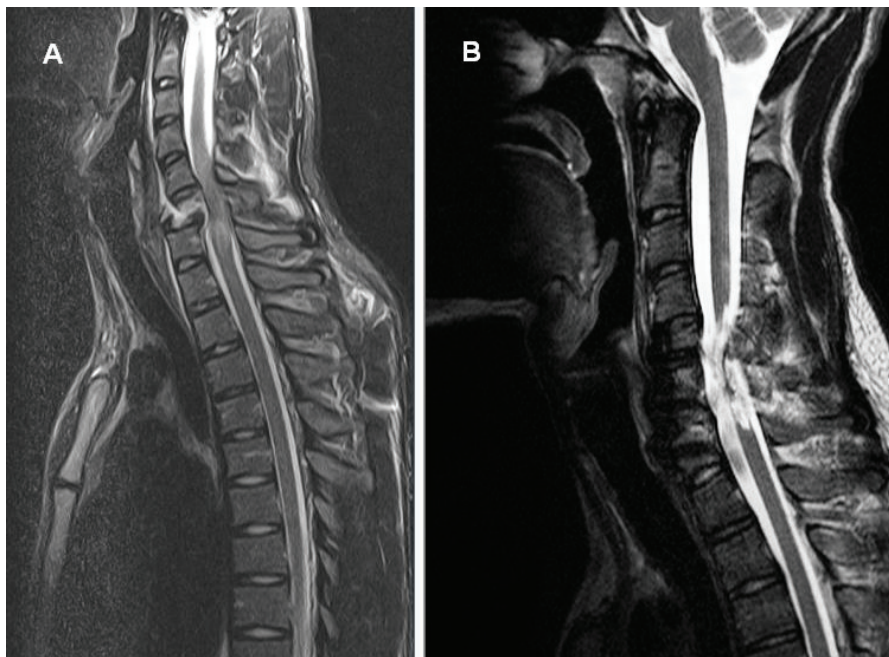


Figure 5: Cervical spinal cord injury of an 18-year old man approximately 8 hours after a motor cycle accident (A) and one year later (B).

Copyright: © 2019 Schalow G. This is an open-access article distributed under the terms of the Creative Commons Attribution License, which permits unrestricted use, distribution, and reproduction in any medium, provided the original author and source are credited.