

## Clinical Image

# Acute Myocardial Infarction on Contrast-Enhanced Computed Tomography

Akira Baba\*, Yumi Okuyama, Shinji Yamazoe and Takuji Mogami

Department of Radiology, Tokyo Dental College Ichikawa General Hospital, Chiba, Japan

\*Corresponding author: Akira Baba, M.D, Department of Radiology, Tokyo Dental College Ichikawa General Hospital, Chiba, Japan, E-mail: akirababa@jikei.ac.jp

Received: 21 January, 2016; Accepted: 04 February, 2016; Published: 06 February, 2016

## Keywords

Acute myocardial infarction; Computed tomography; Myocardial perfusion

## Text

A 79-year-old man presented to our emergency department with sudden back pain. Laboratory results showed CK 2836 U/L (normal range 30-160), CK-MB 393 U/L (<25), D-dimer 1.4 µg/mL (<1), BNP 37.9 pg/mL (<19.5), cTnl 0.133ng/mL (<0.028) and electrocardiogram showed ST elevation in V1~6. Acute myocardial infarction (AMI) was suspected. Because of the back pain, acute aortic dissection (AAD) and pulmonary thromboembolism (PE)

needed to be ruled out and contrast-enhanced computed tomography (CECT) was performed. CECT images showed no findings of AAD or PE. Instead, the images revealed the decreased enhancement in the interventricular septum and apex of the left ventricle (Figure A,B, arterial phase, Figure C,D, delayed phase). With the diagnosis of ST elevated MI (STEMI), emergent invasive coronary angiography was carried out to reveal total occlusion of LAD, corresponding to the CT findings. Percutaneous cardiac intervention was performed for LAD #6 first with plain old balloon angioplasty (POBA) and then thrombus aspiration, completed with drug-eluted stent (DES). The final coronary blood flow was TIMI III. The patient developed mild sub-acute pulmonary edema, which soon subsided with intravenous diuretics. The patient was released without complications.

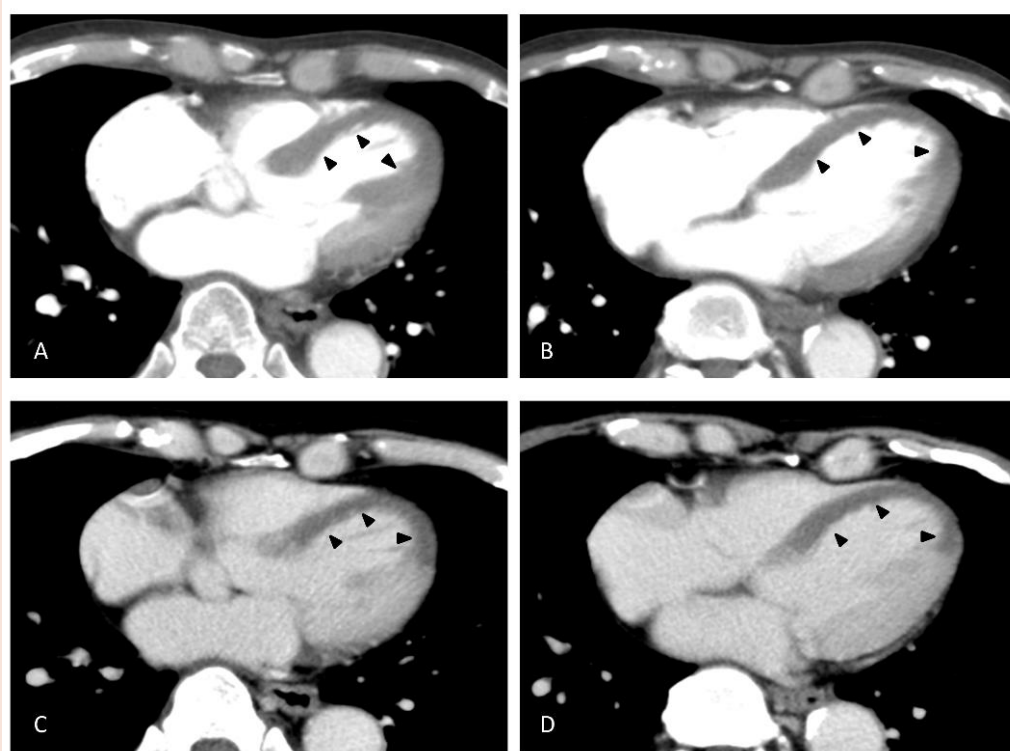


Figure 1:



When a patient presents with acute back pain, CECT is often ordered to evaluate aorta and pulmonary arteries. There have been cases reported where CECT revealed decreased perfusion in myocardium in patients with AMI, without increased cardiac biomarkers [1]. Assessing myocardial enhancement with CECT can be useful in detecting MI [2].

## References

1. Mano Y, Anzai T, Yoshizawa A, Ohki T (2015) Role of non-electrocardiogram-gated contrast-enhanced computed tomography in the diagnosis of acute coronary syndrome. *Heart Vessels* 30: 1-8.
2. Arnett JH, Mohajer K, Okon SA (2007) Evidence of acute myocardial infarction on CT. *Br J Radiol* 80: e219-221.

**Copyright:** © 2016 Baba A, et al. This is an open-access article distributed under the terms of the Creative Commons Attribution License, which permits unrestricted use, distribution, and reproduction in any medium, provided the original author and source are credited.

**Citation:** Baba A, Okuyama Y, Yamazoe S, Mogami T (2016) Acute Myocardial Infarction on Contrast-Enhanced Computed Tomography. *Imaging J Clin Med Sciences* 3(1): 004-005. DOI: 10.17352/2455-8702.000023