

Clinical Image

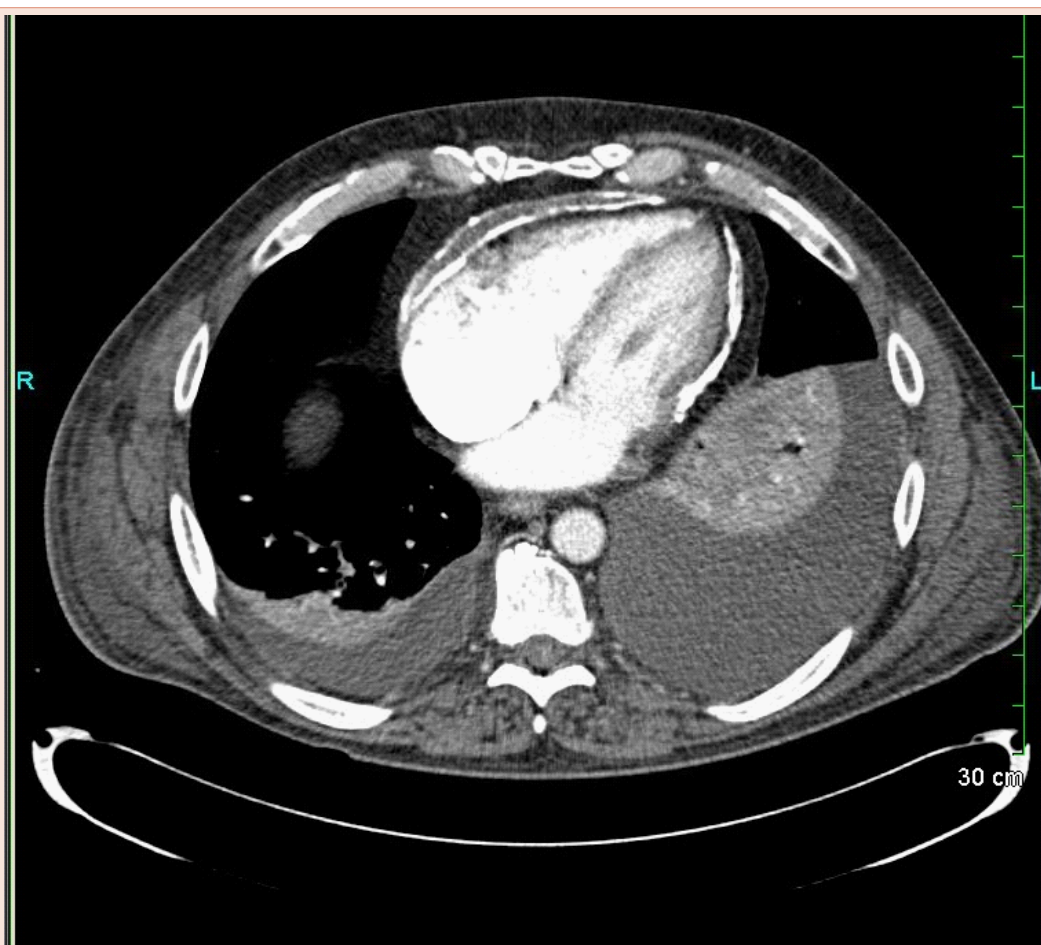
Extensive Pericardial Calcification in Constrictive Pericarditis

Khurram Tariq*, Farhangi Arezo and Rana Fauzia

University of Florida College of Medicine, Jacksonville, FL, USA

*Corresponding author: Khurram Bilal Tariq, MD, University of Florida, Department of Internal Medicine, 653 West 8th Street, Box L 18, Jacksonville, FL 32209, USA, Tel: 904-244-3093; E-mail: Khurram.Tariq@jax.ufl.edu

Received: June 27, 2014; Accepted: July 02, 2014; Published: July 03, 2014



Severe calcification of the pericardium with thickness measuring up to an impressive 1.2 cm leading to bi-atrial enlargement. The inter-ventricular septum is also straightened. All these findings are highly suggestive of constrictive pericarditis on the CT scan image shown above.