

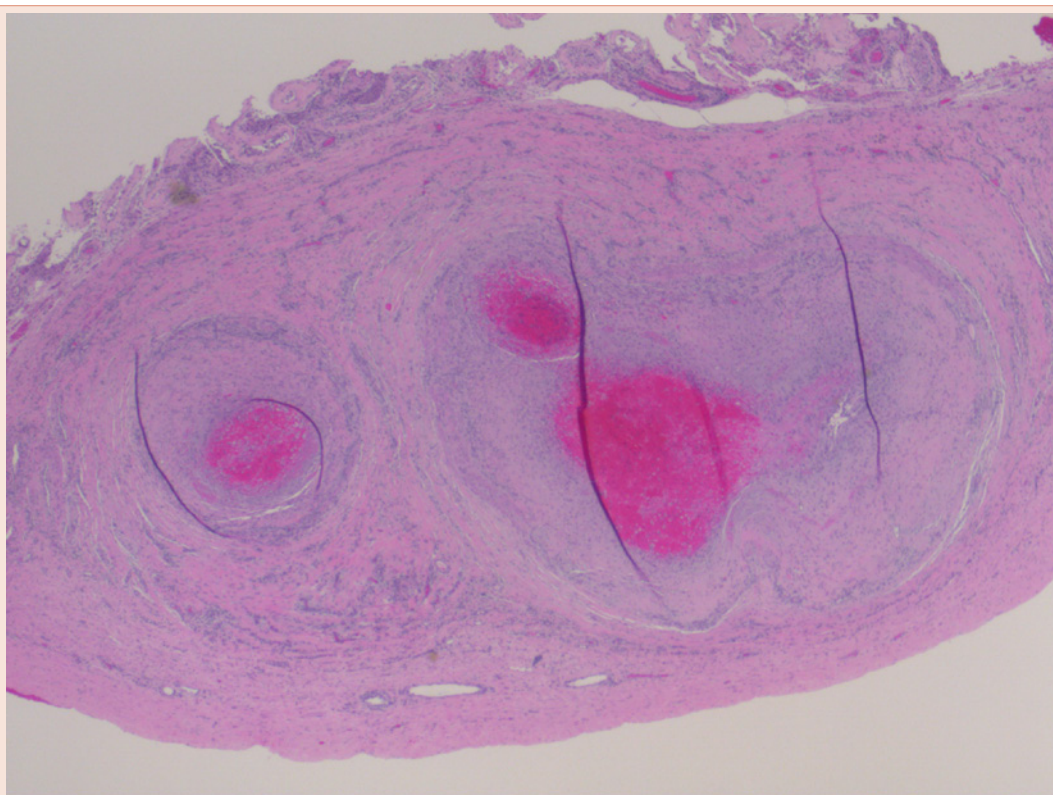
Isolated Right Testicular PAN (Polyarthriti s Nodosa) presenting as Right Testicular Pain

Khurram Tariq*, Arezo Farhangi and Fauzia Rana

University of Florida College of Medicine, Jacksonville, Fl, USA

*Corresponding author: Khurram Bilal Tariq, MD, University of Florida, Department of Internal Medicine, 653 West 8th Street, Box L 18, Jacksonville, FL 32209, USA, Tel: 904-244-3093; E-mail: Khurram.Tariq@jax.ufl.edu

Received: June 27, 2014; Accepted: July 02, 2014; Published: July 03, 2014



Patient is a 30 year old male with no significant past medical history who repeatedly sought medical attention for debilitating right testicular pain. Initially he was symptomatically treated with non-steroidal anti-inflammatory medications for presumptive diagnosis of testicular trauma. A few months later he went to different emergency department and was treated with antibiotics for presumptive diagnosis of epididymitis. Finally at his third presentation he was hospitalized. Three testicular biopsies were taken and only the biopsy sample from the middle area of the right testes revealed polyarthriti s nodosa. The Patient had no other signs and symptoms and this was likely isolated PAN of his right testes which is a very rare occurrence.