

Clinical Group

International Journal of Clinical Endocrinology and Metabolism

DOI: <http://dx.doi.org/10.17352/ijcem>

ISSN: 2640-7582

CC BY

Enver Simsek^{1*}, Tulay Simsek²,
Meliha Dermiral¹ and Mustafa F
Acikalin³

¹Departments of Pediatric Endocrinology, Eskisehir Osmangazi University School of Medicine, Eskisehir, Turkey

²Departments of Ophthalmology, Eskisehir Osmangazi University School of Medicine, Eskisehir, Turkey

³Departments of Pathology, Eskisehir Osmangazi University School of Medicine, Eskisehir, Turkey

Dates: Received: 02 December, 2016; **Accepted:** 29 December, 2016; **Published:** 30 December, 2016

***Corresponding author:** Enver Simsek, Prof. Dr., Eskisehir Osmangazi University School of Medicine, Department of Pediatrics and Division of Pediatric Endocrinology, 26480 Meselik, Eskisehir, Turkey, Tel: +905054962302; E-mail: enversimsek06@hotmail.com

Keywords: Children; Turkish; Genitourinary sarcoidosis; Testicular sarcoidosis; Testicular masses

<https://www.peertechz.com>

Case Report

Bilateral Painless Testicular Enlargement: An Unusual Presentation of Sarcoidosis and a Literature Review

Abstract

Background: Sarcoidosis is a systemic inflammatory disease characterized by non-caseating epithelioid granulomas; whereas it usually involves the lungs and lymph nodes, genitourinary involvement is extremely rare. For this reason, no consensus regarding the diagnostic and management options for testicular sarcoidosis has been reached.

Objective: The aim of this case report was to describe an unusual clinical presentation of sarcoidosis. An 8-year-old boy presented with a 6-month history of painless scrotal enlargement and a 2-month history of photophobia, blurred vision, and pain in both eyes. Physical examination revealed tearing, conjunctival hyperemia, and nodular lesions in both eyes as well as bilateral, nontender, irregularly shaped, and very hard testes. Laboratory investigations revealed elevated serum angiotensin-converting enzyme levels, and 8 fluoro-2-deoxyglucose positron emission tomography (FDG-PET) showed intense FDG accumulation in both testes. Testes biopsy showed non-caseating epithelioid granulomas, staining negative for acid-fast bacilli and fungi; tuberculosis culture was negative. A diagnosis of sarcoidosis was made.

Conclusions: This is the first reported case of testicular sarcoidosis in a Turkish child. Frozen section assessment is the most sensitive and reliable method for differentiating testicular masses. The diagnosis of testicular sarcoidosis should be made after excluding other inflammatory diseases characterized by non-caseating epithelioid granulomas.

Introduction

Sarcoidosis is a multisystemic inflammatory disease characterized by non-caseating epithelioid granulomatous lesions that classically affect the chest and lymph nodes. Extrapulmonary involvement is seen in 75% cases, but genitourinary sarcoidosis represents an extremely rare presentation of this condition [1–3]. Genitourinary involvement usually presents between the ages of 20 and 40 years. Due to its extreme rarity, there is no consensus regarding the diagnosis and management of testicular sarcoidosis. To date, seven cases of testicular sarcoidosis, including the present one, have been reported in patients < 20 years of age. The presence of firm and painless nodular enlargements of the testis should always be considered suspicious for malignancy. The aim of this study was to report an unusual presentation of sarcoidosis and to provide updated information regarding the diagnostic and management options for testicular sarcoidosis.

Case Report

An 8-year-old boy was referred to our pediatric

endocrinology outpatient clinic with a 6-month history of painless scrotal enlargement and a 2-month history of tearing, photophobia, blurred vision, and pain in both eyes. His parents denied constitutional symptoms or tuberculosis contacts, and his medical history was otherwise noncontributory. Family history was negative for tuberculosis or connective tissue disease. Physical examination revealed normal weight and height, with tearing and redness in both eyes. Testicular palpation revealed a nontender, firm, “woody” consistency, with the right and left testes measuring 35 × 25 mm and 38 × 28 mm, respectively (Figure 1A). The patient was then referred to the ophthalmology department. Ophthalmic examination revealed hyperemia and multiple translucent, yellowish nodules in the bulbar conjunctiva (Figure 1B). Slit-lamp biomicroscopy revealed fine keratitic precipitates on the corneal endothelium, 2+ cells in the anterior chamber, and scanty cells in the anterior vitreous, bilaterally, in accordance with the diagnosis of acute anterior uveitis. The ophthalmologist’s interpretation was that the granulomatous inflammation and yellowish nodules could be explained by tuberculosis, sarcoidosis, or lymphoma. The findings from the rest of the physical examination were normal,

including with respect to the respiratory and cardiovascular systems. A biopsy from the conjunctival nodular lesions was suggested, but the patient's parents refused.

Scrotal ultrasound revealed multiple, poorly defined intratesticular hypoechoic masses in both testes (Figure 2). Approximately 75% of the testicular parenchyma was occupied with these hyperechoic masses, and 8 fluoro-2-deoxyglucose positron emission tomography (FDG-PET) showed intense FDG uptake in both testes (Figure 3).

Laboratory examination revealed a white blood cell count of 5,350/mm³ with a normal differential; a hemoglobin level of 13.2 g/dL; an erythrocyte sedimentation rate (ESR) of 71 mm/h (normal range: 3–13 mm/h); a C-reactive protein (CRP) level of 7.62 mg/dl (normal, < 0.8 mg/dl); follicle-stimulating hormone and luteinizing hormone levels of 0.23 and 0.1 mIU/mL,

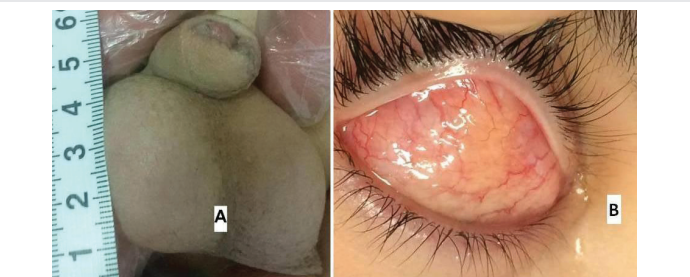

Figure 1: A: Photograph showing testicular enlargement. B: Photograph showing conjunctival hyperemia and yellowish nodules in the eye.

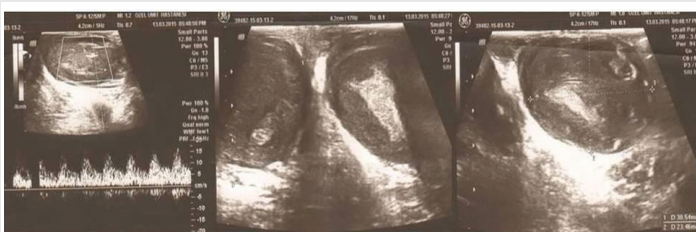

Figure 2: Gray-scale ultrasound images showing solid, ill-defined, hypoechoic masses in both testes replacing three-quarters of the normal testes parenchyma.

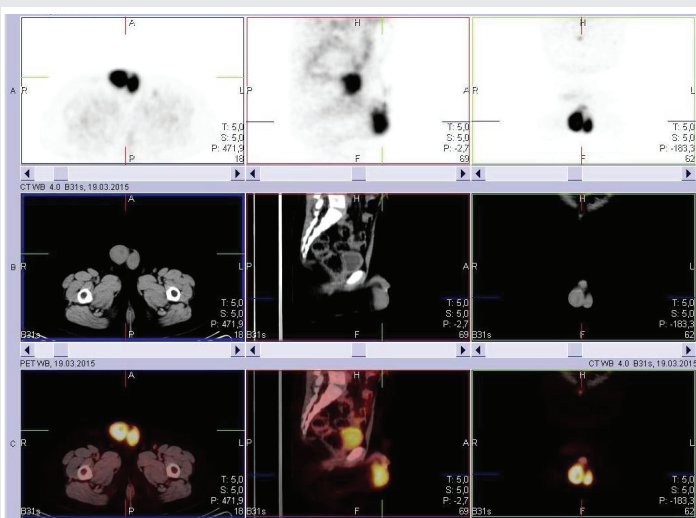


Figure 3: 18-fluorodeoxyglucose positron emission tomographies (FDG-PET) scan showing intense FDG accumulation in both testes.

respectively; a total testosterone level of < 2.5 ng/dL; a serum fibrinogen level of 514 mg/dL (normal range: 200–400 mg/dL); and a serum angiotensin-converting enzyme (ACE) level of 178 U/L (normal range: 8–55 U/L). Serum electrolyte levels and renal, pulmonary and liver function test results, were in the normal reference ranges. The 24-h urinary calcium excretion was 4.8 mmol/24 h (normal, 0–7.5 mmol/24 h). Serologic tests for autoimmune diseases revealed that antinuclear antibody (ANA) was positive at 1:320 and staining patterns were 2+ homogenous and 1+ granular, but anti-double stranded DNA, rheumatoid factor, and ENA panel (anti-RNP, anti-SSA, anti-SSB, anti-Sm, anti-Scl-70, Anti-Jo-1) as well as cytoplasmic and perinuclear antineutrophil antibodies (c-ANCA and p-ANCA, respectively) were negative. Tumor markers (serum α -fetoprotein [AFP] and β -human chorionic gonadotropin [β -HCG]) were negative, whereas lactate dehydrogenase (LDH) was at 503 IU/L (normal, 240–480 IU/L). The tube agglutination test for brucellosis, galactomannan antigen level for *Aspergillosis*, *Treponema pallidum* Western blot for syphilis, direct fluorescent antibody test for *Chlamydia* antigens, and serologic studies for histoplasmosis, coccidioidomycosis, and blastomycosis, were all negative. The intradermal purified protein derivate (PPD) skin test was also negative (0.05 μ g intra-dermal). On three consecutive days, fungal and mycobacterial culture from sputum and urine were negative. To distinguish testicular malignancy from benign testicular lesions, patient underwent bilateral inguinal exploration after written informed consent was obtained from the patient's parents. Incisional wedge biopsies were taken from both testes. Frozen section assessment showed non-caseating epithelioid granulomas, with most of the normal testicular parenchyma replaced by granulomatous inflammation (Figure 4). Stains for acid-fast bacilli and fungi and tuberculosis culture from testicular biopsy specimens were also negative. Based on the clinical presentation, the laboratory evaluations, and the histological report, the patient was diagnosed with testicular sarcoidosis. A chest roentgenogram and computed tomography (CT) of the thorax and abdomen were performed to assess other organ involvement; there were no abnormal findings. Prednisone (1 mg/kg daily) was started with a proton pump inhibitor. After 6 months of corticosteroid treatment, all symptoms and signs of acute uveitis disappeared, but testicular masses remained constant, and a diagnosis of iatrogenic Cushing's syndrome was made. Prednisolone treatment was tapered and discontinued.

Discussion

Sarcoidosis is a chronic inflammatory disease of unknown cause characterized by the formation of non-caseating epithelioid granuloma in various organs. The testes are rarely involved in sarcoidosis, being reported in less than 0.1% of all clinically diagnosed cases [2,4]. To the best of our knowledge, 71 cases of male genitourinary sarcoidosis, including our case, have been reported to date [2,3,5]. Manifestations of genitourinary sarcoidosis include typically painless, unilateral or bilateral, nodular epididymal or testicular enlargements. More than 80% of patients with genitourinary sarcoidosis present with intrathoracic involvement [6]. To our knowledge,

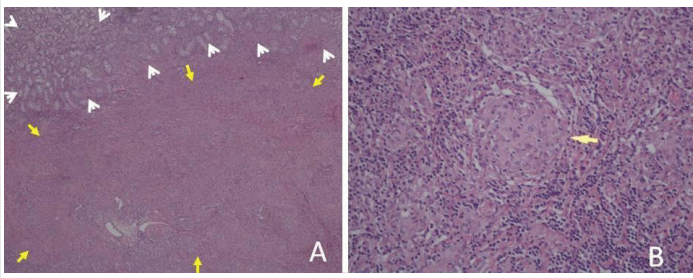


Figure 4: A: Non-caseating epithelioid granulomatous lesions of testes (arrows) and normal seminiferous tubules and interstitium (arrowheads) (H&E x40). B: Non-caseating epithelioid granulomatous lesions in the testes (arrow) (H&E x40).

seven cases, including ours, presented without thoracic involvement [2,7]. Sarcoidosis of the testicle typically occurs in 20- to 40-year-olds. To date, only seven cases of testicular sarcoidosis, including our patient, have been reported in patients less than 20 years of age [2,8–10]. Weinberg et al. [9], reported the youngest case of testicular sarcoidosis in a 2.5-year-old boy, and Hackney et al. [10], reported the case of a 7.5-year-old boy with this condition. We report the third-youngest case of testicular sarcoidosis, an 8-year-old boy; furthermore, this is the second case report of testicular sarcoidosis in Turkey [11]. A comprehensive literature review up to December 2016 showed that our case of sarcoidosis differed from the previously reported cases because the testis was the first organ involved.

Solid testicular masses in children are generally considered malignant until proven otherwise. Inguinal orchiectomy is the primary management option for most patients with a suspicious testicular mass [12]. Unfortunately, nearly one-third of patients with testicular sarcoidosis undergo unnecessary radical orchidectomy [2,3,13–15]. Although corticosteroids remain the principal treatment, side-effects are common with systemic steroids, depending on the dose and length of treatment. In addition, as in our case, some patients with testicular sarcoidosis are unresponsive to steroid treatment [16–18] or relapse when prednisone is stopped or reduced to < 10–15 mg/day [10,19]. The literature is unclear regarding the optimal duration of steroid therapy. Another important issue is that, without treatment, remission occurs in more than 50% of patients within 2–3 years of diagnosis [20]. When all these issues are taken into consideration, it is clear that there is an urgent need for consensus regarding the diagnosis and management of testicular sarcoidosis. The first issue concerns the differentiation of testicular sarcoidosis from malignant lesions, and the second issue pertains to the decision for radical orchiectomy in a patient diagnosed with unilateral or bilateral testicular sarcoidosis. Finally, there are uncertainties regarding the patient subgroups that require steroid treatment as well as the dose and duration of therapy. After a comprehensive literature review, we reached conclusions regarding all three issues.

In our case, due to diffuse the bilateral involvement of the testes with hypoechoic ill-defined masses, we suspected testicular malignancy, particularly lymphoma. Unfortunately, it is extremely difficult to differentiate testicular malignancies

from sarcoidosis based on the clinical presentation and imaging modalities. However, simultaneous testicular cancer plus sarcoidosis has been reported in several case reports [20–25] and case series [26–33]. In an epidemiologic study of 2,544 patients with respiratory sarcoidosis, Brincker and Wilbek [26], reported, that malignant lymphoma was 11-fold more prevalent and lung cancer 3-fold more prevalent than would be expected in the general population. In a retrospective study of 1,120 patients with germ cell tumor, nine cases had sarcoidosis in the presence of testicular tumor [27]. A retrospective study from the Mayo Clinic demonstrated a strong association between sarcoidosis and testicular tumors, with an approximately 100-fold increase in sarcoidosis in men with a history of testicular cancer treatment [29]. The study conducted by Askling et al. [30], included the largest cohort (n = 8,541) and found an overall increase in the relative risk for cancer (standardized incidence ratio = 1.3, 95% CI: 1.2–1.4). A review by Paparel et al. [31], noted the coexistence of sarcoidosis and testicular cancer. Hunt et al. [32], reported 21 cases of sarcoidosis accompanied by various malignancies. The most important conclusion from these studies is that sarcoidosis should always be considered in the differential diagnosis of testicular mass.

Clinical presentation, imaging studies, and laboratory investigations have limited value for differentiating benign from malignant conditions. The most common sonographic finding in testicular sarcoidosis is a poorly defined hypoechoic mass, but this is not specific to testicular sarcoidosis. In a series of FDG-PET investigations, the majority of patients with sarcoidosis showed intense FDG uptake at areas of sarcoidosis involvement [34–36], as in our case. FDG-PET may also show intense FDG uptake in testicular tumor cells, and it is therefore unlikely to be a helpful imaging method for differentiating between sarcoidosis and malignant tumors. The prevalence rate of ANA positivity in systemic sarcoidosis patients has been reported to be between 4% and 28% [37,38]. ANA positivity in patients with sarcoidosis may be suggestive of connective tissue disease, with which sarcoidosis may share a common immunopathogenic mechanism. Furthermore, mildly or moderately increased serum ACE levels have been reported in untreated active sarcoidosis, but such increases cannot be used for diagnostic purposes because ACE elevations can be seen in many diseases [39]. Additionally, in non-seminoma testicular cancers, serum AFP, β -HCG, and LDH levels are elevated in only 50% of patients [40]. On the other hand, as in our case, elevated LDH [15,33,41], AFP, and β HCG [42], levels have been reported in patients with sarcoidosis. For these reasons, tumor markers are neither sensitive nor specific for detecting testicular cancer. All these data indicate that histological examination remains the only sensitive and specific method for discriminating between benign and malignant testicular masses, as is the case in all the other organs.

Open biopsy, through an inguinal approach with intraoperative clamping of the spermatic cord, is preferred because of the potential for malignant diagnoses and to avoid seeding of malignant cells [15]. The other advantage of this method is that it allows for intra-operative frozen section assessment (and potential testicle preservation), but it can

progress to radical orchiectomy if this assessment suggests malignancy [43]. In our case, frozen assessment revealed non-caseating epitheloid granulomata, ruled out malignant testicular tumors, and prevented unnecessary orchiectomy.

Before a definitive diagnosis can be made, numerous other conditions with potentially similar pathologic findings should be ruled out. The differentials of testicular non-caseating epitheloid granulomas include infectious diseases (such as *Mycobacterium tuberculosis*, brucellosis, *Treponema pallidum*, *Chlamydia trachomatis*, and fungi infections), sperm granulomas, Wegener's granulomatosis [7], and sarcoidosis. Genitourinary tuberculosis is the second most common form of extrapulmonary tuberculosis after lymph node involvement [44]. It usually presents as a painful scrotal mass, which initially cannot be distinguished clinically from epididymo-orchitis or other mass lesions of the testes. Definitive diagnosis of tuberculosis involves demonstration of *M. tuberculosis* by microbiological or cytopathological results. Pelvic ultrasound examination is a poor modality for showing genitourinary changes in tuberculosis. In our patient, except for ESR, all the tests for tuberculosis were negative. However, elevated ESR is nonspecific and does not point to a specific disease. All tests for other infectious diseases and *Wegener's granulomatosis* were negative. Sperm granulomas are extratesticular, inflammatory lesions that are usually located adjacent to the testis or seminal vesicle and are associated with a history of infection, trauma, or prior surgery; there has been no previous report of this condition in pre-pubertal children [45]. Because our case was prepubertal, and granulomatous lesions were localized to the intratesticular space, sperm granuloma was ruled out. *Testicular sarcoidosis should be suspected when features of sarcoidosis exist elsewhere (e.g., on chest X-ray showing typical lung lesions, characteristic skin lesions, uveitis or conjunctival redness, or elevation of serum ACE or FDG uptake). After a prolonged workup, our patient was diagnosed with testicular sarcoidosis based on acute uveitis, elevated serum ACE level, elevated FDG uptake in the testes, and a characteristic histopathological report. Other inflammatory diseases characterized by epitheloid non-caseating granulomas were excluded.*

There have been only two large cohort studies on pediatric sarcoidosis; these included 46 and 41 cases, respectively [46,47]. Interestingly, no genital involvement was reported in either study. However, in our case, the first organ involved was the testis, followed by the eye. Recently, Nathan et al. [47], reported thoracic involvement in 56% of pediatric sarcoidosis patients, with liver and eye involvement in 49% and 39% of cases, respectively. Anterior uveitis is the most common ocular manifestation of sarcoidosis [48]. The signs of anterior uveitis secondary to sarcoidosis include granulomatous keratic precipitates, iris nodules, posterior synechiae, and peripheral anterior synechiae, as in our case. The definitive diagnosis of ocular sarcoidosis is made on the basis of uveitis compatible with sarcoidosis and biopsy of another organ supporting sarcoidosis [49]. We excluded mycobacterial infection during the work up for differentials of testicular non-caseating epitheloid granulomas. In light of our detailed work-up, the eye symptoms and signs in our sarcoidosis patient were

suggestive of ocular involvement; all these symptoms and signs disappeared following steroid treatment.

The effect of lesions on the fertility of testicular sarcoidosis patients, as well as the optimal management approach, has been debated. Currently, radical orchiectomy is suggested for patients with unilateral testicular sarcoidosis, indeterminate pathological findings, and possible testicular malignancy on a frozen section of the biopsy as well as for those in whom a diagnosis of malignancy is confirmed [50–52]. Before the decision for radical orchiectomy, surgical exploration and frozen section assessment may prevent unnecessary orchidectomy and preserve functional testes in patients who desire to be fertile in the future, as in our case. Long-term corticosteroid treatment of various doses has been reported for testicular sarcoidosis cases. Some authors have suggested that corticosteroids are indicated in genitourinary sarcoidosis because they can reduce testicular mass lesion size and pain and improve azospermia [53,54] in contrast, other studies have found that cases with epididymal or testicular involvement were unresponsive to corticosteroid treatment [16–18,55], as in our patient. It is well-known that long-term supraphysiological corticosteroid treatment has numerous side-effects. On the other hand, spontaneous total remission over a period of up to 3 years has been reported in 25–78% of sarcoidosis cases [2,20,46,47]. When all these data are *considered together*, corticosteroid treatment should be reserved for cases with vital organ involvement (such as the lungs, kidneys, eyes, heart, and central nervous system).

Sarcoidosis of the ovaries is an extremely rare and symptoms are usually nonspecific and presented with the clinical features concerning ovarian tumors [56]. According to our extensive English literature review from 1968 to date, only eleven cases of ovarian sarcoidosis reported [57–67]. To our knowledge, there are no specific radiological findings of genital sarcoidosis. The unusual clinical presentation of ovarian sarcoidosis, and the imaging features mimicking ovarian malignancies, the diagnosis of the previously reported cases of genital tract sarcoidosis was usually made on the basis of the histopathological examination of surgical specimens after the total abdominal hysterectomy with bilateral salpingo-oophorectomy (TAH-BSO). The diagnosis of pelvic sarcoidosis has been confirmed by demonstrating non-caseating granulomas in the ovarian cortex, fallopian tubes, uterus, and pelvic lymph nodes, and excluding the other granulomatous inflammatory diseases, such as tuberculosis, coccidiomycosis, lymphogranuloma inguinale, leprosy, Crohn's disease, and foreign body reaction [61,63]. To prevent of unnecessary TAH-BSO, especially in re-productive ages, laparoscopic tissue sampling from enlarged pelvic lymph nodes and ovaries for he histological examination is the only essential method for forming a differential diagnosis.

In conclusion, sarcoidosis cases with bilateral testicular involvement and poorly defined hypoechoic masses can be diagnosed by a combination of clinical presentation, laboratory tests (ACE, AFP, β -HCH), and frozen section assessment. Frozen section assessment and special staining techniques are the most sensitive and specific methods for differentiating

testicular masses and can prevent unnecessary orchidectomy; this is important for preventing future fertility issues. Radical orchiectomy should be performed only under special conditions. Testicular non-caseating epithelioid granulomas can also be differentiated by excluding other inflammatory diseases that are characterized by the same histological presentation. Long-term corticosteroid treatment for sarcoidosis should be decided according to the organs involved and is not indicated in all cases.

References

- Haas GP, Badalament R, Wonnell DM, Miles BJ (1986) Testicular sarcoidosis: case report and review of the literature. *J Urol* 135: 1254-1256. [Link: https://goo.gl/UKIOxt](https://goo.gl/UKIOxt)
- Kodama K, Hasegawa T, Egawa M, Tomosugi N, Mukai A, et al. (2004) Bilateral epididymal sarcoidosis presenting without radiographic evidence of intrathoracic lesion: Review of sarcoidosis involving the male reproductive tract. *Int J Urol* 11: 345-348. [Link: https://goo.gl/UKIOxt](https://goo.gl/UKIOxt)
- Esnakula AK, Coleman P, Ahaghotu CA, Naab TJ (2013) Scrotal mass and unilateral lung masses with pleural effusion mimicking metastatic testicular malignancy: an unusual presentation of sarcoidosis. *BMJ Case Rep*. pii: bcr2012008658. [Link: https://goo.gl/lkgPXR](https://goo.gl/lkgPXR)
- Turk CO, Schacht M, Ross L (1986) Diagnosis and management of testicular sarcoidosis. *J Urol* 135: 380-381. [Link: https://goo.gl/2eqr3c](https://goo.gl/2eqr3c)
- Carmody JP, Sharma OP (1996) Intrasacrotal sarcoidosis: case reports and review. *Sarcoidosis Vasc Diffuse Lung Dis* 13: 129-134. [Link: https://goo.gl/HCKDEa](https://goo.gl/HCKDEa)
- Rizzato G (2001) Extrapulmonary presentation of sarcoidosis. *Curr Opin Pulm Med* 7: 295-297. [Link: https://goo.gl/HzUMbu](https://goo.gl/HzUMbu)
- Ryan DM, Lesser BA, Crumley LA, Cartwright HA, Peron S, et al. (1993) Epididymal sarcoidosis. *J Urol* 149: 134-136. [Link: https://goo.gl/DV9uX3](https://goo.gl/DV9uX3)
- Torrington KG, Lewis PG, Tellis CJ, Swedarsky RH (1979) Systemic sarcoidosis presenting with a testicular nodule. *South Med J* 72: 1001-1103. [Link: https://goo.gl/h4E942](https://goo.gl/h4E942)
- Weinberg A, Ginsburg CM (1982) Epididymal sarcoidosis in a prepubertal child. *Am J Dis Child* 136: 71-72. [Link: https://goo.gl/Hj100u](https://goo.gl/Hj100u)
- Hackney RL Jr, Jackson AG, Worrell RG (1986) Sarcoidosis of the testis: a case report. *J Natl Med Assoc* 78: 65-68. [Link: https://goo.gl/jxID2J](https://goo.gl/jxID2J)
- Canguven O, Balaban M, Selimoglu A, Albayrak S (2013) Corticosteroid therapy improves the outcome of semen analysis in an oligozoospermic patient with epididymal sarcoidosis. *Korean J Urol* 54: 558-560. [Link: https://goo.gl/0CKVJV](https://goo.gl/0CKVJV)
- Motzer RJ, Agarwal N, Beard C, Bhayani S, Bolger GB, et al. (2012) National Comprehensive Cancer Network. Testicular cancer. *J Natl Compr Canc Netw* 10: 502-535. [Link: https://goo.gl/kNrupR](https://goo.gl/kNrupR)
- Eraso CE, Vrachliotis TG, Cunningham JJ (1999) Sonographic findings in testicular sarcoidosis simulating malignant nodule. *J Clin Ultrasound* 27: 81-83. [Link: https://goo.gl/6HkL9i](https://goo.gl/6HkL9i)
- Seaworth JF, Davis SJ, Donovan WN (1983) Aggressive diagnostic approach indicated in testicular sarcoidosis. *Urology* 21: 396-398. [Link: https://goo.gl/Yn1W0i](https://goo.gl/Yn1W0i)
- Woolf R, Toms L, Mann B (2010) Systemic sarcoidosis mimicking advanced testicular cancer. *JR Soc Med* 103: 251-253. [Link: https://goo.gl/GJAFYT](https://goo.gl/GJAFYT)
- Evans SS, Fisher RG, Scott MA, Kennedy BG, Brock JW 3rd, et al. (1997) Sarcoidosis presenting as bilateral testicular masses. *Pediatrics* 100: 392-394. [Link: https://goo.gl/dmWc1i](https://goo.gl/dmWc1i)
- Obinata D, Yamaguchi K, Hirano D, Fuchinoue A, Nemoto N, et al. (2007) Intrasacrotal involvement of sarcoidosis presenting like testicular appendices. *Int J Urol* 14: 87-88. [Link: https://goo.gl/ZaSRok](https://goo.gl/ZaSRok)
- Unsal A, Basturk T, Koc Y, Sakaci T, Ahbap E, et al. (2013) Renal sarcoidosis with normal serum vitamin D and refractory hypercalcemia. *Int Urol Nephrol* 45: 1779-1783. [Link: https://goo.gl/ccbKMA](https://goo.gl/ccbKMA)
- Johns CJ, Schonfeld SA, Scott PP, Zachary JB, MacGregor MI, et al. (1986) Longitudinal study of chronic sarcoidosis with low-dose maintenance corticosteroid therapy. Outcome and complications. *Ann N Y Acad Sci* 465: 702-712. [Link: https://goo.gl/gDRwBh](https://goo.gl/gDRwBh)
- Tjan-Heijnen VC, Vlasveld LT, Pernet FP, Pauwels P, De Mulder PH, et al. (1998) Coincidence of seminoma and sarcoidosis: a myth or fact? *Ann Oncol* 9: 321-325. [Link: https://goo.gl/hxRzje](https://goo.gl/hxRzje)
- Kok TC, Haasjes JG, Splinter TA, ten Kate FJ (1991) Sarcoid-like lymphadenopathy mimicking metastatic testicular cancer. *Cancer* 68: 1845-1847. [Link: https://goo.gl/PKFSuD](https://goo.gl/PKFSuD)
- Waterston A, Seywright M, White J (2006) A salutary tale of mistaken identity in testicular cancer. *Urol Oncol* 24: 407-409. [Link: https://goo.gl/0TI0wA](https://goo.gl/0TI0wA)
- Jegannathan A, Taylor MB, Jones M, Logue JP (2009) Testicular seminoma with mediastinal lymphadenopathy – a diagnostic pitfall. *Br J Radiol* 82: e85-86. [Link: https://goo.gl/2qN92B](https://goo.gl/2qN92B)
- Claus F, De Wever L, Moerman P (2012) Coincidence of seminoma and sarcoidosis in two patients presenting with peritoneal surface disease. *Int J Urol* 19: 1126. [Link: https://goo.gl/qHajTz](https://goo.gl/qHajTz)
- Teo M, McCarthy JE, Brady AP, Curran DR, Power DG, et al. (2013) A case of sarcoidosis in a patient with testicular cancer post stem cell transplant. *Acta Oncol* 52: 869-871. [Link: https://goo.gl/fs2Hll](https://goo.gl/fs2Hll)
- Brincker H, Wilbek E (1974) The incidence of malignant tumours in patients with respiratory sarcoidosis. *Br J Cancer* 29: 247-251. [Link: https://goo.gl/8bqSQh](https://goo.gl/8bqSQh)
- Brinker H (1989) Coexistence of sarcoidosis and malignant disease: Causality or coincidence? *Sarcoidosis* 6: 31-34. [Link: https://goo.gl/Ud51rJ](https://goo.gl/Ud51rJ)
- Leatham EW, Eeles R, Sheppard M, Moskovic E, Williams MP, et al. (1992) The association of germ cell tumours of the testis with sarcoid-like processes. *Clin Oncol (R Coll Radiol)* 4: 89-95. [Link: https://goo.gl/2VEWm9](https://goo.gl/2VEWm9)
- Rayson D, Burch PA, Richardson RL (1998) Sarcoidosis and testicular carcinoma. *Cancer* 83: 337-343. [Link: https://goo.gl/ENfMdq](https://goo.gl/ENfMdq)
- Askling J, Grunewald J, Eklund A, Hillerdal G, Ekblom A, et al. (1999) Increased risk for cancer following sarcoidosis. *Am J Respir Crit Care Med* 160: 1668-1672. [Link: https://goo.gl/mcuNqB](https://goo.gl/mcuNqB)
- Paparel P, Devonec M, Perrin P, Ruffion A, Decaussin-Petrucci M, et al. (2007) Association between sarcoidosis and testicular carcinoma: a diagnostic pitfall. *Sarcoidosis Vasc Diffuse Lung Dis* 24: 95-101. [Link: https://goo.gl/g4iOTnb](https://goo.gl/g4iOTnb)
- Hunt BM, Vallières E, Buduhan G, Aye R, Louie B, et al. (2009) Sarcoidosis as a benign cause of lymphadenopathy in cancer patients. *Am J Surg* 197: 629-632. [Link: https://goo.gl/qqJ82R](https://goo.gl/qqJ82R)
- Dick J, Begent RH, Meyer T (2010) Sarcoidosis and testicular cancer: A case series and literature review. *Urol Oncol* 28: 350-354. [Link: https://goo.gl/MYHg8z](https://goo.gl/MYHg8z)
- Nishiyama Y, Yamamoto Y, Fukunaga K, Takinami H, Iwado Y, et al. (2006) Comparative evaluation of 18F-FDG PET and 67Ga scintigraphy in patients with sarcoidosis. *J Nucl Med* 47: 1571-1576. [Link: https://goo.gl/Uxv8Xy](https://goo.gl/Uxv8Xy)
- Braun JJ, Kessler R, Constantinesco A, Imperiale A (2008) 18F-FDG PET/CT in sarcoidosis management: review and report of 20 cases. *Eur J Nucl Med Mol Imaging* 35: 1537-1543. [Link: https://goo.gl/lisBPS](https://goo.gl/lisBPS)

36. Ambrosini V, Zompatori M, Fasano L, Nanni C, Nava S, et al. (2013) (18)F-FDG PET/CT for the assessment of disease extension and activity in patients with sarcoidosis: results of a preliminary prospective study. *Clin Nucl Med* 38: e171-177. [Link: https://goo.gl/SMWqd3](https://goo.gl/SMWqd3)
37. Svendsen CB, Milman N, Høier-Madsen M, Dziegiel MH, Krogfelt KA, et al. (2008) Determination of rickettsial and antinuclear antibodies in Danish patients with sarcoidosis. *Clin Respir J* 2: 202-207. [Link: https://goo.gl/LCXhA6](https://goo.gl/LCXhA6)
38. Kobak S, Yilmaz H, Sever F, Duran A, Sen N, et al. (2014) The prevalence of antinuclear antibodies in patients with sarcoidosis. *Autoimmune Dis* 351852. [Link: https://goo.gl/xnloHI](https://goo.gl/xnloHI)
39. Costabel U, Hunninghake GW (1999) ATS/ERS/WASOG statement on sarcoidosis. Sarcoidosis Statement Committee. American Thoracic Society. European Respiratory Society. World Association for Sarcoidosis and Other Granulomatous Disorders. *Eur Respir J* 14: 735-737. [Link: https://goo.gl/rhTM7t](https://goo.gl/rhTM7t)
40. Gupta R, Senadhi V (2011) A diagnostic dilemma: metastatic testicular cancer and systemic sarcoidosis - a review of the literature. *Case Rep Oncol* 4: 118-124. [Link: https://goo.gl/RZQljb](https://goo.gl/RZQljb)
41. Venkitaraman R, Johnson B, Huddart RA, Parker CC, Horwich A, et al. (2007) The utility of lactate dehydrogenase in the follow-up of testicular germ cell tumours. *BJU Int* 100: 30-32. [Link: https://goo.gl/N0Uqac](https://goo.gl/N0Uqac)
42. Thuret R, Cariou G, Aerts J, Cochand-Priollet B (2008) Testicular sarcoidosis with elevated levels of cancer-associated markers. *J Clin Oncol* 26: 6007-6008. [Link: https://goo.gl/ZS7IHm](https://goo.gl/ZS7IHm)
43. Passman C, Urban D, Klemm K, Lockhart M, Kenney P, et al. (2009) Testicular lesions other than germ cell tumours: feasibility of testis-sparing surgery. *BJU Int* 103: 488-491. [Link: https://goo.gl/HS0Zoc](https://goo.gl/HS0Zoc)
44. Sharma SK, Mohan A (2004) Extra-pulmonary tuberculosis. *Indian J Med Res* 120: 316-353. [Link: https://goo.gl/R2z46c](https://goo.gl/R2z46c)
45. McDonald S (2000) "Cellular responses to vasectomy." *Int Rev Cytol* 199: 295-339. [Link: https://goo.gl/x6Qo6L](https://goo.gl/x6Qo6L)
46. Milman N, Hoffmann AL (2008) Childhood sarcoidosis: long-term follow-up. *Eur Respir J* 31: 592-598. [Link: https://goo.gl/ladGSA](https://goo.gl/ladGSA)
47. Nathan N, Marcelo P, Houdouin V, Epaud R, de Blic J, et al. (2015) RespiRare and the French Sarcoidosis groups. Lung sarcoidosis in children: update on disease expression and management. *Thorax* 70: 537-542. [Link: https://goo.gl/kDRwfk](https://goo.gl/kDRwfk)
48. Hoover DL, Khan JA, Giangiacomo J (1986) Pediatric ocular sarcoidosis. *Surv Ophthalmol* 30: 215-228. [Link: https://goo.gl/MXg5r4](https://goo.gl/MXg5r4)
49. Herbort CP, Rao NA, Mochizuki M, Bodaghi B, Baarsma SG, et al. (2009) International criteria for the diagnosis of ocular sarcoidosis: results of the first International Workshop on Ocular Sarcoidosis (IWOS). *Ocul Immunol Inflamm* 17: 160-169. [Link: https://goo.gl/ABFP2w](https://goo.gl/ABFP2w)
50. Wong JA, Grantmyre J (2006) Sarcoid of the testis. *Can J Urol* 13: 3201-3203. [Link: https://goo.gl/4uh8mK](https://goo.gl/4uh8mK)
51. Rao PK, Sabanegh ES (2009) Genitourinary sarcoidosis. *Rev Urol* 11: 108-113. [Link: https://goo.gl/e9oPwx](https://goo.gl/e9oPwx)
52. Torrington KG, Lewis PG, Tellis CJ, Swedarsky RH (1979) Systemic sarcoidosis presenting with a testicular nodule. *South Med J* 72: 1001-1003. [Link: https://goo.gl/U3YI8b](https://goo.gl/U3YI8b)
53. Rees DA, Dodds AL, Rathbone N, Davies JS, Scanlon MF, et al. (2004) Azoospermia in testicular sarcoidosis is an indication for corticosteroid therapy. *Fertil Steril* 82: 1672-1674. [Link: https://goo.gl/eomHC6](https://goo.gl/eomHC6)
54. Vasu TS, Lai RS, Amzuta IG, Nasr MR, Lenox RJ, et al. (2006) Sarcoidosis presenting as intrascrotal mass: case report and review. *South Med J* 99: 995-997. [Link: https://goo.gl/fkWWJ0](https://goo.gl/fkWWJ0)
55. Winnacker JL, Becker KL, Katz S, Matthews MJ (1967) Recurrent epididymitis in sarcoidosis. Report of a patient treated with corticosteroids. *Ann Intern Med* 66: 743-748. [Link: https://goo.gl/S5DzKd](https://goo.gl/S5DzKd)
56. Prabhakar HB, Rabinowitz CB, Gibbons FK, O'Donnell WJ, Shepard JA, et al. (2008) Imaging features of sarcoidosis on MDCT, FDG PET, and PET/CT. *AJR Am J Roentgenol* 190: S1-6. [Link: https://goo.gl/9yvPX5](https://goo.gl/9yvPX5)
57. Winslow RC, Funkhouser JW (1968) Sarcoidosis of the female reproductive organs. Report of a case. *Obstet Gynecol* 32: 285-9. [Link: https://goo.gl/vgrLiQ](https://goo.gl/vgrLiQ)
58. Chalvardjian A (1978) Sarcoidosis of the female genital tract. *Am J Obstet Gynecol* 132: 78-80. [Link: https://goo.gl/8xu1vS](https://goo.gl/8xu1vS)
59. White A, Flaris N, Elmer D, Lui R, Fanburg BL, et al. (1990) Coexistence of mucinous cystadenoma of the ovary and ovarian sarcoidosis. *Am J Obstet Gynecol* 162: 1284-1285. [Link: https://goo.gl/WZsCpd](https://goo.gl/WZsCpd)
60. Parveen AS, Elliott H, Howells R (2004) Sarcoidosis of the ovary. *J Obstet Gynaecol* 24:465. [Link: https://goo.gl/uQ6Y11](https://goo.gl/uQ6Y11)
61. Karmaniolas K, Liatis S, Dalamaga M, Mourouti G, Digeni A, et al. (2005) A case of ovarian sarcoidosis mimicking malignancy. *Eur J Gynaecol Oncol* 26: 231-232. [Link: https://goo.gl/EPK4eS](https://goo.gl/EPK4eS)
62. Honoré LH (1981) Asymptomatic genital sarcoidosis. *Aust N Z J Obstet Gynaecol* 21: 188-190. [Link: https://goo.gl/VuIPK3](https://goo.gl/VuIPK3)
63. Rosenfeld SI, Steck W, Breen JL (1989) Sarcoidosis of the female genital tract: a case presentation and survey of the world literature. *Int J Gynaecol Obstet* 28: 373-380. [Link: https://goo.gl/myHhMU](https://goo.gl/myHhMU)
64. Wuntakal R, Bharathan R, Rockall A, Jeyarajah A (2007) Interesting case of ovarian sarcoidosis: the value of multi-disciplinary team working. *World J Surg Oncol* 5:38. [Link: https://goo.gl/SPkPqi](https://goo.gl/SPkPqi)
65. Brown JV, Epstein HD, Chang M, Goldstein BH (2010) Sarcoidosis presenting as an intraperitoneal mass. *Case Rep Oncol* 3: 9-13. [Link: https://goo.gl/SeBxx9](https://goo.gl/SeBxx9)
66. Turkay R, Bakir B, Golabi UC, Topuz S, Ilhan HR, et al. (2015) Vanishing ovarian mass: Sarcoidosis. *Radiol Case Rep* 7:685. [Link: https://goo.gl/w6tHbF](https://goo.gl/w6tHbF)
67. Gorkem U, Gungor T, Bas Y, Togrul C (2015) Abdominal Sarcoidosis May Mimic Peritoneal Carcinomatosis. *Case Rep Obstet Gynecol* 263945. [Link: https://goo.gl/e7r5kc](https://goo.gl/e7r5kc)