

Bruno César da Silva<sup>1</sup>, Fábio Carneiro Vosqui Nascimento<sup>1</sup>, Sonyara Ruedys Oliveira Lisboa<sup>2</sup>, Eduardo Antônio Gonçalves Ramos<sup>3</sup>, Valdiana Cristina Surlo<sup>1</sup>, Tatiana Senna Galvão Nonato Alves<sup>4</sup> and Genoile Oliveira Santana<sup>1,5\*</sup>

<sup>1</sup>Universidade Federal da Bahia, Department of Gastroenterology - Salvador, Bahia, Brazil

<sup>2</sup>School of Medicine and Public Health, Faculty of Medicine - Salvador, Bahia, Brazil

<sup>3</sup>Gonçalo Moniz Research Center - Fiocruz, Histopathology Unit - Salvador, Bahia, Brazil

<sup>4</sup>Octávio Mangabeira Reference Hospital, Department of Pneumology - Salvador, Bahia, Brazil

<sup>5</sup>Universidade do Estado da Bahia - Health Science Department - Salvador, Bahia, Brazil

**Dates:** Received: 02 September, 2015; Accepted: 12 October, 2015; Published: 14 October, 2015

**\*Corresponding author:** Genoile Oliveira Santana, PhD, Universidade Federal da Bahia/ Hospital Universitário Prof. Edgard Santos, Gastroenterology Unit, Rua Augusto Viana, 1 - Canela, Salvador / Bahia/Brazil, 40110-060, Tel: +55 71 9957-2121; Fax: +55 71 3283-8141; E-mail: genoile@uol.com.br

[www.peertechz.com](http://www.peertechz.com)

ISSN: 2455-2283

**Keywords:** Inflammatory bowel disease; Anti-TNF; Tuberculosis

## Introduction

The use of monoclonal antibodies against tumor necrosis factor (anti-TNF) has revolutionized the treatment of Crohn's disease (CD). However a report of several cases of tuberculosis (TB) began to be reported during the use of biological therapy. Therefore, screening protocols for latent tuberculosis (LTB) were included in the evaluation of patients with CD before undergoing therapy with anti-TNF [1]. In Brazil, these protocols are based on the use of chest radiograph and tuberculin skin testing with a purified protein derivative (PPD) [2]. We report a case of CD patient that even with negative screening for LTB before starting treatment with anti-TNF, developed tuberculosis.

## Case Report

A 44-year-old man was diagnosed with CD in 1999. At the time, he complained of oral ulcers, abdominal pain and diarrhea for 6 months. A colonoscopy showed inflammation in the distal ileum mucosa and stenosis of the ileocecal valve. He had been using mesalazine until 2001, when he presented partial bowel obstruction. He was hospitalized and underwent another colonoscopy that showed hyperemia and edema of the ileocecal valve and terminal ileum with stricture and erosions covered by fibrin. In addition to using prednisone for 8 weeks, therapy with azathioprine at 2.5 mg/kg/day was started.

In March 2005, the patient developed perianal fistula, which required surgical treatment and, soon after, we chose to associate

## Case Report

# Mediastinal Tuberculosis Lymphadenitis during Anti-TNF Therapy - Case Report

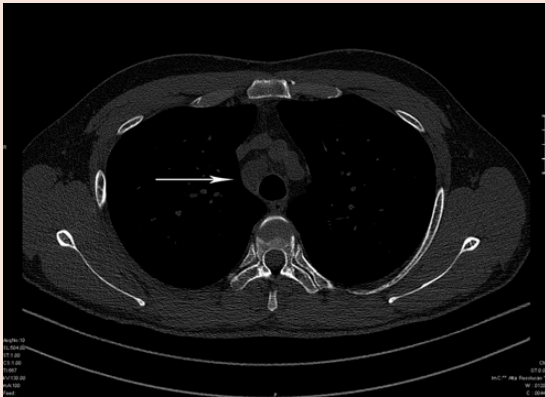### Abstract

Tuberculosis is described during the use of monoclonal antibodies against tumor necrosis factor (TNF) for Crohn's disease treatment. We report a case of a 44 year old man that developed fever, night sweats and weight loss during immunosuppressive and anti-TNF therapy for Crohn's disease. After extensive investigation we performed mediastinoscopy with biopsy of the paratracheal lymph node. A histopathological study revealed caseous necrosis. The patient improved after therapy against tuberculosis. During anti-TNF therapy, the diagnosis of tuberculosis may be mainly difficult when an atypical location is present. Clinical skills are important mainly in countries where tuberculosis is endemic.

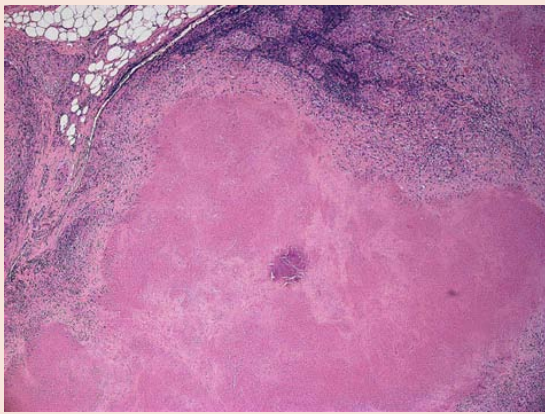
infliximab plus azathioprine. Before starting biologic therapy, PPD, chest radiography and serological markers of hepatitis B, hepatitis C and HIV were performed. All tests were negative. There was no report of prior contact with people with TB. Six weeks after the start of biologic therapy, the fistula closed and infliximab and azathioprine were maintained.

In September 2009, he was admitted to another hospital after an onset of fever and night sweats. A computed tomography (CT) of the chest and abdomen showed splenomegaly and mild bilateral pleural effusion. He was treated with ciprofloxacin and metronidazole and clinical improvement was observed. In October 2009, he returned to our clinic with fever and night sweats again. We requested a complete blood count (normal), PPD (energy), as well as new chest CT which was also normal. Infliximab was discontinued, and azathioprine monotherapy was maintained.

In August 2010, the patient returned and clinical findings suggested a reactivation of CD. At that moment, he no longer complained of fever. In addition, laboratory tests and CT of the abdomen ruled out the possibility of intra-abdominal abscess and pyogenic infections. Therapy was initiated with adalimumab, however eight days after the first dose (160mg) there was recurrence of fever. Once again, biological therapy was discontinued. Afterwards a chest CT revealed mediastinal lymphadenomegaly (Figure 1) and a PPD resulted a strong reaction (15mm). As a result, he underwent mediastinoscopy with lymph node biopsy. Histopathological analysis showed granulomas with caseous necrosis (Figure 2) compatible with TB lymphadenitis. Treatment was started for two months with rifampicin 600mg/day, isoniazid 300mg/day, pyrazinamide 1600mg/day and ethambutol 1100mg/day, followed by another 4 months of isoniazid and rifampicin, with the same dosages, according to the Brazilian guidelines for treatment of tuberculosis [2]. From the second week until the end of treatment, the patient developed remission of fever and night sweats. Due to the presence of CD clinical activity, a month after initiation of therapy against TB, budesonide 9mg/day was started, which resulted in clinical improvement.



**Figure 1:** High-resolution CT showing enlarged paratracheal lymph nodes (arrow).



**Figure 2:** Panoramic view of lymph node with extensive caseous necrosis and confluent granulomas (Hematoxylin and eosin; 40x magnification).

## Discussion

This patient with ileocecal CD and perianal fistula became refractory to azathioprine. In these cases, biologic therapy is indicated. Infliximab and adalimumab are anti-TNF agents effective for the treatment of CD refractory to conventional therapy [3].

Moreover, anti-TNF therapy increases the risk of TB reactivation in individuals with latent infection. Clinical forms of TB that occur during anti-TNF treatment are often extrapulmonary and disseminated. To prevent reactivation of TB, all patients should be screened for LTB before initiating immunosuppressive therapies, including TNF antagonists. The LTB should be treated as recommended by each country prior to starting anti-TNF therapy [4].

Even when submitted to the recommended protocol, which did not detect LTB, this patient developed TB lymphadenitis. Although adopted as an LTB screening method, PPD has recognized limitations. Vaccination with Bacille Calmette-Guérin (BCG) or exposure to other mycobacteria can cause false positive results, while false negatives may occur in immunosuppressed patients [5]. We believe that the immunosuppression caused by azathioprine contributed to the two

initial negative PPD. A study conducted in Brazil, where tuberculosis is endemic, showed that the PPD was not very effective in detecting LTB in patients with rheumatic diseases before undergoing biological therapy [6]. In recent years, new methods for detecting tuberculosis based on quantification of gamma-interferon after stimulation with specific antigens, known as IGRA (Interferon-Gamma Release Assay), have shown better results than PPD, including in immunosuppressed patients [7]. However, in a recent publication, Wong SH et al. demonstrated that IBD patients on immunosuppressive therapy had a significantly lower IGRA positive rate (13.0% versus 29.6%;  $P = 0.002$ ) compared to immunosuppressant-naïve IBD patients. The authors concluded that IGRA results are negatively impacted by immunosuppressive therapy and LTB testing seems to be better performed before the initiation of immunosuppressive therapies in IBD patients [8]. In Brazil, IGRA is still not routinely performed in clinical practice. One concern that has emerged over the last few months is the increasing unavailability of the tuberculin skin test.

During the first admission, eleven months before diagnosis of TB, it is likely that the fever, splenomegaly and pleural effusion were already due to LTB activation. The improvement may have occurred due to the use of ciprofloxacin, since the fluoroquinolones, in addition to being effective in the treatment of respiratory and urinary tract infections, also show antibacterial activity against *Mycobacterium tuberculosis* [9]. However, the use of fluoroquinolones alone and for a short period of time is associated with partial and temporary improvement of symptoms of tuberculosis, which contributes to its late detection [10].

Although uncommon, there are reported cases that demonstrate that the onset of fever is a side effect of the use of anti-TNF [11]. Before attributing the fever to the anti-TNF therapy, it is essential to rule out the occurrence of active infections. As our patient presented night sweats living in a country where TB is endemic, there was concern about maintaining clinical and laboratory surveillance, this was done in order to detect the occurrence of associated infection which resulted in a strong suspicion of TB reactivation during anti-TNF therapy.

## Conclusion

Despite the systematic screening for latent TB in individuals who will use anti-TNF therapy, some patients developed different forms of TB. The occurrence of fever and night sweats in the presence of anti-TNF therapy should raise suspicion of TB reactivation. The use of fluoroquinolones in these situations should be discouraged because they can mask symptoms and delay the detection. Considering poor access to tuberculin testing currently, countries with a moderate and high prevalence of tuberculosis, such as Brazil, should seek to validate IGRA in their populations in order to avoid the increase of TB activation during anti-TNF therapy.

## References

1. Theis VS, Rhodes JM (2008) Review article: minimizing tuberculosis during anti-tumour necrosis factor-alpha treatment of inflammatory bowel disease. *Aliment Pharmacol Ther* 27: 19-30.
2. Conde MB, Melo FA, Marques AM, Cardoso NC, Pinheiro VG, et al. (2009)

- III Brazilian Thoracic Association Guidelines on tuberculosis. *J Bras Pneumol* 35: 1018-1048.
3. Dignass A, Van Assche G, Lindsay JO, Lémann M, Söderholm J, Colombel JF et al. (2010) The second European evidence-based Consensus on the diagnosis and management of Crohn's disease: Current management. *J Crohns Colitis* 4: 28-62.
  4. Winthrop KL (2006) Risk and prevention of tuberculosis and other serious opportunistic infections associated with the inhibition of tumor necrosis factor. *Nat Clin Pract Rheumatol* 2: 602-610.
  5. Sester U, Junker H, Hodapp T, Schütz A, Thiele B, Meyerhans A et al. (2006) Improved efficiency in detecting cellular immunity towards M. tuberculosis in patients receiving immunosuppressive drug therapy. *Nephrol Dial Transplant* 21: 3258-3268.
  6. Callado MR, Lima JR, Nobre CA, Vieira WP (2011) Low prevalence of reactive PPD prior to infliximab use: comparative study on a population sample of Hospital Geral de Fortaleza. *Rev Bras Reumatol* 51: 40-52.
  7. Schoepfer AM, Flogerzi B, Fallegger S, Schaffer T, Mueller S, Nicod L et al. (2008) Comparison of interferon-gamma release assay versus tuberculin skin test for tuberculosis screening in inflammatory bowel disease. *Am J Gastroenterol* 103: 2799-2806.
  8. Wong SH, Ip M, Tang W, Lin Z, Kee C, Hung E et al. (2014) Performance of interferon-gamma release assay for tuberculosis screening in inflammatory bowel disease patients. *Inflamm Bowel Dis* 20: 2067-2072.
  9. Moadebi S, Harder CK, Fitzgerald MJ, Elwood KR, Marra F (2007) Fluoroquinolones for the treatment of pulmonary tuberculosis. *Drugs* 67: 2077-2099.
  10. Ang D, Hsu AAL, Tan BH (2006) Fluoroquinolones may delay the diagnosis of tuberculosis. *Singapore Med J* 47: 747-751.
  11. Katz J, Frank M (2012) Prolonged fever after Infliximab infusion. *World J Gastrointest Pharmacol Ther* 3: 34-35.

**Copyright:** © 2015 da Silva BC, et al. This is an open-access article distributed under the terms of the Creative Commons Attribution License, which permits unrestricted use, distribution, and reproduction in any medium, provided the original author and source are credited.

**Citation:** da Silva BC, Vosqui Nascimento FC, Oliveira Lisboa SR, Gonçalves Ramos EA, Surlo VC, et al. (2015) Mediastinal Tuberculosis Lymphadenitis during Anti-TNF Therapy - Case Report. *Arch Clin Gastroenterol* 1 (2): 038-040. DOI: 10.17352/2455-2283.000008