

Moussa O*, Mittapalli D and Suttie SA

Department of Vascular Surgery, Ninewells Hospital and Medical School, Dundee, UK

Dates: Received: 05 December, 2015; Accepted: 05 January, 2016; Published: 08 January, 2016

*Corresponding author: Osama M Moussa, Department of Vascular Surgery, Ninewells Hospital and Medical School, Dundee, DD1 9SY, UK, Tel: 01382 660111; E-mail: omoussa@doctors.org.uk

www.peertechz.com

ISSN: 2455-5452

Keywords: Peripheral; Aneurysms; Pseudoaneurysms; Management; Surgical; Radiological

Case Report

Infra-Inguinal Aneurysms – Threat to Life and Limb?

Abstract

Objectives: To assess the outcomes of infra-inguinal aneurysms admitted to a regional vascular unit.

Methods: All patients admitted with a primary diagnosis of infra inguinal aneurysms were identified from clinical coding lists over a four-year period (January 2008–May 2012). All patients were identified through clinical coding and records were checked to confirm diagnosis, management and outcome, with data analysed using SPSS v18.

Results: 39 patients (mean age 58.3yr, range 18-98), of which 27 were male, were identified (24 PseudoAneurysms (PA), 12 True Aneurysms (TA) and 3 Mycotic Aneurysms (MA)). The majority of the PAs were secondary to Intravenous Drug Abuse, IVDA (41%), followed by interventional procedures (29%), vascular anastomotic sites (13%), orthopaedic surgery (13%) and penetrating trauma (4%). 11/12 (92%) TAs were popliteal in origin, with 22/24 (92%) of PAs located at or around the femoral bifurcation. 22/24 of PA (12 surgical; 4 endovascular stenting; 1 ultrasound guided thrombin injection; 4 ultrasound guided compression; 1 embolisation), 8/12 of TA (7 surgical; 1 endovascular stenting) and 3/3 MA (2 surgical; 1 combined surgical + endovascular stenting) required intervention. One patient underwent primary major amputation (popliteal TA) with a further three patients requiring major amputation post intervention (1 MA post bypass procedure, 1 PA post vessel ligation, 1 PA secondary to percutaneous intervention presenting with distal embolization requiring vessel ligation). Overall 30-day mortality was 5.1% (n=2).

Conclusions: Our results suggest that the risk of major amputation and mortality secondary to infra-inguinal aneurysms as a pathology is significant.

Introduction

An increase in life expectancy, intravenous drug abuse and the number of vascular surgical interventions all have led to a parallel increase in the incidence of infra-inguinal aneurysms. Infra inguinal aneurysms can be life and limb threatening due to their potential to cause embolism, thrombosis, and compression of surrounding structures and depending on aetiology, rupture. True infra-inguinal arterial aneurysms (TA) are most commonly seen in the popliteal arteries, whereas pseudoaneurysms (PA) are seen mostly in the femoral artery [1]. The majority of true popliteal aneurysms remain asymptomatic with reported complication rates of 8% to 39% over 3 - 8 years follow up respectively [2,3]. Femoral pseudoaneurysms on the other hand are usually symptomatic with a reported complication rate of up to 47% [4]. Rupture is relatively uncommon for non-infected femoral PAs, with a reported incidence of 1 - 12% [5,6], but is potentially catastrophic [7]. Femoral PAs may present with acute thrombosis associated with substantial risk of limb loss (up to 28%) if collateral circulation is poor [6]. Hence, timely diagnosis and management before complications ensue is paramount.

Not only do infra-inguinal aneurysms pose a threat to limb, there is also an association between femoral, popliteal and aortic aneurysms, with the incidence of aorto-iliac aneurysms in those with popliteal and femoral aneurysms up to 62% and 85% respectively [6,8].

We describe our experience with infra-inguinal aneurysms admitted to a tertiary vascular department covering a catchment area of 800,000 inhabitants.

Methods and Methods

A comprehensive, retrospective data collection was performed, identifying all infra-inguinal aneurysms admitted between January 2008 and May 2012. Data were extracted through clinical coding lists cross referenced with radiology department diagnosis list and subsequent case note review, resulting in 39 patients diagnosed with infra-inguinal aneurysms being identified. Data collected included: patient characteristics (admission date, age, gender, presentation); pathological characteristics (type of aneurysms, location, infective status, presentation signs and symptoms as well as size, laterality and concomitant aneurysms); intervention details (type of intervention, details of surgery, complications and outcome) and amputation rate and 30-day mortality (including peri-operative and in hospital mortality).

Statistical analysis

Data were processed using the Statistical Package for Social Sciences, version 18.0 (SPSS, Inc., Chicago, IL, USA, 2007). Qualitative variables were summarised by frequency and percentage, while non-normally distributed quantitative variables were described by the median and range.

Results

A total of 39 patients diagnosed and admitted to the vascular surgical unit with infra-inguinal aneurysms between January 2008 and May 2012, were identified, with a mean age of 56 years (range 18-98), of which 27 were males.

PAs accounted for 24/39 (median age 49 years, range 18-85), TAs 12/39 (median age 76 years, range 65-98) and MAs for 3/39 (median age 55 years, range 51-69), **Table 1**, **Figure 1** depicts the management pathways and outcomes.

Presentation

The majority of our sample had a symptomatic presentation, 31/39. 23/24 of the PAs were symptomatic on admission, with the majority presenting with localized pain and swelling with or without a discharge from an overlying sinus. One PA was asymptomatic and identified on graft surveillance following infra-inguinal arterial reconstruction for occlusive disease. 5/12 of the TAs presented with localized pain and swelling (all 5 located at the popliteal artery), with 4/12 presenting with short distance intermittent claudication (3 popliteal TAs, 1 common femoral TA), 2 presenting with critical limb ischaemia (both popliteal TAs) and the final TA presenting with acute limb ischaemia (popliteal TA). Three of the aneurysms were classed as mycotic, with presentations of intermittent claudication, acute limb ischaemia and localized painful swelling, and all three were located at different sites (**Table 2**).

Etiology

Etiology of each type of aneurysm was studied and 10/24 PAs (41.7%) were the direct result of Intra Venous Drug Abuse (IVDA), all of which were infected, with only one other PA (post interventional procedure) presenting with localized sepsis. The remaining were secondary to percutaneous access for interventional procedures (7/24, 29.2% - 5 post coronary intervention, 2 post interventional radiology), disruption of vascular anastomosis for lower limb arterial reconstruction (3/24, 12.5%), following orthopedic procedures (3/24, 12.5%) and following non iatrogenic trauma (1/24, 4.2%). **Table 2** displays the site of the aneurysms, with the common femoral artery being the predominant site.

Size

The median size of the aneurysm sac was 30mm (range 10-93). Whilst the median diameter of the TAs was 41.5 mm (range 20-62). True aneurysm of the CFA measured 32mm and all other popliteal TA with a mean of 40.6mm and a median of 43mm. The median sac diameter was 41mm (range 38-50) in mycotic aneurysms.

Management

22/24 underwent some form of intervention, **Table 3** with 12 requiring open surgical intervention. All 10 PAs due to IVDA required vessel ligation, 1 of which culminated in major lower limb

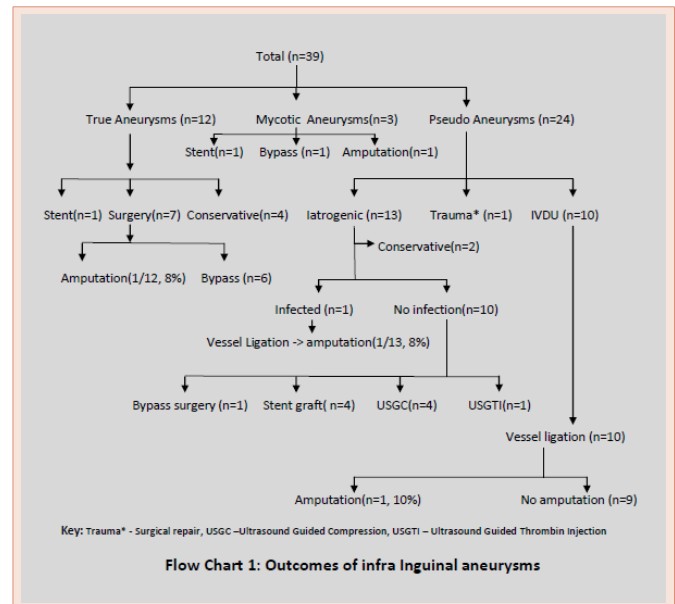


Figure 1: Outcomes of infra Inguinal aneurysms.

Table 2: Aneurysm site.

	Site				
	Common Femoral Artery	Profunda Femoris Artery	Superficial Femoral Artery	Popliteal Artery	Crural Artery
Pseudoaneurysm	15	2	5	1	1
True Aneurysm	1	0	0	11	0
Mycotic Aneurysm	1	0	1	1	0

amputation with a further patient requiring ileo-femoral bypass for limb salvage. One infected PA following an interventional procedure for iliac occlusive disease, required vessel ligation of the common femoral artery and subsequent major amputation. Of the remaining 2 requiring surgical intervention, one underwent a direct suture repair whilst the other underwent vessel ligation. 8/12 TA required intervention (**Table 3**), with 7 undergoing surgical intervention and one endovascular stenting. Five underwent lower limb arterial bypass, 1 underwent attempt at lower limb bypass but was abandoned due to no suitable conduit and poor run off vessel whilst the popliteal TA presenting with acute ischaemia underwent transfemoral amputation. All 3 mycotic aneurysms required intervention, two lower limb arterial bypass reconstructions, one of which occluded resulting in a major lower limb amputation, whilst the third underwent endovascular stenting only to later require vessel ligation.

Of the 12 patients with symptomatic true aneurysms, 7 had concomitant incidental aneurysms, as shown in **Table 4**.

Mortality

30-day mortality was 5.1% (n=2), with one patient presenting with a painful popliteal true aneurysm and chest sepsis who was previously turned down for abdominal aortic aneurysm (AAA 78mm in diameter) repair, who was deemed too frail for intervention (either limb salvage or major amputation), whilst the second patient died of

Table 1: Patient Characteristics.

	Pseudoaneurysms N=24	True Aneurysms N=12	Mycotic Aneurysms N=3
Male	12 (50%)	12 (100%)	3 (100%)
Median Age, yrs	45	76	55
Side			
Right	15 (62.5%)	6 (50%)	2 (66.7%)
Left	9 (37.5%)	6 (50%)	1 (33.3%)
Intervention	22 (91.7%)	8 (66.7%)	3 (100%)
Amputation	2 (8.3%)	1 (8.3%)	1 (33.3%)
30 day mortality	1 (4%)	1 (17%)	0

Table 3: Intervention by aneurysm type.

	Site	Intervention							
		Surgical	Conservative	Endovascular stent	US Guided Thrombin Injection	US Guided Compression	Embolisation	Combined Surgery + endovascular	Palliative
Pseudo aneurysm		12	2	4	1	4	1	0	0
True Aneurysm		7	2	1	0	0	0	0	2
Mycotic Aneurysm		2	0	0	0	0	0	1	0

Table 4: Synchronous aneurysms.

Symptomatic Aneurysm	Incidental Aneurysm
Popliteal	Contra lateral Popliteal Abdominal Aortic Aneurysm
Popliteal	Contra lateral Popliteal Abdominal Aortic Aneurysm
Popliteal	Contra lateral Superficial Femoral
Popliteal	Contra lateral Popliteal Bilateral Common Femoral
Popliteal	Contra lateral Popliteal Abdominal Aortic Aneurysm
Popliteal	Abdominal Aortic Aneurysm
Popliteal	Abdominal Aortic Aneurysm

sepsis in the peri-operative period following ligation of an infected femoral PA.

Discussion

Infra inguinal aneurysms constitute over 90% of non-aortic aneurysms [9]. In recent years, the increases in catheterization procedures and vascular surgical interventions have been important factors in the higher prevalence of pseudoaneurysms. Patients may present with either symptoms of extremity ischaemia secondary to thrombosis and embolism or symptoms related to infection or compression of neighboring veins and nerves. Aetiology plays a vital role both in presentation and management of infra-inguinal aneurysms. PAs in intravenous drug abusers almost always present with infection needing ligation of the affected blood vessel(s). All 10 patients with infected PAs in our study required vessel ligation, whilst infection is uncommon in iatrogenic PAs allowing primary repair. True aneurysms, on the other hand, usually present with either acute or acute on chronic ischaemia and rarely rupture.

In our study more than 90% of TAs involved the popliteal arteries, a finding consistent with the literature [10], while more than 90% of PAs involved femoral (common femoral, superficial femoral and profunda femoris) arteries with only two cases involving popliteal and crural arteries.

Popliteal true aneurysms impact more on limb viability than femoral true aneurysms, mainly because of thrombotic/embolic events. Many studies advocate surgery in asymptomatic popliteal aneurysms to prevent future complications [2,11,12]. However, a policy of operating on all asymptomatic infra-inguinal aneurysms is unjustified and potentially dangerous; many of which are asymptomatic and remain so over several years Trickett et al. [13], performed lower limb duplex ultrasonography on 1074 males attending screening or surveillance for abdominal aortic aneurysms. Only 1% of those screened had a popliteal aneurysm, none of which developed a complication (in the five year follow up) related to their asymptomatic popliteal aneurysm [13]. Selective surgical treatment,

based on symptoms, the amount of mural thrombus, the diameter of the aneurysm and the life expectancy of the patient, is likely to produce better results [14]. Other studies have suggested surgical treatment should be provided to all patients with symptomatic popliteal artery aneurysms and asymptomatic aneurysms of more than 2 cm [14]. It should be remembered that the risk of amputation for symptomatic popliteal aneurysms is high (20-69%) [1,9] and that the life expectancy of these patients may be short due to high incidence of comorbid conditions [14]. This is in contrast to asymptomatic true popliteal aneurysms with an incidence of amputation about 4% [9]. In the present study all the popliteal aneurysms were symptomatic and 8 underwent some form of intervention, two were treated conservatively first already had a common femoral-posterior tibial reverse vein bypass graft for a SFA aneurysm and symptoms were managed conservatively as symptoms were deemed due to distal bypass anastomosis. Second patient had a long standing symptomatic presentation and electively surgically explored but procedure abandoned due to absence of native long saphenous veins.

The remaining two patients were deemed not physiologically fit for intervention or limb salvage, and as such were treated palliatively. Of those patients with TAs, 8.3% ultimately required major limb amputation on the same admission. True aneurysms have historically been treated surgically with either exclusion of the aneurysm and subsequent arterial bypass or resection of the aneurysmal segment with an interposition bypass. Open surgical repair with general or regional anaesthesia ay poses a high risk for these patients and as such endoluminal stent grafting has become an alternative to surgical treatment [9,22-24].

With regards to PAs, etiology and presence or absence of infection helps in deciding treatment options. As PAs in IVDAs are almost always infected, ligation of the involved artery has been the treatment of choice. In our study all the infected PAs (10/10 in IVDUs and 1/13 Iatrogenic PA) required ligation of involved arteries, with only one PA requiring vessel ligation secondary to IVDA undergoing an arterial bypass for limb salvage. Ultrasound Guided Compression

(USGC) introduced by Fellmeth et al. [15], is a safe and cost-effective method for achieving pseudoaneurysm thrombosis in the non-infected, non-neurovascular/sin compromised, post iatrogenic injury (ie arterial puncture) [16]. However, USGC has limitations, including a long procedure time and discomfort to patient. It is less likely to be successful in large PAs (larger than 3cm), those with chronic PAs (as they have become endothelialised), those with large diameter neck and those who can't tolerate the associated discomfort [17]. Its success rates can vary, depending on the experience of the practitioner, and have been reported as high as 75% and above [18]. One third of Iatrogenic PAs (4/12) were successfully treated with USGC in our study whilst another one third were successfully treated by covered stent graft. Durability and long-term outcomes of stent grafts are still awaited [19,20]. A recent Cochrane review concluded that Ultrasound Guided Thrombin Injection (USGTI) might be considered as the new 'gold standard' for the treatment of non-infected post percutaneous intervention pseudoaneurysms [21]. In our study one patient was successfully treated by USGTI whilst another was treated with coil embolization.

The incidence of amputation for pseudoaneurysms varies depending on the aetiology and treatment required. The incidence of major lower limb amputation following ligation of infected femoral artery pseudoaneurysms ranges from 11% to 33% [25]. In our study the overall amputation of PAs was 8.3%, with a major lower limb amputation rate of 18.2% (n=2/11) for those patients with an infected PA. Of those patients with an infected PA requiring vessel ligation, only one subsequently underwent arterial reconstruction with autologous vein (reversed long saphenous ilio-femoral bypass, resulting in limb salvage) once the sepsis was adequately controlled. A further patient in this group underwent trans femoral amputation following vessel ligation due to the acute nature of the ischaemia and ongoing sepsis, with amputation being a lifesaving procedure. The majority of studies reporting on infected PAs secondary to IVDA document small patient numbers. Padberg et al. [26], in a study of 18 patients with infected femoral false aneurysms secondary to IVDA, reported on their aggressive use of limb revascularisation due to their concerns about high rates of limb loss when limiting their initial management to vessel ligation and debridement. Twelve of the 18 patients underwent revascularisation in the initial peri-operative period, resulting in 3 amputations and 13 secondary arterial operations in this re-vascularised group, in contrast to no amputations in those patients undergoing vessel ligation with no reconstruction [26]. Both Padberg and Arora et al. [27], advocate a test clamp of the distal external iliac/proximal common femoral and assessing pedal doppler signals. Should a pedal Doppler signal be present upon test clamping they suggest no further need for immediate arterial reconstruction. In contrast to Padberg et al., a study of 16 patients by Patel et al., reported on their use of aggressive revascularisation in such patients, with 15/16 patients undergoing immediate revascularisation upon vessel ligation and debridement, with only one late graft failure, whilst the remaining 14 patients had functional limbs with no claudication or rest pain [28]. Klonaris et al., documented their experience of utilising the internal iliac artery as a patch or conduit for arterial reconstruction in nine patients with infected false aneurysms secondary to IVDA [29], with the internal iliac artery being utilized

as a patch in five patients and an interposition graft in four patients. None of these nine patients suffered perioperative complications nor had signs of infection or required limb amputation over a median of 19 months follow up [29]. A review of treatment options in these patients reported that even immediate revascularisation procedures through non infected tissues, following ligation resulted in early and late graft infection rates of 21% and 32% respectively, with early and late amputation rates of 10% and 11% respectively, with a risk of anastomotic dehiscence of 14% [30]. Even delayed revascularisation resulted in significant morbidity, with long term graft infection and amputation rates of 6% [30].

30-day mortality rate of infra inguinal aneurysms in this study is 5.2% (n=2), which is well below the reported mortality in the literature. The published mortality for infra inguinal aneurysms varies depending on the type and site of aneurysm, with 30-day mortality for all popliteal aneurysms ranging up to 14% [31,32] and 30-day mortality for all femoral pseudoaneurysms quoted at 4% [33].

Conclusion

Our results compared favorably to the few national observational studies. Due to the risk of rupture, extremity ischemia and amputation, infrainguinal aneurysms result in considerable morbidity and mortality. To achieve high success rates in symptomatic and asymptomatic patients we suggest early diagnosis and appropriate treatment.

References

1. Bahcivan M, Keceligil HT, Kolbakir F, Gol MK (2010) Surgical treatment of peripheral artery aneurysms. *Hellenic J Cardiol* 51: 37-41.
2. Wychulis AR, Spittell JA, Wallace RB (1970) Popliteal aneurysms. *Surgery* 68: 942-952.
3. Schellack J, Smith RB, Perdue GD (1987) Nonoperative management of selected popliteal aneurysms. *Arch Surg* 122: 372-375.
4. Dent TL, Lindenauer SM, Ernst CB, Fry WJ (1972) Multiple arteriosclerotic arterial aneurysms. *Arch Surg* 105: 338-344.
5. Dawson I, Sie RB, van Bockel JH (1997) Atherosclerotic popliteal aneurysm. *Br J Surg* 84: 293-299.
6. Graham LM, Zelenock GB, Whitehouse WM Jr, Erlandson EE, Dent TL, et al. (1980) Clinical significance of arteriosclerotic femoral artery aneurysms. *Arch Surg* 115: 502-507.
7. Lardi C, Fracasso T (2012) Spontaneous External Rupture of Femoral Pseudoaneurysm: Fatal Hemorrhage Related to Drug Abuse. *Am J Forensic Med Pathol* 33: 319-321.
8. Whitehouse WM Jr, Wakefield TW, Graham LM, Kazmers A, Zelenock GB, et al. (1983) Limb-threatening potential of arteriosclerotic popliteal artery aneurysms. *Surgery* 93: 694-699.
9. Barry MC, Mackle T, Joyce L, Kelly C, McGrath F, et al. (2003) Endoluminal graft stenting of peripheral aneurysms: questionable results compared with conventional surgery. *Surgeon* 1: 42-44.
10. Mitchell ME CJ (2001) Popliteal Artery Aneurysm. *Current Therapy in Vascular Surgery*: Mosby, Inc: St. Louis, MO.
11. Linton RR (1949) The arteriosclerotic popliteal aneurysm; a report of 14 patients treated by a preliminary lumbar sympathetic ganglionectomy and aneurysmectomy. *Surgery* 26: 41-58.
12. Gilford RW, Hines EA, Janes JM (1953) An analysis and follow-up study of one hundred popliteal aneurysms. *Surgery* 33: 284-293.

13. Trickett JP, Scott RA, Tilney HS (2002) Screening and management of asymptomatic popliteal aneurysms. *J Med Screen* 9: 92-93.
14. Hands LJ, Collin J (1991) Infra-inguinal aneurysms: outcome for patient and limb. *Br J Surg* 78: 996-998.
15. Fellmeth BD, Roberts AC, Bookstein JJ, Freischlag JA, Forsythe JR, et al. (1991) Postangiographic femoral artery injuries: nonsurgical repair with US-guided compression. *Radiology* 178: 671-675.
16. Eisenberg L, Paulson EK, Kliewer MA, Hudson MP, DeLong DM, et al. (1999) Sonographically guided compression repair of pseudoaneurysms: further experience from a single institution. *Am J Roentgenol* 173: 1567-1573.
17. O'Sullivan GJ, Ray SA, Lewis JS, Lopez AJ, Powell BW, et al. (1999) A review of alternative approaches in the management of iatrogenic femoral pseudoaneurysms. *Ann R Coll Surg Engl* 81: 226-234.
18. Kazmers A, Meeker C, Nofz K, Kline R, Groehn H, et al. (1997) Nonoperative therapy for postcatheterization femoral artery pseudoaneurysms. *Am Surg* 63: 199-204.
19. Henry M, Amor M, Henry I, Klonaris C, Tzvetanov K, et al. (2000) Percutaneous endovascular treatment of peripheral aneurysms. *J Cardiovasc Surg (Torino)* 41: 871-883.
20. van Sambeek MR, Gussenhoven EJ, van der Lugt A, Honkoop J, du Bois NA, et al. (1999) Endovascular stent-grafts for aneurysms of the femoral and popliteal arteries. *Ann Vasc Surg* 13: 247-253.
21. Tisi PV, Callam MJ (2009) Treatment for femoral pseudoaneurysms. *Cochrane Database Syst Rev* CD004981.
22. Joyce WP, McGrath F, Leahy AL, Bouchier-Hayes D (1995) A safe combined surgical/radiological approach to endoluminal graft stenting of a popliteal aneurysm. *Eur J Vasc Endovasc Surg* 10: 489-491.
23. Marin ML, Veith FJ, Panetta TF, Cynamon J, Bakal CW, et al. (1994) Transfemoral endoluminal stented graft repair of a popliteal artery aneurysm. *J Vasc Surg* 19: 754-757.
24. Sapoval MR, Long AL, Raynaud AC, Beyssen BM, Fiessinger JN, et al. (1992) Femoropopliteal stent placement: long-term results. *Radiology* 184: 833-839.
25. Reddy DJ, Smith RF, Elliott JP, Haddad GK, Wanek EA (1986) Infected femoral artery false aneurysms in drug addicts: evolution of selective vascular reconstruction. *J Vasc Surg* 3: 718-724.
26. Padberg F Jr, Hobson R 2nd, Lee B, Anderson R, Manno J, et al. (1992) Femoral pseudoaneurysm from drugs of abuse: ligation or reconstruction? *J Vasc Surg* 15: 642-648.
27. Arora S, Weber MA, Fox CJ, Neville R, Lidor A, et al. (2001) Common femoral artery ligation and local debridement: a safe treatment for infected femoral artery pseudoaneurysms. *J Vasc Surg* 33: 990-993.
28. Patel KR, Semel L, Clauss RH (1988) Routine revascularization with resection of infection femoral pseudoaneurysms from substance abuse. *J Vasc Surg* 8: 321-328.
29. Klonaris C, Katsargyris A, Papapetrou A, Vourliotakis G, Tsiodras S, et al. (2007) Infected femoral artery pseudoaneurysm in drug addicts: the beneficial use of the internal iliac artery for arterial reconstruction. *J Vasc Surg* 45: 498-504.
30. Georgiadis GS, Lazarides MK, Polychronidis A, Simopoulos C (2005) Surgical treatment of femoral artery infected false aneurysms in drug abusers. *ANZ J Surg* 75: 1005-1010.
31. Robinson WP, Belkin M (2009) Acute limb ischemia due to popliteal artery aneurysm: a continuing surgical challenge. *Semin Vasc Surg* 22: 17-24.
32. Mahmood A, Salaman R, Sintler M, Smith SR, Simms MH, et al. (2003) Surgery of popliteal artery aneurysms: a 12-year experience. *J Vasc Surg* 37: 586-593.
33. Moini M, Rasouli MR, Rayatzadeh H, Sheikholeslami G (2008) Management of femoral artery pseudo-aneurysms in Iran: a single centre report of 50 cases. *Acta Chir Belg* 108: 226-230.

Copyright: © 2016 Moussa O, et al. This is an open-access article distributed under the terms of the Creative Commons Attribution License, which permits unrestricted use, distribution, and reproduction in any medium, provided the original author and source are credited.

Citation: Moussa O, Mittapalli D, Suttie SA (2016) Infra-Inguinal Aneurysms – Threat to Life and Limb? *Int J Vasc Surg Med*. 2: 001-005. DOI: 10.17352/2455-5452.000007