

Sava Durkovic¹ and Paolo Scanagatta^{2*}¹University of Milan, School of Medicine, School of General Thoracic Surgery, Milan, Italy²Division of Thoracic Surgery, Fondazione IRCCS Istituto Nazionale dei Tumori, Milan, Italy**Dates:** Received: 20 August, 2015; Accepted: 08 September, 2015; Published: 10 September, 2015

*Corresponding author: Paolo Scanagatta, MD, Fondazione IRCCS Istituto Nazionale dei Tumori, S.C. Chirurgia Toracica Via G.Venezian 1, 20133 Milano, Italy, Tel: +39 (0)2 2390 2384; Fax: +39 (0)2 2390 2907; E-mail: paolo.scanagatta@istitutotumori.mi.it

www.peertechz.com

ISSN: 2454-2968

Keywords: Muscle-sparing thoracotomy; Classification; Review

Research Article

Muscle-Sparing Thoracotomy: A Systematic Literature Review and the “AVE” Classification

Abstract

Background: To synthesize the concept of muscle-sparing thoracotomies for major pulmonary resections and to explore the relationship between Kraissl's lines and skin incisions perpendicular to them.

Methods: Systematic literature review was performed of MEDLINE database. Articles were selected if they described adult patients undergoing major pulmonary resection by way of a well-described thoracotomy that neither partially nor completely transects outer thoracic muscles, and that is independent of endoscopic instruments, and video technology. Median sternotomy was excluded.

Results and Discussion: On the basis of analysis of 45 articles we propose an anatomical classification of muscle-sparing thoracotomies considering the way in which the muscles are spared. Classification distinguishes five types of muscle-sparing thoracotomies which are represented originally using cylindrical projection of thorax. Type I is realized by enlarging auscultatory triangle, Type II by splitting of latissimus dorsi muscle fibers beneath the bifurcation of thoracodorsal nerve and artery, Type III by retracting latissimus muscle posteriorly and serratus anterior muscle anteriorly, Type IV by separating digitations of serratus anterior muscle in front of the long thoracic nerve, and Type V by disinserting serratus anterior muscle in its medial part. The significance of Kraissl's lines remains unknown.

Conclusions: Proposed classification is original and might have a didactic role. It facilitates evidence-based approach to comparative studies. Thoracic maps are a useful way to express this concept.

Introduction

The issue of operative “open” accesses to the thorax remains complex, even if we limit ourselves to major pulmonary resections (segmentectomy, lobectomy and pneumonectomy or more than two non-anatomical sublobar resections). The variable of interest within this health care intervention that is in focus of this article is the operative approach. Selecting the best one among many alternatives may be important for the patient, surgeon and health-policy makers. Systematic literature review on the subject of muscle-sparing thoracotomies is lacking.

The term “thorax” has Grecian origin and it refers to ancient Grecian armour [1] used as a protection that consisted of two bronze sheets, one for the protection of the breast and abdomen, the other for the back [2].

Gerardus Mercator (1512-1594) was a Flemish cartographer [3]. He is remembered for the first cylindrical world map projection which is named after him. It was presented in 1569. He named it *Nova et Aucta Orbis Terrae Descriptio ad Usus Navigatium Emendate*: “new and augmented description of Earth corrected for the use of navigation”. His idea was to help navigation by sea [4]. Furthermore Mercator was the first in the world to use the word “Atlas” to describe a collection of maps [4].

Each projection is an attempt to fit a curved surface onto a flat

sheet, so that some distortion of the true layout of the projected surface is inevitable [4]. Thoracic cartography might mean fitting thorax onto a flat surface by way of a cylindrical projection. It shares some common features with that of Mercator: it is meant to help “navigation” through thoracotomies, and it is the first one of its kind.

Mercator-like projection of the human body covered by the “ancient” thorax at the cutaneous level is presented on [Figure 1](#). Base of the neck is added in an orthographical manner for clarity. The “Greenwich” is on the anterior median line. Instead of meridians and parallels, concentric circles that correspond to lines of skin tension or Kraissl's lines are drawn [5]. Unlike Langer's lines which are determined on cadavers during rigor mortis, these lines are determined on living persons and are essentially perpendicular to the direction of the underlying muscle fibers which are easy to follow on [Figure 2](#). Secondary endpoint of this research will be to explore the relationship between these lines and skin incisions perpendicular to them.

Thoracic maps and human body throughout this text should be placed in the same context as planet earth and world map. They are intended to act as carriers of the results of systematic literature review. Regarding [Figure 1](#) it is essential to notice that the thoracic wall is divided conventionally by anterior and posterior axillary folds in anterior, lateral, and posterior walls. Furthermore, the lower margin

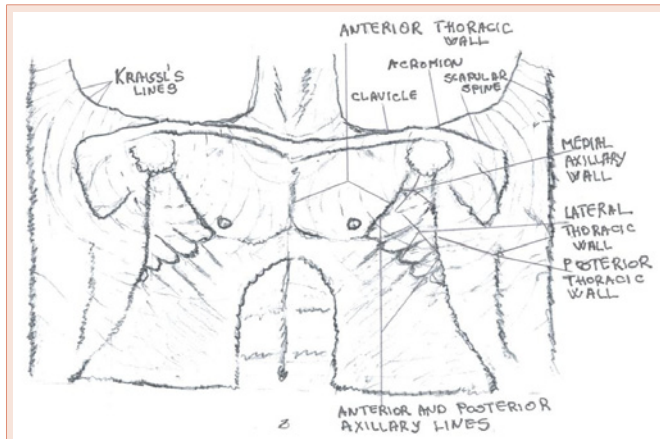


Figure 1: Mercator-like sketch projection of the human body (I). Anatomy.

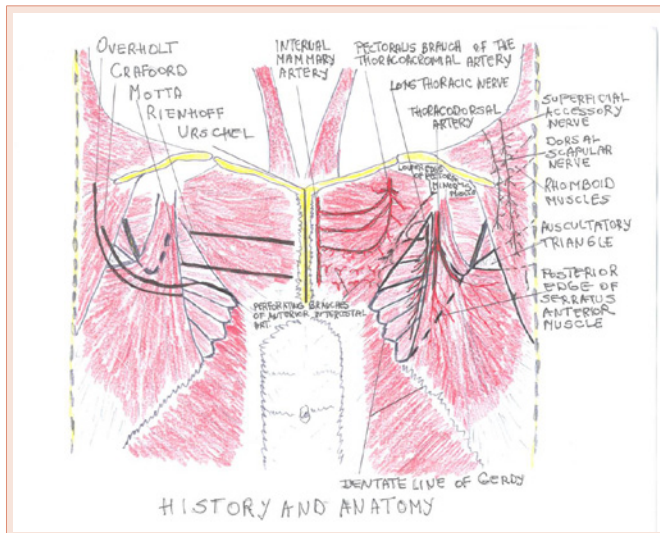


Figure 2: Mercator-like sketch projection of the human body (II). Thoracotomy: history and anatomy.

of medial axillary wall corresponds to the lower margin of the 4th rib. Thus, medial axillary wall makes upper part of lateral thoracic wall.

- It is well known that the variable, operative approach for major pulmonary resections may take many forms:
- posterior thoracotomy done in prone decubitus described by Overholt [6] in 1934;
- posterolateral described by Crafoord [7] in 1938 done in lateral decubitus;
- anterolateral done in anterior-oblique decubitus described by Archibald [8] already in 1934 for left pneumonectomy only, and many years later, in 1983 by Motta [9] for all types of major pulmonary resections;
- anterior thoracotomy done in supine decubitus described by Rienhoff [10] in 1936;

- median sternotomy described by Urschel [11] in 1986;
- muscle-sparing alternatives which were reported already in the sixties as will be explained later, and
- Minimally invasive incisions that appeared in the nineties.

These variables should be explicitly defined in order to make comparisons between them meaningful.

Thoracic map that summarizes thoracic incisions for major pulmonary resections that do not spare extra thoracic muscles [6-10] is sketched on the left side of Figure 2. Skin incisions for this group are equivalent to the extent of muscle transection presented and their names conform perfectly to previously mentioned posterior, lateral, and anterior thoracic walls. Their names also reflect prevailing approach to the hilus and patient's decubitus which altogether implicates their respective advantages and disadvantages. As for median sternotomy, we identified at least one center where it is still a dominant approach for all types of major pulmonary resections with exception of left lower lobectomy [12].

Two events changed significantly the choice of surgical access. Double-lumen endotracheal tubes were introduced in the early fifties [13]. As lateral decubitus became safe posterolateral thoracotomy prevailed as it permits "all-around" approach to the hilus. Alternative approaches had to prove their superiority with respect to posterolateral thoracotomy. Another event was introduction of mechanical suture [14], which occurred also in the fifties on the eastern side of the "iron curtain". These two events set the stage for the appearance of alternative incisions.

Pertinent anatomy to realize the concept of muscle-sparing is presented on the right half of the Figure 2 which is a sketched cylindrical projection of thorax at the muscular level. Neurovascular anatomy of pectoralis major, serratus anterior and latissimus dorsi muscle was drawn according to the results of anatomic studies done for use in plastic surgery [15-17].

Materials and Methods

A systematic literature review was performed using PUBMED MEDLINE database (as of 20th May 2010; key words (t= thoracotomy): muscle sparing t., vertical t., axillary t., lateral t., posterior t., auscultatory triangle t., anterior t., anterolateral t., posterolateral t.). In order to facilitate literature retrieval a PICOS framework was used, and the steps taken in the course of analysis were summarized in an algorithm (Figure 3). Inclusion criteria considered adult patients who underwent major pulmonary resections (defined as anatomical resections –segmentectomy, lobectomy or pneumonectomy- or more than two non-anatomical sublobar resections) by way of well-described thoracic incisions that neither partially nor completely transect outer thoracic muscles. Median sternotomy and previous reviews were excluded. To isolate this variable from the impact of endoscopic instruments and video assisted thoracoscopy (VATS) such studies were excluded. Outcome of interest was adequacy of such an incision to perform successfully major pulmonary resections.

First authors will be cited throughout review, country of origin and year of publication will be cited for those authors who first established

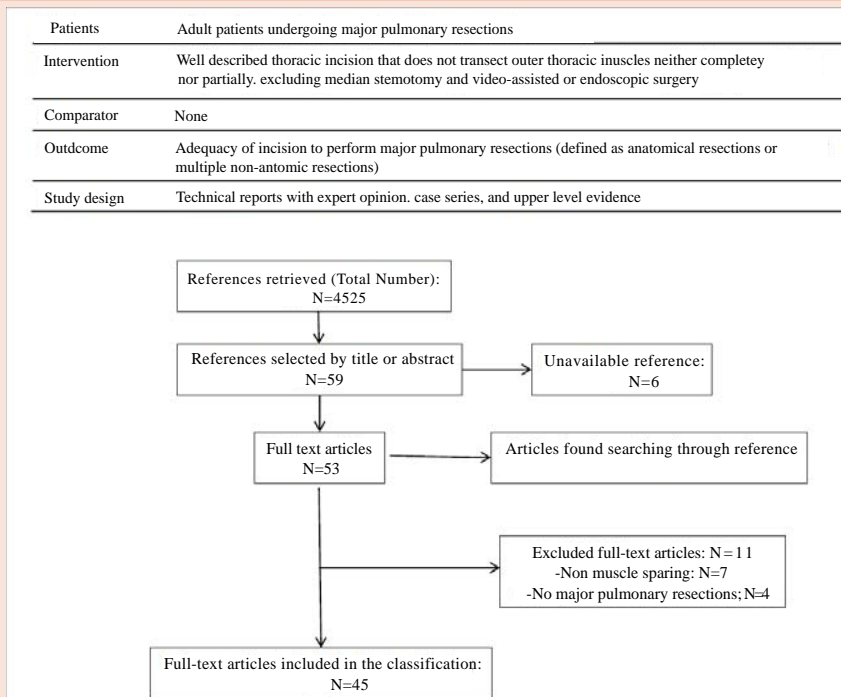


Figure 3: The flowchart for the systematic review of MEDLINE database demonstrates PICOS criteria for selecting articles (above) as well as the number of articles identified at each step (below).

the adequacy of respective type of muscle-sparing thoracotomies. We will present in tables comparative studies between posterolateral and any type of muscle-sparing thoracotomies.

Results

After systematic review, the 45 selected articles were analyzed and grouped considering the way in which the muscles were spared, thus identifying an anatomical classification of muscle-sparing thoracotomies. It distinguishes five types of muscle-sparing thoracotomies designated by Roman numbers, arranged on thoracic maps navigating from auscultatory triangle toward the sternum. Results are summarized in Table 1 and two maps (Figures 4,5). Table 1 is modified according to Oxford Centre for Evidence-based Medicine [18] to present body of evidence supporting each respective type of muscle-sparing thoracotomy. Figure 4 is a sketch which represents compilation of skin incisions. Skin incisions perpendicular to Kraissl’s lines, many of them referred to as “vertical”, are grouped on the right side of the same Figure, and as such they are ideal to study their significance. Figure 5 is an ideal representation of muscle-sparing concept. Skin incisions depicted in Figure 4 with their appropriate type designation proceed on Figure 5 through the same number.

Clinical observations with advantages and disadvantages are reported for each type from Level 4 and 5 studies (Table 1).

Type I

The first muscle-sparing thoracotomy described as adequate for major pulmonary resections and to have supplanted posterolateral

thoracotomy was that of American surgeon Karwande [19] in 1989. Briefly, lateral or semi-prone decubitus, appropriate posterolateral skin incision, skin flaps raised, exposure of bony thorax is through the auscultatory triangle which may be further enlarged by incising aponeurosis of latissimus dorsi muscle. Access to the pleural cavity is through 5th intercostal space. Horowitz [20] and Ashour [21] belong to this group.

Advantages: Shoulder function better, indicated for patients dependent on maximal arm function.

Disadvantages: Difficult exposure for obese or heavily muscled.

Type II

French surgeon Bellamy [22] was the first to have described incision of this type in 1993. Lateral decubitus. Skin incision is placed parallel to the fibers of latissimus dorsi muscle beneath the bifurcation of thoracodorsal nerve and artery. Access to the bony thorax is obtained after incision of fascia along the inferior border of rhomboid major and anterior serratus muscle. Access to the pleural cavity is through 5th intercostal space. Sadighi [23] and Subrammanian [24] described this type through posterolateral skin incision with raising skin flaps.

Advantages: Less pain, quickly opened, easier to open, better cosmesis, and shoulder function.

Disadvantages: Not for voluminous tumors.

Type III

American surgeon Bethencourt [25] reported this technique in

Table 1: Levels of evidence of studies supporting different types of muscle-sparing thoracotomy (as categorized in the text) according to Oxford Centre for Evidence-based Medicine (page last edited 15 April 2011).

Grades of recommendation	Level	Therapy/Major Pulmonary Resection by way of a muscle sparing thoracotomy	Type I	Type II	Type III	Type IV	Type V
A	1a	SR (with homogeneity) of RCTs					
	1b	Individual RCT (with narrow confidence interval)					
	1c	All or nones			26, 31*-37		
B	2a	SR (with homogeneity) of cohort studies					
	2b	Individual cohort study (including low quality RCTs)					
	2c	"Outcomes" research; Ecological studies					
	3a	SR (with homogeneity) of case-control studies			28,29,30	53,58	63
	3b	Individual case-control study					
C	4	Case series (and poor quality cohort and case-control studies)	19,21	22	38,42	43,44,46,47,51,52, 55-57	60-62
D	5	Expert opinion without explicit critical appraisal, or based on physiology, bench research or "first principles"	20	23,24	25,27, 39-41	45,48-50, 54	59

SR systematic review ; RCT randomized controlled trial.

* reference 31 is a RCT comparing lobectomy done by Type III thoracotomy vs. VATS.

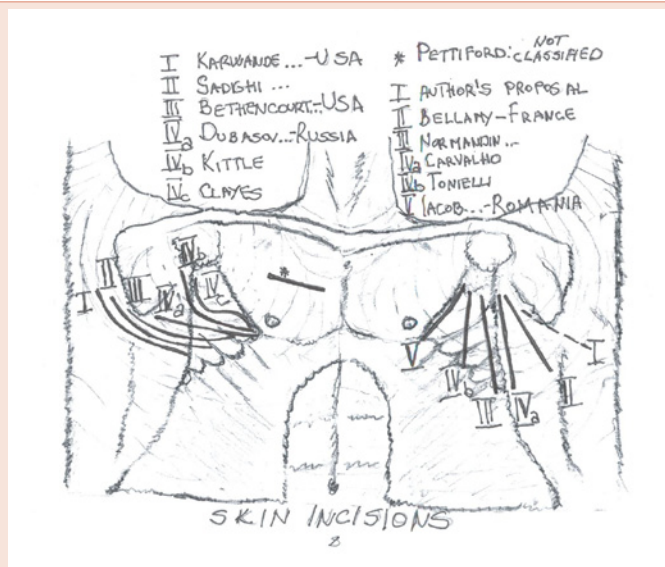


Figure 4: Mercator-like sketch projection of the human body (III). Skin incisions for muscle-sparing thoracotomies.

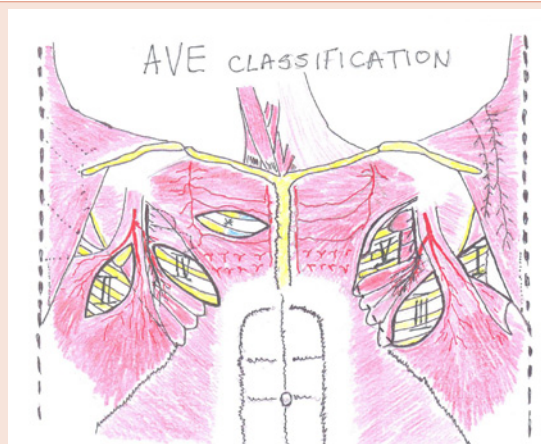

Figure 5: Mercator-like sketch projection of the human body (IV). Five types of muscle-sparing thoracotomies.

1988. Lateral decubitus, appropriate posterolateral skin incision, large skin flaps are raised, latissimus dorsi retracted posteriorly and anterior serratus anteriorly. Inferior insertions of serratus anterior muscle may sometimes be divided for a variable distance to obtain adequate exposure (broken line on the right half of Figure 5). Intercostal incision is usually through 5th intercostal space. Hazelrigg [26], Ponn [27], Landreneau [28-30], Kirby [31], Sugi [32], Kutlu [33], Akcali [34,35], and Athanassiadi [36] used this incision without modifications. Lemmer [37] described a modification of the skin incision in order to decrease the extent of subcutaneous dissection. He used curvilinear incision that started in the midaxillary line several centimetres below the hairline that curved anteriorly at the nipple level to extend below the breast.

The following authors described using a vertical skin incision along the anterior border of latissimus dorsi muscle without raising skin flaps: Normandin [38], Ginsberg [39], Van Raemdonck [40], Hennington [41], and Kim [42].

Advantages: Less pain, better shoulder function, better cosmesis.

Disadvantages: More time to open, difficult exposure for muscular patients, difficult exposure through the 4th intercostal space, seromas.

All authors in this group [25-42] noted occasional need to divide lower attachments of serratus anterior muscle to obtain adequate exposure (broken line on Figure 5). Among these 17 references there are six randomized controlled trials of Type III vs. posterolateral thoracotomy. They are reported in Table 2.

Prospective cohort study done by Landreneau is presented in Table 3.

Type IV

Russian surgeon Dubasov [43] reported the adequacy of this type of incision in 1966 with an update two years later [44]. Lateral decubitus. The upper arm is abducted to open up the axilla, operative Table is rotated 20-25 degrees posteriorly, and skin incision is lateral, parallel with the 5th intercostal space.

Small skin flaps are raised. Latissimus dorsi muscle is retracted posteriorly after mobilization of its anterior border, digitations of serratus muscle are separated in front of the long thoracic nerve and thus access to the bony thorax obtained. This principle allows major pulmonary resections to be performed from 3rd-6th intercostal space. The most versatile form is through the 5th intercostal space. Noirclerc et al. [45] reported that their group had seen this incision in Russia, but they left no citations. What has been known for decades as “French” incision in fact is “Russian”. The following authors reported excellent experience with this incision: Tsybyrne [46], Ganul [47], Massimiano [48], Fry [49], Mitchell [50,51], Richelme [52], and Giudicelli [53].

The following three authors described a modification of skin incision with skin flaps raising. Kittle [54] uses a skin incision that starts in the submammary crease and then curves along the posterior axillary line toward axilla. Tonielli [55] described vertical skin incision placed in the middle axillary line, and Clayes [56] used a Latin”S”-like lateral skin incision.

Carvalho [57] reported a modification of skin incision that avoids subcutaneous dissection. The elbow of the upper arm is placed in

Table 2: Randomized controlled trials comparing Type III thoracotomy and posterolateralThoracotomy. PLT = posterolateral thoracotomy; NR =not reported.

Study (First author, year)	Patients	Outcomes	Results	Comment
Lemmer [37]	Type III: 13 PLT: 15	Early postoperative pulmonary function, early postoperative pain, complications	FEV1 and FVC at 24 h favor Type III group. No difference in pain and complications rate.	53% of patients underwent lobectomy. 8 in Type III and 7 in PLT group; randomization method NR
Hazelrigg [26]	Type III: 26 PLT:24	Early postoperative pain, pulmonary function, shoulder strength and range of motion	Pulmonary function equal, less pain in Type III(p=0.01), shoulder strength better early, identical after one month, complications equal, seroma prevalence 23%	66% of pts underwent major resections, randomization method NR
Sugi [32]	Type III: 15 PLT: 15	Pulmonary function after one month, operative field size, number of lymphnodes, pain, shoulder function	Smaller operative field for B&H, less pain and better shoulder function, lymph nodes equal, pulmonary function equal, approach time longer	All patients were clinical stage I and II NSCLC and underwent lobectomy with lymphadenectomy, randomization method NR
Kutlu [33]	Type III: 10 PLT: 10	Shoulder girdle strength measured preoperatively and 3 months postoperatively	Shoulder girdle strength significantly better in Type III group 3 months after thoracotomy	60% of patients underwent lung resection, no data about the type, randomization done according to hospital numbers
Akcali [35]	Type III: 30 PLT: 30	Approach time, early pain, pulmonary function, shoulder function	No difference in approach time, pulmonary function, shoulder range of motion, muscle strength after one month and complication-rate. Less pain in Type III group.	25 % of patients underwent major resections, 8 in PLT and 7 in B&H group, randomization method NR
Athanassiadi [36]	Type III: 50 PLT: 50	postoperative pain, postoperative pulmonary function, shoulder function up to two months postoperatively	No difference	74% of patients underwent lobectomy, 38 in PLT group and 36 in Type III group, randomization method NR

Table 3: Prospective cohort studies comparing Types III - IV - V vs. posterolateral thoracotomy. PLT = posterolateral thoracotomy ; MST = muscle-sparing thoracotomy; ICS = intercostal space.

Study (First author, year)	Patients	Outcomes	Results	Comment
Landreneau [30]	Type III and IV: 148 PLT: 187	Early clinical Outcomes, functional status one year after surgery	No differences, the only advantage is availability of muscle flaps	All patients underwent lobectomy for clinical stage I lung carcinoma. Patients in the MST arm underwent either Type III through the 5 ^o or Type IV incision through the third ICS
Yamaguchi [58],	Type IV: 17 PLT: 27	Postoperative pain, length of hospitalization	Less pain and shorter postoperative stay in Type IV group	73% of patients underwent lobectomy, 18 in the PLT group and 17 in Type IV group
Ochroch [63]	Type V: 82 PLT: 38	Early and long-term pain, and Long term pulmonary function, up to 48 weeks after thoracotomy	No difference when epidural analgesia is used	Patients underwent lobectomies, bilobectomies and segmentectomies and were randomized according to timing of epidural analgesia, not with respect to surgical incision

maximal flexion and the upper arm is flexed anteriorly for about 30 degrees to decrease the distance between insertions of the latissimus dorsi muscle in order to facilitate its retraction. The skin incision is placed parallel to and 1cm posterior to the anterior margin of the latissimus dorsi muscle. Its anterior margin is mobilized and the access obtained to serratus anterior muscle which is then treated as for Type IV.

Yamaguchi [58] reported a modification of intercostal incision creating “French window” by cutting the ribs at the costochondral junction anteriorly and at the level of posterior scapular line posteriorly to avoid rib spreading. Results of this comparative study are reported in Table 3.

Advantages: Better cosmesis, better shoulder function immediately upon awakening from anesthesia.

Disadvantages: Authors do not report limitations in performing major pulmonary resections.

Type V

Naef [59] from Switzerland reported in 1958 that he had performed some lobectomies through this incision, but cautioned about limited exposure. French surgeon Mathey [60] reported this technique in 1961, but it was used for upper lobectomies only. Romanian surgeon Jacob [61] reported in 1962 experience with this incision using it for all types of lobectomies. He started using it in 1952 and as of 1962 it became exclusive incision in his practice. According to this research this is the oldest technique that had supplanted completely any form of non muscle-sparing thoracotomy. Lateral or supine decubitus may be used. The skin incision is vertical (retropectoral), placed in the anterior axillary line, occasionally may be extended anteriorly in the sub mammary crease, serratus anterior muscle is disinserted from the ribs 2-4, and folded back. Pectoralis major is retracted anteriorly and serratus muscle posteriorly thus accessing the bony thorax.

Intercostal incision is usually performed through 4th, sometimes 3rd, but never 5th intercostal space. At the end of the operation serratus anterior muscle is resutured to the pectoralis minor muscle. Hayward [62], and Ochroch [63] reported good experience with this incision. The former disinserts serratus anterior muscle from the ribs 3-6, and the latter from the fourth and fifth rib only. The only

comparative study in this group [63] is reported in Table 3.

It is clear from the Figure 4 that vertical incisions are in fact perpendicular to Kraissl’s lines and that they converge toward axilla. None of the authors using such skin incisions reported unsightly scars or other problems [22,38-42,55,57,59-63].

Discussion

The first comment is about the graphics we have decided to use throughout this article.

For the purposes of this article they were arranged to express synthetically the concept of muscle-sparing thoracotomies and their consequential classification, but thoracic maps could also be used to carry out an international survey, and in a short period of time surgical behavior of thoracic community could be mapped, representing the smallest, but the most comprehensive “atlas” of muscle-sparing thoracotomies.

The proposed classification has been thought to eliminate confusion from various terms, to be simple and, possibly, to be an useful didactic basis for non-exclusive general thoracic surgeons (i.e. prevalent cardiac, pediatric, or general surgeons). A collateral effect of Figure 2 or Figure 5 may be a nice perspective of various muscle flaps used in thoracic surgery. The very first application of the proposed classification might be as follows: Type III incision has been studied in 6 randomized controlled studies vs. posterolateral thoracotomy. These have never been systematically reviewed to produce level 1a evidence. Looking at Table 2 it is obvious that the numbers of patients are small, patient populations heterogeneous, outcomes as well as tools to measure them different, randomization methods reported for one study only. It seems very hard to synthesize these trials. Results for type III thoracotomy, may not be applicable to other types of muscle-sparing thoracotomies. As for Table 3, patients in the muscle-sparing arm of Landreneau’s study were composed of Type III and Type IV patients and analyzed together further complicating our judgment. The “French window” thoracotomy presented in Table 3 brings an important modification of intercostal incision such that it seems logical to analyze it as a separate entity. Two incisions were different at both muscle and intercostal level. And finally comparative study between Type V and posterolateral thoracotomy randomized patients with respect to timing of epidural thoracic analgesia. As this

pain treatment modality is so efficacious little can be deduced about other differences between the two approaches.

We feel that in its entirety the issue of thoracotomies may be an extremely fertile soil for a host of confounding variables from the skin incision to its closure. What we really need are higher level, carefully planned and adequately powered studies.

We propose the name “AVE”, deriving it from the view of the thoracic map at the muscular level. The letter “A” is formed by the lateral margin of the trapezius muscle, posteroinferior margin of rhomboid major and serratus anterior muscle, and superior margin of latissimus dorsi muscle where it forms the auscultatory triangle. The letter “V” comes from posteroinferior margin of anterior serratus and anterior margin of latissimus dorsi muscle. The letter “E” comes from long thoracic nerve and digitations of this muscle originating from the 3-5th rib.

Moreover, there is some hidden message in the name that we have chosen for this classification, which is not only a mnemonic or an ancient Roman salute. It refers mostly to the Types I, III, and IV thoracotomy (Figure 5).

The letter “A” (Type I) contains a triangle and implicates that an already existing anatomical structure should only be enlarged. The letter “E” (Type IV) similarly implicates that digitations of serratus anterior muscle should be simply separated and that this principle functions well on several intercostal levels. This is not the case with the letter “V” (Type III). In the course of this type of thoracotomy muscles are retracted so that the legs of the “V” must first change their places and then further be retracted to permit access to the bony chest. As we have already seen all authors using this technique reported occasional division of distal part of serratus anterior muscle, a feature that makes it a little bit problematic. Yet, this Type has been most extensively studied.

An interesting question for those who teach might be: “How many of these techniques should be in the armamentarium of an average thoracic surgeon and how a lecture on the subject should be best organized?”

All types of muscle-sparing thoracotomies have been described to be feasible through skin incisions called “vertical”, except type I. On the basis of this pure theoretical analysis and following the same logic it seems that such a modification of Type I thoracotomy would be feasible as well, and is represented on the map by a broken line on Figure 4 on the right. The skin incision should follow the upper margin of latissimus dorsi muscle. The dissection should be continued through the auscultatory triangle and under the muscles. The authors of this text feel that validating such an approach would not have any significant impact. Vertical skin incisions except that of Tonielli [55] avoid raising skin flaps and thus are elegant ways to “eradicate” seromas.

Looking at the neurovascular anatomy of the pectoralis major muscle on the map it is clear to what extent and where to split muscle fibers to meet criteria of muscle-sparing concept. Pettiford [64] described such a thoracotomy for upper (sleeve) lobectomies and pneumonectomies that demands the assistance of endoscopic

instruments through a separate port. Although not classified as Type VI because of this assistance it deserves to be placed on the map as it is continuation of this philosophical concept and maybe the last peace in the puzzle (Figure 5). Skin incision for this anterior minithoracotomy is also perpendicular to Kraissl’s lines (Figure 4), even if it could be modified easily into an incision running parallel to Kraissl’s line, loosing neither its safety nor feasibility.

At the dawn of minimally invasive thoracic surgery muscle-sparing concept had almost finished its development. It is a legacy whose principles this new concept embraced. An interested reader will easily find out that the impact of video assistance, with spreading of and progressive development of various endoscopic instruments was substantial even in this “open surgery” field.

For example, skin incisions became shorter, skin flaps raising unnecessary, muscle-sparing was retained, muscle dissection became of lesser extent, intercostal incision became shorter, rib spreading reduced or totally avoided. The next step should be a systematic literature review of surgical “hybrid” techniques that are dependent on video technology and/or endoscopic instruments including robotics. Once this is done, systematic review of comparative studies between various incisions should be carried out to explore the body of evidence supporting each discrete form of this extensive variable. Choosing the best incision is important step in the health care process. It should be done using the principles of Evidence-based medicine (EBM).

Each well-defined form of this variable should have its own EBM box.

The ongoing discussion about VATS major lung resections vs. open surgery could be resolved with a large, adequately powered multi-institutional randomized controlled trial. The question might be: “Which incisions should be used in respective arms, and on what grounds should such a decision be made?”

Gopaldas et al. [65] reported in their retrospective comparative study using 2004 and 2006 Nationwide Inpatient Sample database that in a cohort of 13,619 patients about 5.6% of all lobectomies in the USA were performed using VATS. The term “open surgery” was used for the rest of 94.4% lobectomies. When and how the “open group” became homogeneous? Invasiveness of surgical incision seems to be a continuous variable.

We are always trying to use VATS starting major pulmonary surgery, but when it is justified? Does something like “maximally or intermediate invasive surgery” exist? Where should we place cut-off values for surgical invasiveness? What is the impact of Type IV thoracotomy in this field?

These numbers justify the timing of this classification.

Could you say: “Video killed the radio star?” [66] Not yet.

Finally, synthesis of the left half of Figure 2, Figure 5 produces a tentative definition of muscle-sparing concept: “Muscle-sparing thoracotomy is a common name for a group of thoracic incisions alternative to historically preceding posterior, posterolateral, anterolateral, and anterior thoracotomy that avoid transection of outer thoracic muscles”.

As authors' choice, we prefer type IV muscle-sparing thoracotomy.

Conclusion

The proposed classification could have a didactic role. It could facilitate communication between surgeons, support an Evidence-based approach to comparative studies, and be the basis of an international survey on the subject. Variables will certainly remain extensive with numerous pros and cons, but a well categorized and systematized concept of muscle-sparing is an option to have in mind.

Acknowledgements

We acknowledge Dr Ugo Pastorino for making this research possible, Dr Slobodan Djuric and Dr. Massimo Francese for technical support; Dr Roberto Bellini for supplying us with French surgical literature, Dr Igor Koncar for retrieving articles from Belgium, and Bojana Lazarevic for retrieving articles from Russia.

References

- Zimmel J, Girard T (2015) Hoplite Arms and Armor.
- Lahans M (2015) Ancient Greek Armour, Shields and Helmets.
- (2015) Gerardus Mercator. Source: Wikipedia.
- (2015) Mercator projection. Source: Wikipedia.
- Wilhelmi BJ, Blackwell SJ, Phillips LG (1999) Langer's lines: to use or not to use. *Plast Reconstr Surg* 104: 208-214.
- Overholt RH (1934) The total removal of the right lung for carcinoma. *J Thorac Surg* 4: 196-210.
- Crafoord C (1938) On the technique of pneumonectomy in man: a critical survey of the experimental and clinical development and a report of the author's material and technique. *Acta Chir Scan Suppl* 81: 1-142.
- Archibald E (1934) The technic of total unilateral pneumonectomy. *Ann Surg* 100: 796-811.
- Motta G, Ratto GB, Sacco A (1983) The use of anterolateral thoracotomy in pulmonary exeresis. *Min Chir* 38: 1255-1262.
- Rienhoff WF Jr (1936) The surgical technique of total pneumonectomy. *Arch Surg* 32: 218- 231.
- Urschel HC, Razzuk MA (1986) Median sternotomy as a standard approach for pulmonary. resection. *Ann Thorac Surg* 41: 130-134.
- Handy JR Jr, Asaph JW, Douville EC, Ott Gy, Grunkemeier GL, et al. (2010) Does video-assisted thoracoscopic lobectomy for lung cancer provide improved functional outcomes compared with open lobectomy? *Eur j Cardiothorac Surg* 37: 451-455.
- Bjork VO, Carlens E (1950) The prevention of spread during pulmonary resection by the use of double-lumen catheter. *J Thorac Surg* 20: 151-157.
- Amosov NM, Berezovsky KK (1961) Pulmonary resection with mechanical suture. *J Thorac cardiovasc Surg* 41: 325-335.
- Rikimaru H, Kiyokawa K, Inoue Y, Tai Y (2005) Three-dimensional anatomical vascular distribution in the pectoralis major myocutaneous flap. *Plast Reconstr Surg* 115: 1342-1352.
- Godat DM, Sanger JR, Lifchez SD et al. (2004) Detailed neurovascular anatomy of the serratus anterior muscle: implications for a functional muscle flap with multiple independent force vectors. *Plast Reconstr Surg* 114: 21-29.
- Mojallal A, Saint-Cyr M, Wong C, Veber M, Braye F, et al. (2010) [Muscle-sparing latissimus dorsi flap. Vascular anatomy and indications in breast reconstruction]. *Ann Chir Plast Esthet* 55: 87-96.
- (2009) Oxford Centre for Evidence-based medicine-levels of evidence (March 2009).
- Karwande SV, Pruitt JC (1989) A muscle-saving posterolateral thoracotomy. *Chest* 96: 1426-1427.
- Horowitz MD, Ancalmo N, Ochsner JL (1989) Thoracotomy through the auscultatory triangle. *Ann Thorac Surg* 47: 782-783.
- Ashour M (1990) Modified muscle sparing posterolateral thoracotomy. *Thorax* 45: 935-938.
- Bellamy J, Santillan D (1993) [A new posterolateral thoracotomy with preservation of the latissimus dorsi muscle]. *Ann Chir* 47: 174-178.
- Sadighi PJ, Woodworth CS (1998) Muscle-splitting thoracotomy. *Am Surg* 4: 370-371.
- Subramanian S, Halow KD (2000) Muscle-splitting posterolateral thoracotomy: A novel technique. *Curr Surg* 57: 74-77.
- Bethencourt DM, Holmes CE (1998) Muscle-sparing posterolateral thoracotomy. *Ann Thorac Surg* 45: 337-339.
- Hazelrigg SR, Landreneau RJ, Boley TM et al. (1991) The effect of muscle sparing versus standard posterolateral thoracotomy on pulmonary function, muscle strength and postoperative pain. *J Thorac Cardiovasc Surg* 101: 394-400.
- Ponn RB, Ferneini A, D'Agostino RS, Toole AL, Stern H (1992) Comparison of late pulmonary function after posterolateral and muscle sparing thoracotomy. *Ann Thorac Surg* 53: 675-679.
- Landreneau RJ, Hazelrigg SR, Mack MJ, Dowling RD, Burke D, et al. (1993) Postoperative pain related morbidity: video-assisted thoracic surgery versus thoracotomy. *Ann Thorac Surg* 56: 1285-1289.
- Landreneau RJ, Mack MJ, Hazelrigg SR, Naunheim K, Dowling RD, et al. (1994) Prevalence of chronic pain after pulmonary resection by thoracotomy or video-assisted thoracic surgery. *J Thorac Cardiovasc Surg* 107: 1079-1085.
- Landreneau RJ, Pigula F, Luketich JD, Keenan RJ, Bartley S, et al. (1996) Acute and chronic morbidity differences between muscle-sparing and standard lateral thoracotomies. *J Thorac Cardiovasc Surg* 112: 1346-1350.
- Kirby TJ, Mack MJ, Landreneau RJ, Rice TW (1995) Lobectomy- video-assisted thoracic surgery versus muscle-sparing thoracotomy: A randomized trial. *J Thorac Cardiovasc Surg* 109: 997-1001.
- Sugi K, Nawata S, Kaneda Y, Nawata K, Ueda K, et al. (1996) Disadvantages of muscle-sparing thoracotomy in patients with lung cancer. *World J Surg* 20: 551-555.
- Kutlu AC, Akin H, Biliciler U, Kayserililoglu A, Olcmen M et al. (2001) Shoulder girdle strength after standard and lateral muscle-sparing thoracotomy. *Thorac Cardiovasc Surg* 49: 112-114.
- Akcali Y, Demir H, Tezcan B (2002) A technique facilitating muscle-sparing thoracotomy. *Asian Cardiovasc Thorac Ann* 10: 194-195.
- Akcali Y, Demir H, Tezcan B (2003) The effect of standard posterolateral versus musclesparing thoracotomy on multiple parameters. *Ann Thorac Surg* 76: 1050-1054.
- Athanassiadi K, Kakaris S, Theakos N, Skottis I (2007) Muscle sparing versus posterolateral thoracotomy: a prospective study. *Eur J Cardiothorac Surg* 31: 496-499.
- Lemmer JH, Gomez MN, Symreng T, Ross AF, Rossi NP (1990) Limited lateral thoracotomy: improved postoperative pulmonary function. *Arch Surg* 125: 873-877.
- Normandin L, Page A, Verdant A (1991) [Thoracotomy with muscle-sparing]. *Ann Chir* 45: 760-763.
- Ginsberg RJ (1993) Alternative (muscle-sparing) incisions in thoracic surgery. *Ann Thorac Surg* 56: 752-754.
- Van Raemdonck D, Coosemans W, Lerut T (1993) Vertical axillary thoracotomy; a muscle-sparing approach for routine thoracic operations. *Acta*

- Chir Belg 93: 207-211.
41. Hennington MH, Ulicny KS, Detterbeck FC (1994) Vertical muscle-sparing thoracotomy. *Ann Thorac Surg* 57: 759-761.
 42. Kim D, Park S (2004) Feasibility of latissimus dorsi and serratus anterior muscle-sparing vertical thoracotomy in general thoracic surgery. *Interact Cardio Vasc Thorac Surg* 3: 456-459.
 43. Dubasov BS (1966) [Horizontal axillary thoracotomy in lung surgery]. *Vestn Khir Im I I grek* 97: 127-129.
 44. Dubasov BS (1968) The use of horizontal lateral thoracotomy in operations of the lungs. *Vestn Khir Im I I Grek* 100: 45-48.
 45. Noirclerc M, Dor V, Chauvin G et al. (1973) Extensive lateral thoracotomy without muscle section. *Ann Chir Thorac Cardiovasc* 12: 181-184.
 46. Tsybyrne KA, Gulia DI (1975) Lateral thoracotomy without dissection of the muscles and lateral neural-vascular bundle. *Grud Khir* 83-86.
 47. Ganul VL, Dorfman MV, Levchenko AM, Thachuk VA, Zakharychev VD (1976) Lateral thoracotomy without complete muscle dissection. *Klin Khir* 00: 45-48.
 48. Massimiano P, Ponn RB, Toole AB (1988) Transaxillary thoracotomy revisited. *Ann Thorac Surg* 45: 559-560.
 49. Fry WA, Kehoe TJ, McGee JP (1990) Axillary thoracotomy. *Am Surg* 56: 460-462.
 50. Mitchell R, Angell W, Wuerflein R, Dor V (1976) Simplified lateral chest incision for most thoracotomies other than sternotomy. *Ann Thorac Surg* 22: 284-286.
 51. Mitchell RL (1990) The lateral limited thoracotomy incision: standard for pulmonary operations. *J Thorac Cardiovasc Surg* 99: 590-596.
 52. Richelme H, Bourgeon A, Ferrari C, Limouse B, Pulcini A (1983) Lateral thoracotomy without muscular section in pleuro-pulmonary and mediastinal surgery. The experience of 624 operations over 5 years. *Chirurgie* 109: 404-414.
 53. Giudicelli R, Thomas P, Lonjon T, Ragni J, Morati N, et al. (1994) Video-assisted minithoracotomy versus muscle-sparing thoracotomy for performing lobectomy. *Ann Thorac Surg* 58: 712-717.
 54. Kittle CF (1988) Which way in? The thoracotomy incision. *Ann Thorac Surg* 45: 234.
 55. Tonielli E, Del Prete M, Brulatti M, Almerigi PL, Gelsomini S, et al. (1993) Axillary thoracotomy: A simple and non-destructive access to thoracic cavity. *Ann Ital Chir* 1: 75-77.
 56. Claeys D, Flamme H, Vanoverbeke H, Muysoms F (1995) Muscle-saving lateral axillary thoracotomy. *Acta Chir Belg* 95: 27-30.
 57. Carvalho PE, Leao LE, Giudici R, Rodrigues OR (1988) Economic lateral posterior thoracotomy. Minimally invasive option in pulmonary resections. *J Cardiovasc Surg* 39: 677-681.
 58. Yamaguchi A, Hashimoto O, Tamaki S (2006) French window thoracotomy: postoperative pain avoidance for short stay lung cancer surgery. *Jpn J Thorac Cardiovasc Surg* 54: 520-527.
 59. Naef AP (1958) Relative indications for anterior, lateral and posterior thoracotomy. *Helv Chir Acta* 25: 273-276.
 60. Mathey J, Aiugeperse J, Lalardrie JP (1961) The retropectoral axillar approach in thoracic surgery. *Ann Chir* 15: 1115-1124.
 61. Iacob G (1962) Considerations on 630 axillary approaches in thoracopulmonary surgery. *Poumon Coeur* 18: 377-386.
 62. Hayward RH, Knight WL, Baisden CE, Korompai F (1994) Access to the thorax by incision. *Am Coll Surg* 178: 202-208.
 63. Ochroch EA, Gotschalk A, Augoustides JG, Aukburg SJ, Kaiser LR, et al. (2005) Pain and physical function are similar following axillary, muscle-sparing vs. posterolateral thoracotomy. *Chest* 128: 2664-2670.
 64. Pettiford BL1, Schuchert MJ, Abbas G, Pennathur A, Gilbert S, et al. (2010) Anterior minithoracotomy: A direct approach to the difficult hilum for upper lobectomy, pneumonectomy and sleeve lobectomy. *Ann Surg Oncol* 17: 123-128.
 65. Gopaldas RR, Bakaeen FG, Dao TK, Walsh GL, Swisher SG, et al. (2010) Videoassisted thoracoscopic versus open thoracotomy lobectomy in a cohort of 13,619 patients. *Ann Thorac Surg* 89: 1563-1570.
 66. (2015) Video killed the radio star. Source: Wikipedia.

Copyright: © 2015 Durkovic S, et al. This is an open-access article distributed under the terms of the Creative Commons Attribution License, which permits unrestricted use, distribution, and reproduction in any medium, provided the original author and source are credited.

Citation: Durkovic S, Scanagatta P (2015) Muscle-Sparing Thoracotomy: A Systematic Literature Review and the "AVE" Classification. *J Surg Surgical Res* 1(3): 035-044. DOI: 10.17352/2454-2968.000011



Appendix	
A) Unavailable Articles:	
1.	Saute M, Sharony R, Uretzky G. Muscle-sparing thoracotomy: a renewed approach in thoracic surgery. <i>Harefuah</i> . 1995;128(1-2):8-9, 80.
2.	Nomori H, Horio H. Anteroaxillary thoracotomy for curative surgery in lung cancer. <i>Kyobu Geka</i> 1996;49:902-5.
3.	He J, Yang Y, Wei B. Clinical application of a modified small posterolateral thoracotomy in general thoracic surgery. <i>Zhonghua Wai Ke Za Zhi</i> 1997;35: 292-3.
4.	Wang YQ, Xia Y, Ye WW, He ZF, Chen ZM, Zhang WM, Guo Jg. Muscle-sparing thoracotomy in chest surgery. <i>Zhejiang Da Xue Bao Yi Xue Ban</i> 2004;33:554-5.
5.	Fang DQ, Peng PX, Liao CQ. A clinical study of lobectomy with minimally invasive incision. <i>Di Yi Jun Yi Da Xue Xue Bao</i> . 2005;25:1571-3.
6.	Yatsuyanagi E, Matsuda Y, Kusajima K. Surgical results of video-assisted lung resection for lung cancer; does surgical approach affect patient's satisfaction of surgery? <i>Kyobu Geka</i> . 2009;62:316-20.
B) Articles Excluded After Full-Text Review Because They Describe Anterolateral Thoracotomy With Division Of Pectoralis Major Muscle:	
1.	Motta G, Ratto GB, Sacco A. The use of anterolateral thoracotomy in pulmonary exeresis. <i>Min Chir</i> 1983;38:1255-1262.
2.	Nomori H, Horio H, Fuyuno G, Kobayashi R. Non serratus sparing antero-axillary thoracotomy with disconnection of anterior rib cartilage: Improvement in postoperative pulmonary function and pain in comparison to posterolateral thoracotomy. <i>Chest</i> 1997;111:572-576.
3.	Nomori H, Horio H, Suemasu K. Intrathoracic light-assisted anterior limited thoracotomy in lung cancer surgery. <i>Jpn J Surg</i> 1999;29:606-609.
4.	Nomori H, Horio H, Suemasu K. Anterior limited thoracotomy with intrathoracic illumination for lung cancer. Its advantages over anteroaxillary and posterolateral thoracotomy. <i>Chest</i> 1999;115:874-880.
5.	Nomori H, Horio H, Naruke T, Suemasu K. What is the advantage of a thoracoscopic lobectomy over a limited thoracotomy procedure for lung cancer surgery? <i>Ann Thorac Surg</i> 2001;72:8790-84.
6.	Nomori H, Ohtsuka T, Horio H, Naruke T, Suemasu K. Difference in the impairment of vital capacity and 6-minute walking after a lobectomy performed by thoracoscopic surgery, an anterior limited thoracotomy, an anteroaxillary thoracotomy, and a posterolateral thoracotomy. <i>Surg Today</i> 2003;33:7-12
C) Article Excluded Because It Describes Non-Muscle Sparing Posterolateral Thoracotomy:	
1.	Conolly JE. The technique of lateral thoracotomy. <i>Surg Gynecol Obstet</i> 1962;115:649-50.
D) Articles Excluded Because Patients Or Great Majority Of Them Did Not Undergo Major Pulmonary Resections:	
1	Baeza OR, Foster ED. Vertical axillary thoracotomy: A functional and cosmetically appealing incision. <i>Ann Thorac Surg</i> 1976;22:287-288.
2	Becker RM, Munro DD. Transaxillary thoracotomy: the optimal approach for certain pulmonary and mediastinal lesions. <i>Ann Thorac Surg</i> 1976;22:254-259.
3	Siegel T, Steiger Z. Axillary thoracotomy. <i>Surg Gynecol Obstet</i> 1982;155:725-7.
4	Khan IH, McManus KG, McCraith A, Mcguigan JA. Muscle sparing thoracotomy: a biomechanical analysis confirms preservation of muscle strength but no improvement in wound discomfort. <i>Eur J Cardiothorac Surg</i> 2000;18:656-61.
E) Articles Found Searching Through The References:	
1.	Mathey J, Aiugeperse J, Lalardrie JP. The retropectoral axillar approach in thoracic surgery. <i>Ann Chir</i> 1961;15:1115-1124.
2.	Iacob G. Considerations on 630 axillary approaches in thoracopleuro-pulmonary surgery. <i>Poumon Coeur</i> 1962;18:377-86.
3.	Kittle CF. Which way in? The thoracotomy incision. <i>Ann Thorac Surg</i> 1988;45:234.