

Gonzalo Martin^{1*}, Mohammed Iyoob
Mohammed Ilyas², José F Noguera³ and
Valentine Nfonsam²

¹General and Digestive Surgery Department,
Hospital Universitario Son Espases, Palma, Spain

²Department of Surgery, University of Arizona,
Tucson, Arizona, USA

³General and Digestive Surgery Department,
Complejo Hospitalario Universitario Juan Canalejo,
A Coruña, Spain

Dates: Received: 08 July, 2015; Accepted: 22
August, 2015; Published: 24 August, 2015

*Corresponding author: Gonzalo Martin MD,
PhD, General and Digestive Surgery Department,
Hospital Universitario Son Espases, Carretera de
Valldemossa, 79, PC: 07010, Palma, Spain, E-mail:
martin_martin_g@me.com

www.peertechz.com

ISSN: 2454-2968

Keywords: Right colectomy; Laparoscopy;
Transvaginal extraction; N.O.T.E.S and N.O.S.E

Case Report

Transvaginal Extraction of Laparoscopic Right Hemicolectomy Specimen

Abstract

Natural Orifice Specimen Extraction (NOSE) maintains the benefits of minimally invasive surgery obviating the need to extend the port site incisions for specimen extraction.

We describe the technique of transvaginal extraction of a laparoscopic right hemicolectomy specimen in sexually active 63 year old female. This included intracorporeal ileo-colic anastomosis and transvaginal colpotomy and extraction of specimen. Periodical follow up for 6 months did not show any complications with no reported dyspareunia. Multiple smaller studies have confirmed the safety of transvaginal extraction of resected colon. Transvaginal extraction of colonic specimen is an attractive option in women with minimal side effects if any.

Case Report

Laparoscopic surgery with natural orifice specimen extraction aims to improve the performance of conventional laparoscopic surgery by reducing the abdominal wall trauma with lower postoperative morbidity and better cosmetic result. The aim of this article is to explain our surgical technique of performing right hemicolectomy with transvaginal extraction.

A 63 year old sexually active female was evaluated for abdominal pain. Colonoscopy showed adenomatous polyp measuring 5 cm in the ascending colon which was not amenable for endoscopic resection. Clinical examination of the patient was otherwise normal including a normal vaginal examination. CT scan of her abdomen showed no other abnormalities. Her past medical history included bronchial asthma and hypertension. After informed consent, she was scheduled for laparoscopic right Hemicolectomy with transvaginal extraction of the specimen.

The procedure was performed in modified Lloyd-Davies position. After establishment of pneumoperitoneum with Veress needle, three trocars were placed – periumbilical (11mm), hypogastric (12mm) and right iliac fossa (5mm). The operating surgeon was between the legs and the first assistant to the left of the patient. Standard Laparoscopic instrumentations were used. Right Hemicolectomy was performed using medial to lateral approach and the ileocolic vessels were transected at its base with Thunderbeat™ (Olympus, Hamburg, Germany). The mesocolon was mobilized up to the mid transverse colon. The Toldt fascia was released to complete right colonic dissection. No pelvic abnormalities were noted. The transverse colon and terminal ileum were transected using (Endo GIA™ Tri-Staple 60mm/Medium-Thick, Covidien, Mans field, USA). Intracorporeal anastomosis with stapler was performed using Endo GIA™ Tri-Staple

60mm/Medium-Thick (Covidien, Mansfield, USA) and enterotomy and colotomy were closed using with continuous running stitches (V-Loc™, Covidien, Mans field, USA).

After povidone iodine washout of the vagina, a colpotomy was performed with a 12mm diameter / 15 cm long trocar (Endopath Xcel™ Bladeless trocar, Ethicon, Cincinnati, USA) through the posterior fornix of the vagina (Figure 1). The specimen was isolated using Endo Catch™ (Covidien, Mansfield, USA). The trocar was removed leaving the specimen with the Endo Catch™ in situ. The specimen was extracted with 1cm extension of the colpotomy incision on either side. The colpotomy was closed using absorbable intermittent polyglactin 910 (Vicryl, Ethicon, USA) (Figure 2). There were no intraoperative or postoperative complications. Estimated blood loss was 40 ml. Her postoperative stay was uneventful and was discharged home on the fourth postoperative day. The final histological report was tubulovillous adenoma with low-grade dysplasia and 14 negative lymph nodes. She was advised to avoid penetrative sex in the postoperative period for 4 weeks. She was followed up postoperatively at 1st week, 4th week, 12th week period and at 6 months. She did not have any

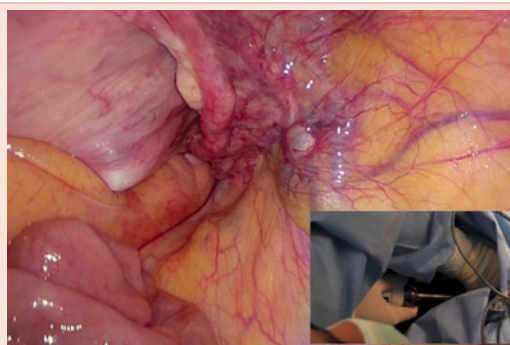


Figure 1: Colpotomy through the posterior vaginal fornix with 12mm trocar.

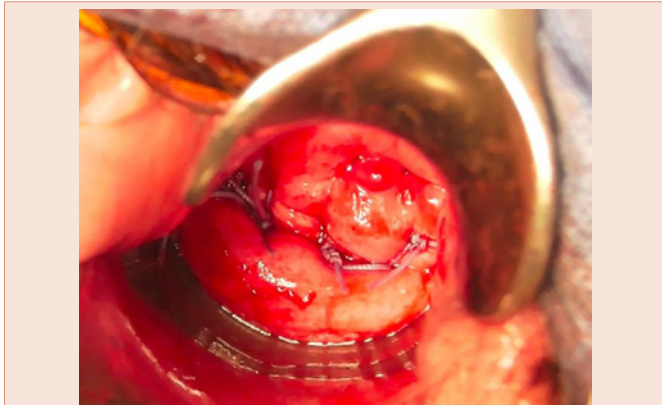


Figure 2: Colporrhaphy with independent stitches of absorbable material.

pain, bleeding or discharge from vagina in the postoperative period. She did not have any dyspareunia in the postoperative period.

Laparoscopic colorectal surgery has evolved over the last two decades considerably and its benefits are well established [1]. Specimen extraction through natural orifices to avoid extension of anterior abdominal wall port site incisions has gained more interest in the last few years. The transvaginal specimen extraction would help avoid mini laparotomy incision and would decrease the incidence of postoperative pain, wound infection and incidence of incisional hernia and would expedite the return to work [2-5]. The high elasticity and good healing of tissues in the vagina enables transvaginal route as an attractive option for colonic specimen extraction [4]. This could be recommended for all benign and malignant specimen extraction and the safety of the procedure has been established in smaller studies [3], but would need long term randomized study to confirm the benefits. Associated pelvic / gynecological abnormalities may make this technique more challenging. Various colpotomy techniques have been described in the literature. Colpotomy performed transperitoneally using laparoscopic instruments is associated with increasing technical

difficulty and iatrogenic injury due to loss of pneumoperitoneum [3,4]. A good orientation of the specimen in the endocatch with the ileum at the apex during retrieval is important to avoid “ball effect” making extraction difficult. Extracorporeal anastomosis has been favored more often due to the technical necessity in enlarging one of the port incisions for specimen retrieval at the end. The role of intracorporeal anastomosis described here has been validated in multiple studies. Cirocchi et al recently published a meta-analysis (7 studies, 945 patients) comparing intracorporeal and extracorporeal anastomosis showed no significant differences in terms of operating times, anastomotic leak and postoperative morbidity [6]. Literature available on colpotomy for specimen extraction do not show any increase in local complications including dyspareunia [2-4].

Transvaginal extraction of colonic specimen remains a very attractive option in colorectal surgery particularly with increasing interest in single port and robotic colorectal surgery.

References

1. Colon Cancer Laparoscopic or Open Resection Study Group, Buunen M, Veldkamp R, Hop WC, Kuhry E, Jeekel J, Haglind E, et al. (2009) Survival after laparoscopic surgery versus open surgery for colon cancer: long-term outcome of a randomized clinical trial. *Lancet Oncol* 10: 44-52.
2. Diana M, Perreta S, Wall J, Constantino FA, Leroy J, et al. (2011) Transvaginal specimen extraction in colorectal surgery: current state of the art. *Colorectal Dis* 13: 104-111.
3. Park JS, Choi GS, Kim HJ, Park SY, Jun SH. (2011) Natural orifice specimen extraction versus conventional laparoscopically assisted right hemicolectomy. *Br J Surg* 98: 710-715.
4. Torres RA, Orban RD, Tocaimaza L, Vallejos G, René J (2012) Transvaginal specimen extraction after laparoscopic colectomy. *World J Surg* 36: 1699-1702.
5. Palanivelu C, Rangarajan M, Jategaonkar PA, Anand NV (2008) An innovative technique for colorectal specimen retrieval: a new era of “Natural Orifice Specimen Extraction”(N.O.S.E). *Dis Colon Rectum* 51: 1120-1124.
6. Cirocchi R, Trastulli S, Farinella E, Guarino S, Desiderio J, et al. (2013) Intracorporeal versus extracorporeal anastomosis during laparoscopic right hemicolectomy - systematic review and meta-analysis. *Surg Oncol* 22: 1-13.

Copyright: © 2015 Martin G, et al. This is an open-access article distributed under the terms of the Creative Commons Attribution License, which permits unrestricted use, distribution, and reproduction in any medium, provided the original author and source are credited.

Citation: Martin G, Mohammed Ilyas MI, Noguera JF, Nfonsam V (2015) Transvaginal Extraction of Laparoscopic Right Hemicolectomy Specimen. *J Surg Surgical Res* 1(2): 031-032. DOI: 10.17352/2454-2968.000009