

Laszlo Gobolos^{1,2*}, Szabolcs Miskolczi¹,
Laszlo Hejmel² and Attila Konyi²

¹Department Cardiothoracic Surgery, Southampton General Hospital, Southampton University Hospital Trust, United Kingdom

²Coronary Care Unit, Heart Institute, University of Pecs, Faculty of Medicine, Pecs, Hungary

Dates: Received: 20 April, 2015; Accepted: 04 June, 2015; Published: 09 June, 2015

***Corresponding author:** Dr. Laszlo Gobolos, Department of Cardiothoracic Surgery, Southampton General Hospital, Southampton University Hospital Trust, UK, Tel: +44-7756-384938; Fax: +44-2380-794526; E-mail: isartor@hotmail.com

www.peertechz.com

ISSN: 2454-2968

Clinical Image

Central Venous Catheter Impacted into the Tricuspid Annulus over a Quarter Century

vena caval-right atrial region; additionally to a significant flow-limiting multivessel coronary artery disease (Panels A, B). The nature of the foreign body was initially unclear; the patient did not give a history of penetrating chest trauma or other major diseases. Further anamnestic review revealed a suicidal attempt 25 years before, which lead to a short intensive care stay. The patient underwent a conventional triple vessel CABG. After opening the right atrium, a fractured old-fashioned central venous cannula (CVC) was found being impacted with the tip into the tricuspid annulus; the curvature accurately shaped the route through superior vena cava to the tricuspid valve (Panels C, D). Following removal of the foreign body the patient had an uneventful postoperative course.

Image Description

A 58-year-old woman was referred for elective coronary bypass graft surgery (CABG). As an incidental finding, the coronary angiogram showed a radio-opaque linear foreign body in the superior

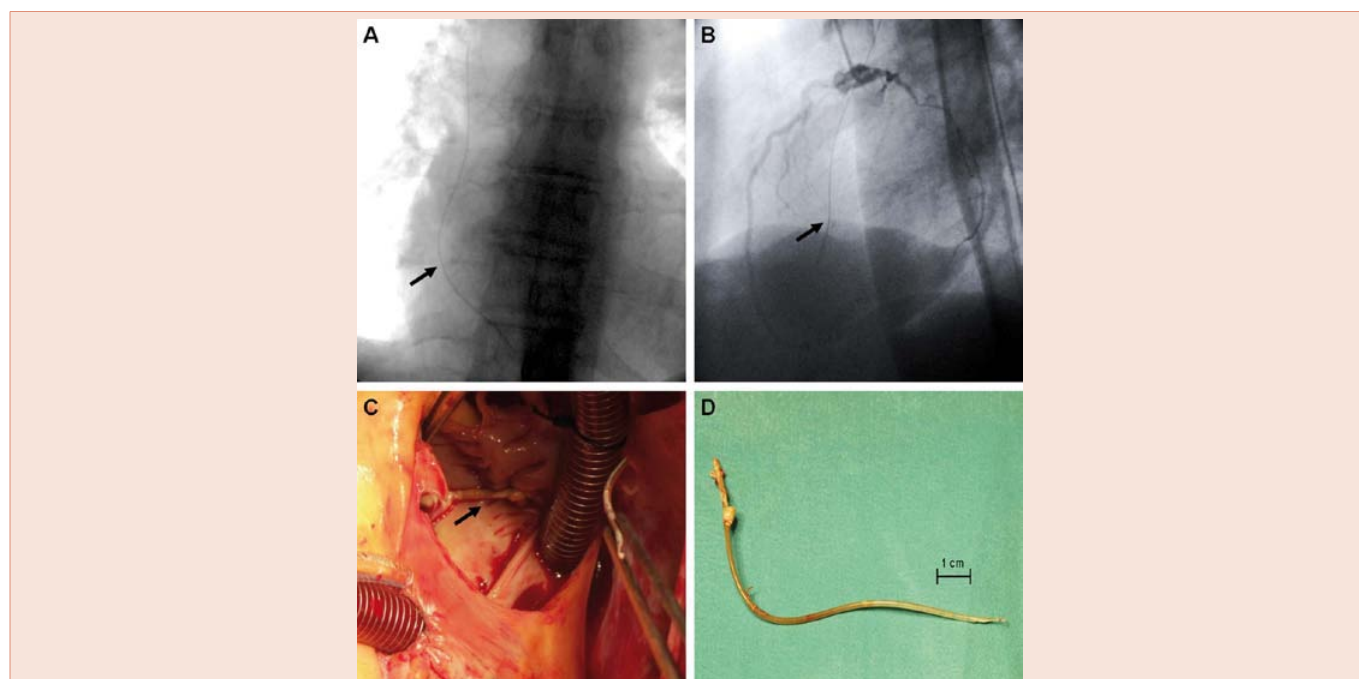


Figure 1:

Panel A: Anterior projection of the foreign body.

Panel B: Lateral image of the radio-opaque linear object.

Panel C: CVC line in situ visible via right atriotomy.

Panel D: The central line frozen shape well demonstrates the superior vena cava-right atrium continuity.

Copyright: © 2015 Cobanoglu U, et al. This is an open-access article distributed under the terms of the Creative Commons Attribution License, which permits unrestricted use, distribution, and reproduction in any medium, provided the original author and source are credited.