

Ramia JM\*, De La Plaza R, Kuhnhardt AW, Gonzalez JD, Valenzuela JC, Garcia-Amador C and Lopez-Marcano AJ

Hepato-Pancreato-Biliary Surgical Unit, Department of Surgery, Hospital Universitario de Guadalajara, Guadalajara, Spain

**Dates:** Received: 25 February, 2015; Accepted: 04 April, 2015; Published: 06 April, 2015

\*Corresponding author: J.M. Ramia, C/General Moscardó 26, 5-1, Madrid 28020, Spain, Tel: 34-616292056; E-mail: jose\_ramia@hotmail.com

[www.peertechz.com](http://www.peertechz.com)

ISSN: 2454-2968

**Keywords:** Hydatidosis; Review; Surgery; Portal hypertension

## Case Report

# Severe Vascular Complications Due to Liver Hydatid Cyst Relapse: A Case Report and Review of the Literature

### Abstract

Vascular complications of liver hydatidosis are infrequent but severe. We present a case with severe vascular problems due to a recurrence of a liver hydatid cyst. A 39 year-old male consulted the Emergency Department after frank hematemesis due to esophageal varices. He had undergone surgery at the age of seven in his native country for liver and lung hydatid cysts. Abdominal CT showed a 20 cm multivesicular cyst, occupying segments IV, V and VIII of the liver, displacing and partially compressing a dilated portal vein and causing portal hypertension and obstruction of the inferior cava vein. A subtotal cystectomy was performed. After surgery, portal vein flow was normal and esophageal varices disappeared, but caval obstruction remained. We review the vascular complications due to liver hydatidosis, focusing on therapeutic management.

## Introduction

Hepatic hydatid disease can cause multiple medical problems, including vascular complications. These complications are infrequent but are associated with high morbidity [1-10]. They occur when a liver hydatid cyst (LHC) compresses or erodes one of the great vessels: portal vein, hepatic veins and/or inferior cava vein (IVC), or smaller branches [6,11]. Here we describe a patient with a recurrence of a giant LHC causing compression of the portal vein and IVC, resulting in portal hypertension and re-distribution of venous flow via theazygos system causing hematemesis from esophageal varices.

## Case Report

A 39-year-old Moroccan male came to the Emergency Department after frank hematemesis. Blood analysis revealed the following noteworthy values: hemoglobin: 8.4 gr/dl, 8400 leukocytes/ul (29.1% eosinophils), and alkaline phosphatase: 180 U/l, GGT: 128 U/l. Upper gastrointestinal endoscopy was performed and esophageal varices with recent bleeding were seen. Past medical history included liver and lung surgery due to hydatid cysts at age of 7 (no medical reports). Abdominal ultrasound and CT showed a well-defined multivesicular cyst, with small foci of calcium in the wall, measuring 20 x 15 x 13 cm, occupying the segments IV, V and VIII of the liver, displacing and partially compressing a dilated portal vein and causing complete obstruction of the IVC (Figure 1). The radiological diagnosis was relapsed LHC. Cavography was performed, demonstrating a complete obstruction of IVC due to an extrinsic mass effect caused by the LHC. A large left renal vein redirected the venous flow through an enlarged azygos and hemiazygos system emptying into the superior cava vein. Hydatid serology was positive (1/320). We performed surgery to open the cyst, and then emptied and sterilized it (Figure 2). As we considered that radical cystectomy was impossible, we

performed a subtotal cystectomy and left a large drain in the cyst cavity. Postoperatively, the patient presented low output biliary fistula that did not require any treatment. The microbiological study of the liquid of the cyst confirmed *Echinococcus granulosus* infestation.

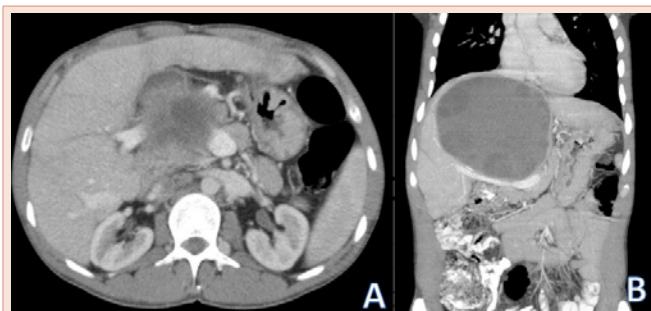


Figure 1: Portal compression. A: sagittal B: coronal.

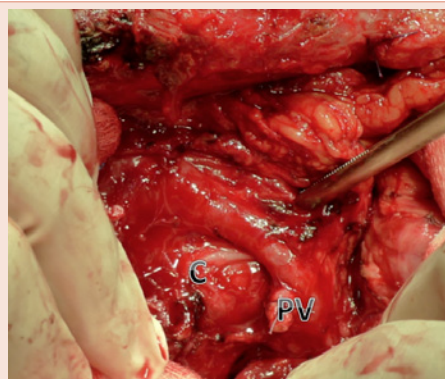


Figure 2: Operative surgical view. C: Cyst. PV: portal vein.

In 18 months of follow-up, no relapse has been observed. The most recent CT showed a residual cavity of 2.7 cm, normalization of portal flow but no IVC flow; flow by collateral circulation continues. Esophageal varices disappeared and serology of hydatidosis is currently negative.

## Discussion

LHC may cause serious vascular complications, affecting portal vein and its branches, the IVC, or both veins, as in our case [2,6].

The portal vein may be affected by extrinsic compression of a LHC producing portal flow obstruction which could cause portal vein thrombosis or, in exceptional cases, portal cavernomatosis [11]. Until 2010, only 11 publications had appeared in PubMed, including 25 patients with hydatidosis and portal hypertension. Eighty per cent of these patients had alveolar hydatid disease [11]. Clinically, LHC can cause prehepatic, hepatic and posthepatic portal hypertension (Budd-Chiari) [2,7,8,11]. A fistula between the LHC and the portal vein may occur, passing daughter vesicles into the bloodstream. This clinical situation has a high mortality [2,7,8]. Surgery for LHC may resolve the portal compression if the period of compression has been short but in cases of cavernomatosis of the portal vein, the venous flow is not usually restored.

Involvement of the IVC is more common in patients with alveolar hydatid disease related to diffuse injury that causes this type of infestation [6]. Compression of the IVC by the LHC may cause either complete or incomplete obstruction of the venous flow and may create a true thrombosis of the IVC, even cavernomatosis in extreme cases like ours [6]. In exceptional cases, a fistula between the LHC and the IVC may occur. In these patients, some hydatid membranes may pass from the cyst to the right atrium and indirectly produce a hydatid pulmonary embolism [1,3-5,9]. Despite the existence of a real fistula between IVC and LHC, exsanguination is exceptional because the pressure of the cyst is higher than the IVC and the pericystic wall hinders the passage of blood to the cyst. But when a fistula is present, anaphylactic or hemodynamic shock may occur and has a high morbidity and mortality [10]. Patients with involvement of the IVC due to LHC usually have large, centrally-located cysts. Thrombosis of the IVC due to LHC can cause acute symptoms but in most cases patients gradually manage to create tributary veins to resolve the obstruction and may, as in our case, be asymptomatic for a long period. Approximately 50% of patients with IVC thrombosis are asymptomatic when they are diagnosed [5].

The limited number of patients with vascular complications of LHC makes it difficult to draw conclusions about optimal treatment. We think that patients with vascular involvement due to LHC should always be treated surgically if their condition permits even if they are asymptomatic, before they develop severe future complications. Previous albendazole therapy is advisable. Some patients have been treated with PAIR, sometimes as single therapy due to severe comorbidities and/or a high surgical risk, or as a prelude to surgery [8,12]. In the case of anaphylactic or hemodynamic shock, emergency surgery is mandatory but mortality is extremely high.

In patients with portal vein involvement, the surgical technique performed depends on the degree of involvement and type of portal thrombosis. If there is only compression or a short contact with no (or only mild) portal thrombosis, radical surgery can be planned if it is not precluded by other clinical problems, but for cases with large-scale contact (either lengthwise or circumferential) or severe thrombosis with portal hypertension, conservative surgery is the best option [2,7,8]. In a very few cases, portal resection or prosthetic substitution has been performed.

Typically, in patients like ours with vascular involvement of the IVC, conservative surgery is chosen because of the difficulty of performing radical procedures [12]. When only lateral contact exists, total cystectomy is possible in selected cases. Some authors have performed liver resection with partial resection of the IVC [1,2,6], and a very small number of IVC resections with prosthetic replacement due to LHC have been reported [6]. This technical option is controversial; some authors consider the degree of surgery to be excessive for a benign disease, but on occasion it is the only possible solution to a severe problem [6,10].

In patients with Budd-Chiari syndrome, three options have been used: LHC surgery alone, shunt, or placement of percutaneous endoluminal prosthesis [11,13].

To conclude, vascular complications due to LHC are infrequent. The portal vein, the IVC, or both, may be affected. Degrees of severity range from compression to cavernomatosis. Patient may be asymptomatic, but extreme clinical situations could occur. In patients with vascular involvement due to LHC, conservative surgery is preferred because radical surgery is usually considered too risky.

## References

1. Gruttadauria S, Luca A, Cintorino D, Doria C, Scott VL, Marino IR (2003) Hepatic hydatid cyst causing thrombosis of the inferior vena cava and complicated by hemofilia. *Dig Dis Sci* 48: 358-364.
2. Zubiarre L, Oyarbazal I, Ruiz I, Guisasola E (2006) Invasion of the portal vein by a hydatid cyst. Review of the literature. *Gastroenterol Hepatol* 29: 405-408.
3. Bahamondes JC, Sandoval P, Losada H, Meriño G, Salaman J, et al. (2010) Quiste hidatídico hepático complicado con invasión a vena cava inferior y embolización de membranas hidatídicas a aurícula derecha. *Caso Clínico. Rev Chil Cir* 62: 179-182.
4. Blasco MA, Corrales M, Poza A, Sanchez JA (1993) Anaphylactic shock caused by spontaneous rupture of hepatic hydatid cyst into inferior vena cava. *Rev Clin Esp* 192: 49-50.
5. Karunajeewa HA, Jones RM, Hardy KJ, Buxton BF, Richards MJ (2002) Hydatid disease invading the inferior vena cava: successful combined medical and surgical Management. *ANZ J Surg* 72: 1 59-160.
6. Mekeel KL, Hemming AW (2007) Combined resection of the liver and the inferior vena cava for hydatid disease. *J Gastrointest Surg* 11: 1741-1743.
7. Gil-Egea MJ, Alamaeda F, Girvent M, Riera R, Sitges A (1998) Hydatid cyst in the hepatic hilum causing a cavernous transformation in the portal vein. *Gastroenterol Hepatol* 21: 227-229.
8. Kayacetin E, Hidayetoglu T (2004) Hydatid cyst of the liver causing a cavernous transformation in the portal vein and complicated by intrabiliary and intraperitoneal rupture. *J Gastroenterol Hepatol* 19: 1223-1224.



9. Sirmali M, Gezer S, Yol S, Kaya S (2006) Hydatid cyst of the pulmonary artery secondary to hepatic hydatid cyst. *Acta Chir Belg* 106: 441-442.
10. Kayaalp C (2007) Hydatid liver cyst ruptured into vena cava inferior. *Neth J Med* 65: 402-403.
11. Agarwal N, Dewan P (2010) Portal hypertension as a rare complication of hydatid cyst: diagnosis and management. *Int J Surg* 9: 1-6.
12. Rajagopal KV, Bishwas R (2002) Hydatid cyst of the liver presenting as inferior vena cava obstruction. *J Clin Ultrasound* 30: 114-116.
13. Sarawagi R, KeshavaSk, Surendrababu NRS, Zachariah UG, Eapen EC (2011) Budd-Chiari syndrome complicating hydatid cyst of the liver managed by venoplasty and stenting. *Cardiovasc Intervent Radiol* 34: s202-205.

**Copyright:** © 2015 Ramia JM, et al. This is an open-access article distributed under the terms of the Creative Commons Attribution License, which permits unrestricted use, distribution, and reproduction in any medium, provided the original author and source are credited.

**Citation:** Ramia JM, De La Plaza R, Kuhnhardt AW, Gonzalez JD, Valenzuela JC, et al. (2015) Severe Vascular Complications Due to Liver Hydatid Cyst Relapse: A Case Report and Review of the Literature. *J Surg Surgical Res* 1(1): 001-003. DOI: 10.17352/2454-2968.000001