

Caterina Pizzicaroli¹ and Giovanni Larciprete^{2*}

¹Department of Obstetrics and Gynecology, Tor Vergata University, Rome, Italy

²Department of Obstetrics and Gynecology, Fatebenefratelli Isola Tiberina Hospital, Rome, Italy

Dates: Received: 09 June, 2016; Accepted: 28 June, 2016; Published: 29 June, 2016

***Corresponding author:** Giovanni Larciprete, Department of Obstetrics and Gynecology, Fatebenefratelli Isola Tiberina Hospital, Rome, Italy, E-mail: glarciprete@libero.it

www.peertechz.com

Case Report

A Rare Case of Asymptomatic Postmenopausal Tubercular Endometritis in Italy

Abstract

Introduction: Tuberculosis affects about a third of world population. Genitourinary tuberculosis is one of the most common manifestations of extra pulmonary tuberculosis. Postmenopausal tubercular endometritis is an uncommon condition that usually occurs with abnormal vaginal bleeding.

Aim: The aim of the paper is to report a rare case of asymptomatic postmenopausal tubercular endometritis.

Case report: Trans-abdominal and trans-vaginal ultrasound performed in a 59 years-old Romanian asymptomatic woman showed a huge hypo-echoic area centrally located in the uterine shape and a severe endometrial hypo-echoic thickness (> 2 cm). Color Doppler did not detect any vascularity into this area. Magnetic Resonance Imaging (MRI) of the lower abdomen confirmed the severe endometrial thickness. The histopathological diagnosis obtained by biopsy during hysteroscopy documented tubercular endometritis. The patient started a medical treatment for tuberculosis. Forty days later a control ultrasound showed the fluidization of the caseous material in the uterine cavity.

Discussion: The main localizations of genitourinary tuberculosis are primarily the fallopian tubes, then it spreads towards endometrium, cervix, vagina and ovaries. In post-menopausal age patients with tubercular endometritis usually present with a story of vaginal bleeding; however, patients may be asymptomatic or they may present aspecific symptoms. This usually leads to a delay in diagnosis and therapeutical interventions.

Conclusions: Tubercular endometritis is a severe disease that may affect both pre- and post-menopausal woman. Symptoms could be absent or aspecific. Diagnosis is not simple and it often needs laparoscopy, laparotomy or hysteroscopy. Histology is needful for the correct diagnosis. A standard medical anti-tubercular therapy of 6 months is often sufficient to obtain a complete therapeutical response. In some selected cases surgery may be necessary. In our paper, an asymptomatic woman in post-menopausal age, affected by endometrial tuberculosis showed clinical response after a standard antitubercular medical therapy.

Introduction

Tuberculosis affects about a third of mondial population mostly resident in developing countries with inadequate health services [1]. In 1990 this disease was considered a global emergency because of the increased number of immigrants from developing countries to the industrialized ones, and the great number of HIV-infected patients [2].

When tuberculosis affects the reproductive system, it causes devastating effects, i.e. infertility due to an irreversible damage to the fallopian tubes [3,4]. Female urogenital tuberculosis often remains silent or may not present a specific symptomatology, so that its prevalence is largely underestimated. In developing countries (such as Africa) the incidence of this disease is about 15-19 % [5], in USA, Australia and Western European countries the incidence is less than 1% [6-7].

Postmenopausal tuberculosis of the endometrium is not a common condition. It usually presents with abnormal vaginal bleeding [1,4,8]. Diagnosis is not simple [9] and it often needs laparoscopy, laparotomy or dilatation and curettage of uterine

cavity (D&C). Imaging investigations are not specific. A standard anti-tubercular therapy of 6 months [10,11], is considered sufficient to obtain a complete therapeutic response, but in some cases patients need a surgical treatment [12,13].

The authors report a case of asymptomatic tubercular endometritis in a Romanian woman, in post-menopausal age, who lived in Italy for five years, from 2004 to 2009.

Case Report

A 59 years-old Romanian woman with a history of HCV-related chronic liver disease, underwent abdominal ultrasound scan. She was totally asymptomatic. The patient was obese (weight: 82 kg, height: 165 cm, body mass index (BMI): 30.1 kg/m²). She referred no pregnancy in her life, menopause at the age of 50 years and no smoke or alcohol assumption. She was affected by arterial hypertension, diabetes and chronic gastritis. Her home therapy was: Felodipine 10 mg cp (1cp/die), Lansoprazole 15 mg cp (1cp/die) and Metformin 500 mg cp (1 cp twice).

The ultrasound of the upper abdomen just documented a mild liver steatosis. No abnormal sonographic appearance was identified

in gallbladder, pancreas, kidneys and spleen. The trans-abdominal ultrasound of the lower abdomen showed a physiologically relaxed bladder without parietal or endoluminal alterations. Collaterally a huge hypoechoic area centrally located in the uterine shape was detected (Figure 1A).

Due to the patient's globular abdomen, it was difficult to obtain further informations about the uterus by using the trans-abdominal probe. So the echographist, in agreement with the patient, decided to perform trans-vaginal (TV) ultrasound. The uterus appeared of normal dimensions, and it was median, anteversed and anteфлекted. There was an abnormal thickening of endometrium (AP diameter > 2 cm) that presented lack of homogeneity, disappearance of the cavity line and a little demarcation with myometrium (Figure 1B,C). With Color-Doppler, no vascularization was appreciated into the hypoechoic area of the uterus (Figure 1D). No liquid was detected in Douglas, nor adnexal diseases. The patient never had abnormal vaginal bleeding.

Because of this abnormal post-menopausal endometrial thickening, a MR scan with contrast was performed to better analyze the endometrium and the perirectal and paravaginal tissues, and to have informations about aortic, iliac and obturatory lymphonodal stations. The MR scan confirmed the relevant endometrial thickness (AP diameter > 2 cm) needing a histological characterization (Figure 2A,B).

So the patient underwent hysteroscopy with endometrial biopsy. We don't have hysteroscopic images because the patient performed hysteroscopy elsewhere without giving us iconographic report. The histological diagnosis was that of chronic granulomatous not necrotizing tubercular endometritis. The microbiologic cultures for alcohol-acid resistant bacilli and mycete were negative.

The patient started a standard oral treatment for tuberculosis with combination of two drugs: Rifampicin 600 mg once a day and Isoniazid 200 mg three times a day. After 40 days of therapy, the patient underwent a control TV: the huge disomogeneous and hypoechoic area, was replaced by an anechoic area because of the fluidization of the caseous material induced by the therapy (Figure 3). After this ultrasound control the patient came back to Romania. Then she referred she continued the anti-tubercular therapy for 6 months with a complete remission of the endometrial tuberculosis. No ultrasound images are available of the complete remission of the pathology.

Discussion

In 1990, a total of 3,8 million cases of tuberculosis were notified to WHO, 49% of them were from sud-est of Asia. An association with HIV infection was revealed [14]. The main pathological localization of *Mycobacterium tuberculosis* is the respiratory tract; however, all the organs of the body can be reached by this infective agent: bones, arteries, kidneys, liver, spleen, prostate gland, epididymides, uterus, gastro-enteric tract, adrenogenital glands, subarachnoid space, peritoneum, pericardium and lymph nodes [9,15].

Primary genital tuberculosis is extremely rare, whereas it is almost always secondary to tuberculosis infection elsewhere in the

body. Genital tuberculosis is the most common manifestation of extra-pulmonary tuberculosis [8,9,16], representing the 15-19% of extra pulmonary tubercular cases [5]. The global prevalence of genital tuberculosis has increased from 22 million cases in 1995 to 1.86 billion cases in 2005, with a 5-10% rate of infertility [17]. It is usually misunderstood by health-care providers, but is an important cause of significant morbidity, with short- and long-term sequelae for the affected women [18].

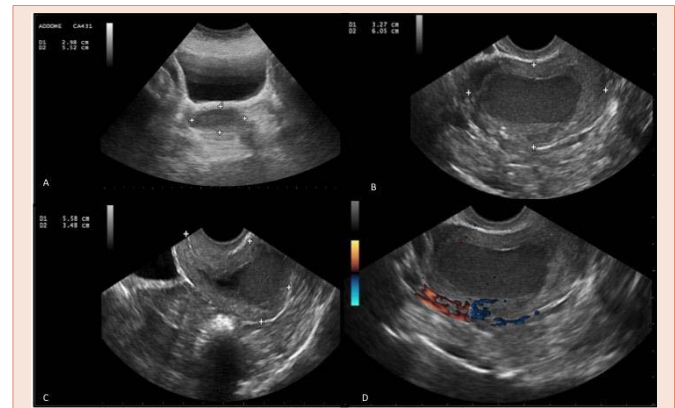


Figure 1: ULTRASOUND IMAGES: A: Transabdominal ultrasound: huge hypoechoic area centrally located in the uterine shape: B-C: Transvaginal ultrasound: huge disomogeneous endometrial mass (AP diameter > 2 cm) that seems to be characterized by necrotic-colliquative material, disappearance of the line of the cavity and little demarcation with myometrium. D: Transvaginal ultrasound: Colour Doppler shows no vascularization of the ipoechoic area of the uterus.

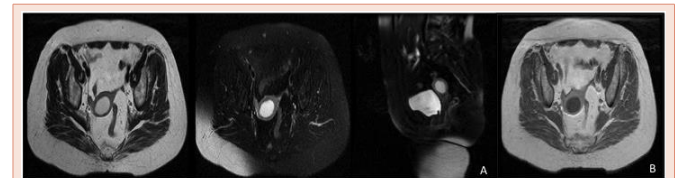


Figure 2: A: T2-weighted MR scans: the uterine mass appears hyperintense and there's no evidence of pathology involving ovaries or limphnodes. The bladder appears full and bright. B: T1-weighted MR scans: the uterine mass appears hypo-intense.

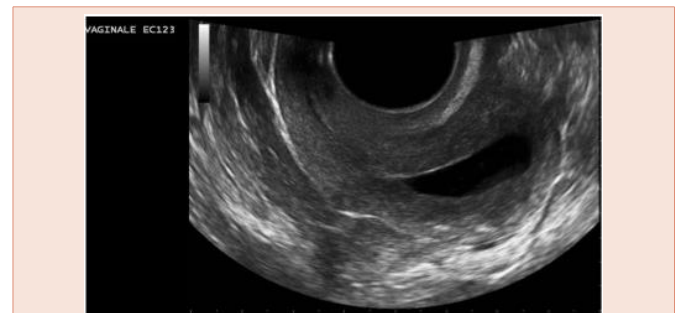


Figure 3: Transvaginal ultrasound 40th days after the start of the therapy: fluidization of the caseous material.

The extra-pulmonary foci are probably colonized by hematogenous spread of the bacilli. The main genital localizations of *Mycobacterium tuberculosis* are the fallopian tubes (90-100 % of cases) [19], then it spreads towards uterus (50-60%), ovaries (20-30%), cervix (5-15%), and vagina (1 %) [10,20,21].

Patients with genital tuberculosis are usually young women with a story of infertility [8], chronic pelvic disease [22], or ectopic pregnancy [23]. Genital tuberculosis is usually asymptomatic. The main causes of a gynecological consultations are infertility (44%), pelvic pain (25%), abnormal vaginal bleeding (18%), amenorrhea (5%) and leukorrhea (4%). Patients can rarely present with abdominal mass, ascites or a tubo-ovarian abscess [24].

Postmenopausal tuberculosis of the endometrium is not a common condition. It usually presents with abnormal vaginal bleeding [1,4,8,24], but it may also present without specific symptoms. This is why there's usually a delay in diagnosis and in therapeutic interventions. Many authors explain the low incidence of this disease in post-menopausal age, assessing that atrophic endometrium represents a poor ground for mycobacterial growth [1,25]. Abnormal vaginal bleeding represents the 5% of causes of a gynecological consultation in post-menopausal age [26]. Differential diagnosis to consider may be endometrial atrophy (59%), endometrial polyps (12%), endometrial cancer (10%), pyometra (13,6%), endometrial hyperplasia, hormonal response, cervical cancer, other infections [8,27,28]. In the differential diagnosis of an ovarian tumor, an endometrial cancer and ascites, genital tuberculosis should always be considered [13,29,30].

Diagnosis of genitourinary tuberculosis is not simple [9] and often may need laparoscopy, laparotomy or dilatation and curettage of uterine cavity (D&C). Urine culture is not useful for diagnosis. Imaging investigations are not specific. Hysterosalpingography may show calcified pelvic lymphadenopathy and adhesions in the uterine cavity with some typical aspect, but it is not very specific nor sensible [20]. Dadhwal et al. [18], reported that the clinician should be aware that isolation of *Mycobacterium Tuberculosis* requires special methods and this diagnosis should be considered while dealing with patients born in countries with high prevalence of Tuberculosis.

Definitive diagnosis requires the identification of *Mycobacterium tuberculosis* either by direct microscopic examination or after culturing pathological specimens. Tangappah [3], reported that in the presence of positive molecular investigation with PCR an infertile woman should be considered as having genital tuberculosis and should be treated. Concerns remain about the high false-negative results with PCR techniques. Besides the long period required for their culture, in paucibacillary endometrial samples, acid-fast bacilli smears are almost always negative [31].

For genital tuberculosis, treatment guidelines recommend a standard anti-tubercular therapy of 6 months, providing that pyrazinamide is included for the first two months of treatment and that the organism is susceptible [11]. The main anti-tubercular drugs are: Streptomycin, Isoniazid, Ethambutol, Rifampicin, and Pyrazinamide [10].

Surgical treatment may be considered in case of persistence of adnexal mass (especially the cold abscess) after medical approach, recurrence of endometrial tuberculosis after a year of treatment, persistence of pelvic pain after 3 months of medical therapy, persistence of vaginal bleeding, fistulas that do not resolve [12,13]. The surgical treatment should be carried out at least 6 weeks after initiation of the pharmacological treatment, because this reduces the risk of intraoperative complications and facilitates the surgical procedure itself [1].

Conclusions

Tubercular endometritis is a severe condition that may affect both pre- and post-menopausal woman and may present both with or without symptoms. Diagnosis may be difficult and requires laparoscopy, laparotomy or D&C. Ultrasound examination may detect a mass of the lower abdomen but it does not provide information about the nature of the mass itself.

A standard anti-tubercular therapy of 6 months is considered adequate to obtain a complete therapeutical response; however, in some cases a surgical approach may be necessary. Progress should be done in diagnostic strategies of this disease, to avoid the progression of the pathology in postmenopausal age, and to correct the damages caused at the reproductive system in fertile age.

This paper shows that postmenopausal tubercular endometritis may be asymptomatic and even if it is not a common condition, it has always to be considered in differential diagnosis of an ovarian tumor and an endometrial cancer.

References

- Gungorduk K, Ulker V, Sahbaz A, Ark C, Tekirdag AI (2007) Postmenopausal tuberculosis endometritis. *Infect Dis Obstet Gynecol*. 2007: 27028.
- Panoskaltis T. A, Moore D. A, Haidopoulos D. A, and McIndoe A. G (2000) Tuberculous peritonitis: part of the differential diagnosis in ovarian cancer. *Am J Obstet Gynecol* 182: 740-742.
- Thangappah RBP, Paramasivan CN, Sujatha Narayanan (2011) Evaluating PCR, culture & histopathology in the diagnosis of female genital tuberculosis. *Indian J Med Res* 134: 40-46.
- Khan R, Sherwani RK, Rana S, Hakim S, Jairajpuri SZ (2016) Clinico-Pathological Patterns in Women with Dysfunctional Uterine Bleeding. *Iran J Pathol* 11: 20-26.
- Aabebe M, Lakew M, Kidane D, Lakew Z, Kiros K, et al. (2004) Female genital tuberculosis in Ethiopia. *Int J Gynaecol Obstet* 84: 241-246.
- Punnonen R, Kiilholma P, Meurman L (1983) Female genital tuberculosis and consequent infertility. *Int J Fertil* 28:235-238.
- Schaefer G (1976) Female genital tuberculosis. *Clin Obstet Gynecol* 19: 223-229.
- Sutherland AM (1980) Surgical treatment of tuberculosis of the female genital tract. *Br J Obstet Gynaecol* 87: 610-612.
- Júlio C, Amaral N, Biscaia I, Torrezao I, Fatela A (2010) Genital tuberculosis: a rare cause of postmenopausal bleeding. *Acta Med Port* 23: 723-726.
- Engin G, Acunas G, Tunaci M (2000) Imaging of extrapulmonary tuberculosis. *Radiographics* 20: 471-488.
- Genet C, Ducroix-Roubertou S, Gondran G, Bezanahary H, Weinbreck P, et al. (2006) Post-menopausal endometrial tuberculosis. *J Gynecol Obstet Biol Reprod* 35: 71-73.

12. Blumberg HM, Burman WJ, Chaisson RE, Daley CL, Etkind SC, et al. (2003) American Thoracic Society/Centers for Disease Control and Prevention/ Infectious Diseases Society of America: treatment of tuberculosis. *American Journal of Respiratory and Critical Care Medicine* 167: 603-662.
13. Taleb Ahmed L, Bouchetara LK, Boutteville C (1989) La tuberculose génitale de la femme. *EMC de Gynécologie* 490-A-10.
14. Horsburgh CR Jr (2004) Priorities for the treatment of latent tuberculosis infection in the United States. *N Engl J Med* 350: 2060-2067.
15. Lado Lado FL, Tunes Bastida V, Golpe Gomez AL, Ferreira Regueiro MJ, Carbarcos Ortiz de Barrón A (2000) Extrapulmonary tuberculosis in our area. Forms of presentation. *An Med Interna* 17: 637-641.
16. Hsieh HC, Lu PL, Chen YH, Chen TC, Tsai JJ, et al. (2006) Genitourinary tuberculosis in a medical center in southern Taiwan: an eleven-year experience. *J Microbiol Immunol Infect* 39: 408-413.
17. Kanna A, Agrawal A (2001) Markers of genital tuberculosis in infertility. *Singapore Med J* 52: 864-867.
18. Dadhwal V, Gupta N, Bahadur A, Mittal S (2009) Flare-Up of genital tuberculosis following endometrial aspiration in a patient with general miliary tuberculosis. *Arch Gynecol Obstet* 280: 503-504.
19. Gunes HA, Göze OF, Duzcan E, Egilmez R, Ozbilim G, et al. (1991) Female genital tract tuberculosis. *Mikrobiyol Bul* 25: 247-255.
20. Jones HW, Went AC, Burnett LS (1988) *Novak's textbook of gynecology*. Williams & Wilkins, Baltimore 557-569.
21. Nogales-Ortiz F, Tarancón I, Nogales FF Jr (1979) The pathology of female genital tuberculosis. A 31-year study of 1436 cases. *Obstet Gynecol* 53: 422-428.
22. Martens MG (1997) Pelvic inflammatory disease. *Telind's Operative Gynecology* 678-685.
23. Mondal SK, Dutta TK (2009) A ten year clinicopathological study of female genital tuberculosis and impact on fertility. *J Nepal Med Assoc* 48: 52-57.
24. Saygili U, Guclu S, Altunyurt S, Koyuncuoglu M, Onvural A (2002) Primary endometrioid adenocarcinoma with coexisting Endometrial tuberculosis: a case report. *Journal of Reproductive Medicine* 47: 322-324.
25. Mestre MA, Manzano CD, López RM (2004) Postmenopausal endometrial tuberculosis. *Int J Gynaecol Obstet* 86: 405-406.
26. Moodley M, Roberts C (2004) Clinical pathway for the evaluation of postmenopausal bleeding with an emphasis on endometrial cancer detection. *J Obstet Gynaecol* 24: 736-741.
27. Karlsson B, Granberg G, Wikland M et al. (1995) transvaginal ultrasonography of endometrium in women with postmenopausal bleeding- A Nordic multicentric study. *Am J Obstet Gynecol* 172: 1488-1494.
28. Sharma N, Singh AS, Bhaphiralyne WJ (2016) Spontaneous Perforation of Pyometra. *Menopausal Med* 22: 47-49.
29. Pesut D, Stojdic J (2007) Female genital tuberculosis: a disease seen again in Europe. *Vojnosanit Pregl* 64: 855-858.
30. Kawatra V, Kohli K, Khurana N (2010) Pelvic tuberculosis mimicking ovarian malignancy: a case report. *J Reprod Med* 55: 449-451.
31. Kohli MD, Nambam B, Trivedi SS, Sherwal BL, Arora S, et al. (2011) PCR-Based Evaluation of Tuberculous Endometritis in Infertile Women of North India. *J Reprod Infertil* 12: 9-14.

Copyright: © 2016 Pizzicaroli C, et al. This is an open-access article distributed under the terms of the Creative Commons Attribution License, which permits unrestricted use, distribution, and reproduction in any medium, provided the original author and source are credited.

Citation: Pizzicaroli C, Larciprete G (2016) A Rare Case of Asymptomatic Postmenopausal Tubercular Endometritis in Italy. *J Gynecol Res Obstet* 2(1): 043-046.