

Virendra N. Sehgal*, Shalini Malhotra and Venkatesh Ramesh

Dermato-Venereology (Skin/VD center, Sehgal Nursing Home, Panchwati-Delhi, India)
Departments of Dermatology and Venereology, Vardhman Mahavir Medical College and Safdarjung hospital, New Delhi, India

Dates: Received: 25 February, 2015; Accepted: 25 April, 2015; Published: 27 March, 2015

***Corresponding author:** Dir. Prof. (Dr.) Virendra N Sehgal MD, FNAsc, FAMS, FRAS (Lond.), Dermato-Venereology (Skin/VD) Centre, Sehgal Nursing Home, A-6 Panchwati, Delhi 110 033 India, Tel: 011-27675363, Mobile: 9810182241; Fax: 91-11-2767-0373; E-mail: drsehgal@ndf.vsnl.net.in, sehgalvn@yahoo.co.in

www.peertechz.com

ISSN: 2455-8605

Clinical Image

Nodular Scabies of the Genitals

scabies's prevalence seems to be unaffected by sex, race, age, or socioeconomic status, poverty and overcrowding living conditions may facilitate its spread [1]. Very young and/or old children and young adults [2] are its usual victims, in addition to mothers of young children and the elderly, suffering from immuno-compromised crusted scabies in nursing homes. Lack of sensitization and/or reduced scratching can develop localized crusting in affected areas [1,2]. Nevertheless, reduced immunity and increased exposure correlate well with its endemicity [3].

Sarcoptes scabiei creates the superficial burrow(s), a cardinal sign of scabies, usually occurring in the area of the hands, feet, wrists, elbows, back, buttocks, and external genitals. Nodular scabies of the genitals is its extra ordinary manifestation, and should be taken cognizance of. It is contagious attended by nocturnal itching, and may engulf the family, intra-familial [4-6].

Conventional India ink or gentian violets are good adjuncts to make a burrow explicit. The ink is painted onto the site and excess stain is removed with alcohol. The stain is taken up by burrow through capillary action, and is seen as a linear colored streak.

Recent advent of epiluminiscence microscopy/dermatoscopy and video-dermatoscopy⁷ has added refreshing dimensions, for it is effective and sensitive diagnostic tool. It also assists in enhancing the therapeutic follow-up and optimizes the timing of drug therapy, minimizing the risk of over- or under-treatment, and to reduce the potential for side-effects. Compliance too is solicited, especially in those where itch persists after treatment.

References

- Walton SF, Holt DC, Currie BJ, Kemp DJ (2004) Scabies: new future for a neglected disease. *Adv Parasitol* 57: 309-376.
- Alexander JO (1984) Infestation by Hemiptera. In: *Arthropods and Human Skin*. Berlin, Germany: Springer-Verlag Pp: 57-74.
- Currie B, Hengge U (2006) Scabies. In *Tyring S, Lupi O, Hengge U. eds. Tropical dermatology*. Elsevier Churchill Livingstone, London, United Kingdom. Pp: 375-388.
- Sehgal VN, Rao TL, Rege VL, Vadiraj SN (1972) Scabies: a study of incidence and a treatment method. *Int J Dermatol* 11: 106-111.
- Hay RJ (2009) Scabies and pyoderma--diagnosis and treatment. *Dermatol Ther* 22: 466-474.
- Sehgal VN, Verma P, Khurana A (2012) *Sarcoptes scabiei* and scabies. In *Textbook of dermatoses in tropics*. Sehgal VN Ed. J.P Brothers. Delhi (In Press).
- Lacarrubba F, Musumeci ML, Caltabiano R, Impallomeni R, West DP, et al. (2001) High-magnification videodermatoscopy: a new noninvasive diagnostic tool for scabies in children. *Pediatr Dermatol* 18: 439-441.

Copyright: © 2015 Sehgal VN, et al. This is an open-access article distributed under the terms of the Creative Commons Attribution License, which permits unrestricted use, distribution, and reproduction in any medium, provided the original author and source are credited.

A 20 years-old-man, a native Indian of low socio-economic reckoning, had come to clinic with the complaints of severe nocturnal itching of the genitals for the past one month. A similar complaint was registered by other members of the household. The early diagnosis of the condition seemed to have been overlooked, because of conspicuous sparing of the usual sites namely the anterior axillary folds, elbows, wrists, webs of the fingers and around the umbilicus of the abdomen. Skin surface examination of the genitals, however, was remarkable, because it was studded by nodules of the size varying from 0.5 to 1cm. They were numerous (Figure 1a). Burrows were interspersed amongst them, and had miscellaneous configuration, harbouring *Sarcoptes scabiei* (Figure 1b). The imperative of its demonstration are emphasized to confirm the diagnosis.

Sarcoptic mange caused by the mite *Sarcoptes scabiei* is a worldwide disease affecting both humans and animals. Although,

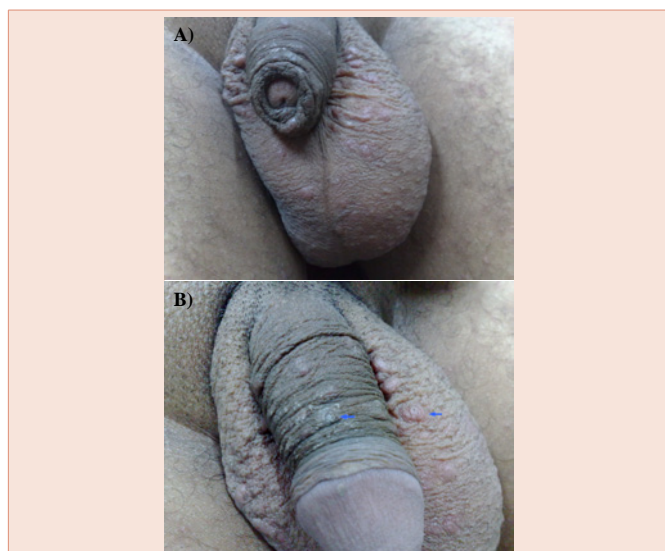


Figure 1: Genitals depicting nodular lesions and burrows (arrow).