

Claudia Florida Costea^{1,5}, Cristina Rusu², Camelia Geanina Ivănescu³, Silvia Dumitraș⁴, Gabriela Dimitriu⁵, Andrei Cucu⁶, Mircea Albert⁷, Dana Mihaela Turliuc^{6,8} and Ingrith Crenguța Miron^{4,9}

¹Department of Ophthalmology, "Grigore T. Popa" University of Medicine and Pharmacy, Iassy, Romania

²Department of Genetics, "Grigore T. Popa" University of Medicine and Pharmacy, Iassy, Romania

³Pediatric Hematology and Oncology Unit, "Sf. Maria" Emergency Children's, Hospital of Iassy, Romania

⁴IVth Pediatric Unit, "Sf. Maria" Emergency Children's Hospital of Iassy, Romania

⁵IInd Ophthalmology Clinic, "Prof. Dr. Nicolae Oblu" Emergency Hospital, Iassy, Romania

⁶Neurosurgery Unit II, "Prof. Dr. Nicolae Oblu" Emergency Hospital, Iassy, Romania

⁷Department of Radiology, "Prof. Dr. Nicolae Oblu" Emergency Clinical Hospital, Iassy, Romania

⁸Department of Neurosurgery, "Grigore T. Popa" University of Medicine and Pharmacy, Iassy, Romania

⁹Department of Pediatrics, "Gr. T. Popa" University of Medicine of Iassy, Romania

Dates: Received: 09 March, 2015; **Accepted:** 09 April, 2015; **Published:** 11 April, 2015

***Corresponding author:** Claudia Florida Costea, Assistant, PhD, Senior ophthalmologist, Department of Ophthalmology, "Grigore T. Popa" University of Medicine and Pharmacy, 34 Brândușa Street, 700374 Iasi, Romania; Tel: +40744972648; Fax +40232-210 064; E-mail: costea10@yahoo.com

www.peertechz.com

Keywords: Goldenhar syndrome; Microphthalmia; Ear malformation; Vertebral malformations

ISSN: 2455-1414

Case Report

Goldenhar Syndrome

Abstract

Goldenhar syndrome (Oculo-Auriculo-Vertebral Spectrum) (OAVS) is a rare congenital condition characterized by craniofacial abnormalities associated with anomalies of the spine, heart, kidney, central nervous and gastrointestinal system. Craniofacial abnormalities include the incomplete development of the eye, ear, nose, soft palate, lips and jaw. We report a case of Goldenhar syndrome in a 14-years-old male patient. There are no other identified cases of congenital diseases in the patient's family history. At the age of 2, the patient was operated for complete right cleft lip and cleft palate dehiscence and it was then, that the suspicion for Goldenhar syndrome was harboured.

The Goldenhar Syndrome diagnosis is clinical, as there are no specific genetic tests to detect this condition. The patient's karyotype was performed in the Genetics Clinic in order to exclude an eventual chromosomal abnormality. The result had been normal (46, XY).

The ophthalmologic examination revealed the microphthalmia of the right eyeball. The ENT exam revealed facial dysmorphism, malformation of the right auricular pavilion with atresia of the external auditory canal and right nasal fossa malformation with deviated septum. The CT examination revealed a right orbit reduced in size, the right eyeball reduced in size with numerous annular calcifications, cleft lip and cleft palate, the area of the bone defect being occupied by soft tissue; flawed implanted dystrophic teeth; hypoplasia of the vertical and horizontal branch of the mandible; absence of the tympanic bone and the right external auditory canal; internal auditory canals, present semicircular ducts and complex vertebral malformations. Being a rare syndrome with many defects, early diagnosis is important, in order to apply appropriate treatment.

The reported incidence of Goldenhar syndrome ranges from 1: 3500 to 1: 5600 [1,2], with a male/female ratio of 3: 2 [1,6-8]. Abnormalities are unilateral in 85% of cases and bilateral in 10%-33% of cases [8]. Eye abnormalities occur in 60% of cases, vertebral abnormalities in 40% of cases, and ear abnormalities in 40% of cases [1]. The etiology of Goldenhar syndrome is unknown [1,9,10]. However, it is possible that abnormal embryonic vascular supply disrupted mesodermal migration, or some other factor lead to defective formation of the structures arising from the first and second branchial arches [1,9]. Most cases of Goldenhar syndrome are sporadic [1,5,9,10]. In the pathogenesis of the syndrome, the autosomal dominant, autosomal recessive and multifactorial modes of inheritance have been suggested [1,7,10]. Drugs, such as cocaine, thalidomide, retinoic acid, and tamoxifen ingested during pregnancy have also been suggested as etiologic factors [5,11]. Maternal diabetes and infections caused by rubella and influenza during pregnancy may be related to the development of this syndrome [8,12].

Patient and Methods

The 14 years old M.P. male patient is placed on the records of the Genetics Clinic of "Sf. Maria" Emergency Children's Hospital of Iassy, Romania, with the diagnosis of Goldenhar syndrome. The medical history indicated operated complete right cleft lip and cleft palate dehiscence at the age of 2 years old and it was then, that the suspicion for Goldenhar syndrome was harboured. The patient has no family history of congenital malformations. The patient's clinical examination evidenced ocular, auricular and vertebral malformations.

The Goldenhar Syndrome diagnosis in our patient was clinical. The patient's karyotype was performed in the Genetics Clinic in order to exclude an eventual chromosomal abnormality.

Introduction

Goldenhar syndrome is rare congenital defect characterized by complex craniofacial abnormalities associated with vertebral, cardiac, renal, central nervous system and gastrointestinal malformations [1,2]. It was described for the first time by the German Austrian ophthalmologist Carl Ferdinand Von Arlt in 1845 [1]. Almost a century later, in 1952, the French ophthalmologist Maurice Goldenhar characterized the syndrome by the triad: epibulbar limbal dermoids, periauricular appendage, and ear abnormalities [3]. In 1963, the American oral pathologist and geneticist Robert James Gorlin [4] added vertebral anomalies to this triad and suggested the name of oculo-auriculo-vertebral dysplasia for this condition. In medical literature this syndrome is also known as oculo-auriculo-vertebral spectrum, Goldenhar-Gorlin syndrome, and oculo-auriculo-vertebral dysplasia with hemifacial microsomia [5].

Results

The patient's physical examination revealed the microphthalmia of the right eyeball (Figure 1), the malformation of the right auricular pavilion (Figure 2), facial asymmetry, deviated septum, upper lip scar after operated complete right cleft lip and cleft palate dehiscence, flawed implanted dystrophic teeth (Figure 3).

The ophthalmological exam revealed the microphthalmia of the right eyeball and a low hypermetropia in the left eye. The ENT exam revealed facial dysmorphism, malformation of the right auricular pavilion with atresia of the external auditory canal and malformation of the right nasal fossa with deviated septum. The cardiologic exam did not reveal any structural and functional abnormalities. The renal ultrasound showed no changes. The laboratory analysis revealed the presence of a deficient hypocalcemia. The psychological consultation revealed a mild mental deficiency (global IQ of 50%) and dyslalia in the context of the disease. The result of the karyotype test had been normal (46,XY).

The CT examination revealed a right orbit reduced in size, the right eyeball reduced in size with numerous annular calcifications (Figure 4), cleft lip and cleft palate, the area of the bone defect being occupied by soft tissue (Figure 5); flawed implanted dystrophic teeth; hypoplasia of the vertical and horizontal branch of the mandible (Figure 6); absence of the tympanic bone and the right external auditory canal; internal auditory canals, present semicircular

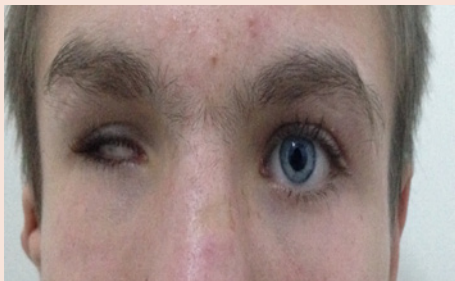

Figure 1: Right eye microphthalmia.

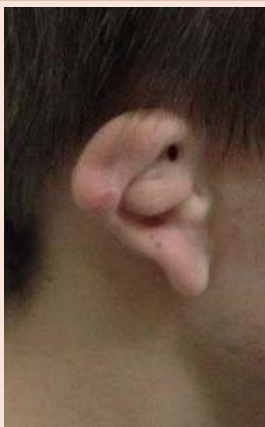

Figure 2: Malformation of the right auricular pavilion.

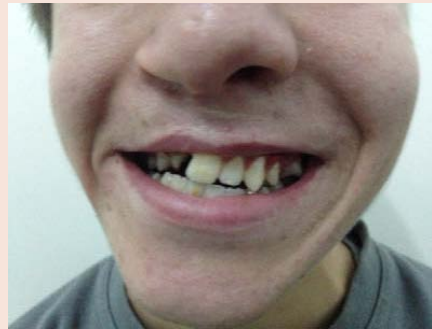

Figure 3: Facial asymmetry, nasal septum deviation, postoperative lip scar after lip and palatine cleft, flawed implanted dystrophic teeth.

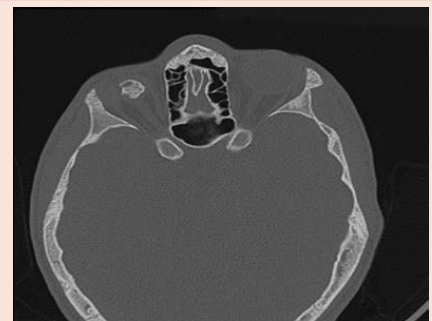

Figure 4: CT-axial imagine shows right eyeball reduced in size with numerous calcifications.

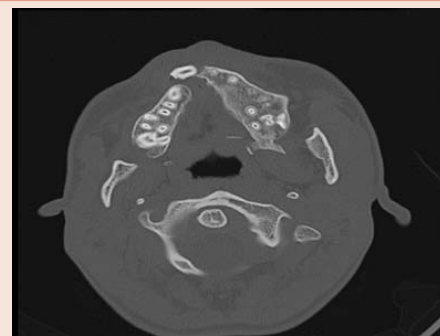


Figure 5: CT-axial imagine shows cleft lip and cleft palate.

ducts (Figure 7) and complex vertebral malformations (Figure 8) (dehiscence of the posterior arch C1 vertebra, complete congenital blocks between C2-C3 vertebrae and partial between C3-C4 vertebrae on the right and C4-C5 on the left at the level of the posterior bodies and arches, dehiscence of the posterior arch C4 vertebra whose right spine blade goes oblique and parallel to its spinous apophysis; hyperplasia of the blade and left vertebral pedicle at the level of C4 and C5 vertebrae).

Discussion

Our patient presented some classical signs of Goldenhar syndrome including facial asymmetry, microphthalmia, malformation of the

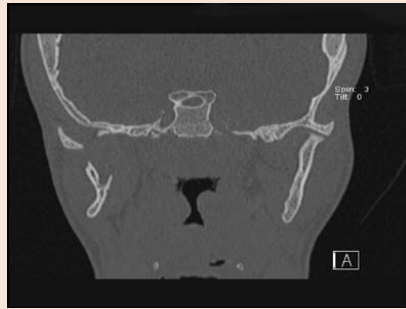


Figure 6: CT-coronal image shows hypoplasia of the vertical and horizontal branch of the mandible.

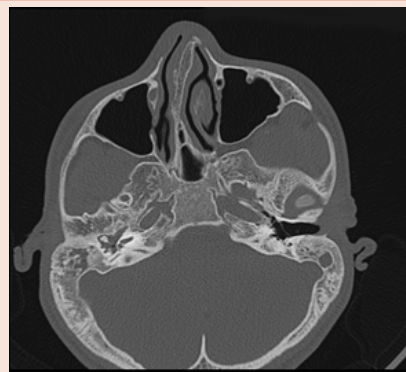


Figure 7: CT-axial image shows absence of the tympanic bone and the right external auditory canal.

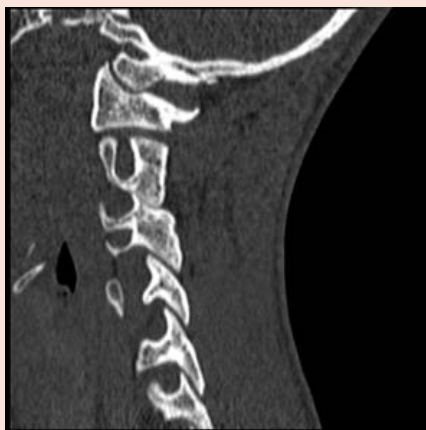

Figure 8: CT-coronal image shows complex cervical vertebral malformations.

right auricular pavilion with atresia of the external auditory canal, right nasal fossa malformation with deviated septum, and complex vertebral malformation without clinical expression. Ear abnormalities in Goldenhar syndrome include acrotia, microtia, preauricular tag, and auricular fistula [4,13,14]. Middle or inner ear abnormalities and the absence of external ear canal can cause conductive hearing loss in 50% of cases [14]. Our patient presented malformation of the right

auricular pavilion, absence of tympanic bone, atresia of the external auditory canal, internal auditory canals and present semicircular ducts.

Eye abnormalities in Goldenhar syndrome include anophthalmia, microphthalmia, eyelid and iris coloboma, epibulbar limbal dermoids, strabismus, and retinal abnormalities [1,4,5,15,16]. Our patient presented a right orbit reduced in size, microphthalmia with annular calcification in the right eye.

Oral manifestations of Goldenhar syndrome are numerous and range from malocclusion to complete absence of the mandibular branch and temporomandibular joint [17,18]. In the literature, there are case reports of Goldenhar syndrome associated with such oral malformations as micrognathia, macrostomia, cleft lip, cleft palate and fissured tongue [1,2,4,15,19]. Dental anomalies are represented by delayed tooth eruption, supernumerary teeth, and malocclusion. From all the oral manifestations of Goldenhar syndrome, our patient presented: cleft lip and cleft palate, the area of the bone defect being occupied by soft tissue; flawed implanted dystrophic teeth.

Facial asymmetry of patients with Goldenhar syndrome is caused by the incomplete development of malar bones, jaws, and temporomandibular joint [17,19]. This abnormality is associated with hypoplasia of facial muscles and is reported in 65-75% of cases [6,15,20]. The clinical facial aspect of Goldenhar syndrome patients is described as “hemifacial microsomia”, most frequently affecting the right side of the face [6,15]. Our patient had aspects of right facial asymmetry, due to the reduced size of the right orbit, septum deviation, cleft lip and cleft palate, hypoplasia of the vertical and horizontal branch of the mandible, atrophy of the right auricular pavilion.

The vertebral abnormalities associated with Goldenhar syndrome are supernumerary vertebrae, hemivertebrae, and fused vertebrae [14,17,19,21]. These abnormalities occur more commonly in the cervical spine. Sometimes they are associated with rib anomalies, scoliosis, kyphosis, and skull abnormalities [19,21]. Vertebral abnormalities occur in 40% to 60% of cases [8]. In our patient’s case, he has presented multiple cervical vertebral malformations, but without clinical expression.

Goldenhar syndrome may be associated with cardiovascular, pulmonary, renal, genital, central nervous system and gastrointestinal abnormalities [8,11,17,22,23]. We did not identify visceral malformations in our patient. According to literature data, most patients with Goldenhar syndrome have normal or low IQ for their age [19,23]. Psychological examination showed that our patient had a global IQ of 50%, found with an average intellectual disability and dyslalia in the context of disease.

In Goldenhar syndrome the genetic cause is not clear. In most cases this syndrome occurs sporadically, without an obvious cause [1,5,24,25]. However, familial cases have been reported, suggesting an autosomal dominant or autosomal recessive mode of inheritance. Chromosome abnormalities have been found in a few cases [24]. Other authors suggest a multifactorial inheritance, through the interaction of multiple genes with environmental factors [24,25]. Diabetes, ingestion of teratogenic drugs during pregnancy, exposure

to viruses or chemicals were also considered as etiological factors [11,12,26]. The mother of our patient had no history of diabetes, viral infections, alcohol consumption and exposure to teratogenic substances prenatally or intranatally.

The diagnosis of Goldenhar syndrome is made by physical and X-ray examination and laboratory tests [5,6,22,23]. Intranatal diagnosis can be confirmed ultrasonographically by the detection of abnormalities. Sometimes the diagnosis of Goldenhar syndrome can be difficult and or tardy [14,17]. Thus, Martelli Junior et al. (2010) [17] reported a mean age at the time of diagnosis of 7.15 years (ranges 3 months to 12 years). So, the diagnosis of Goldenhar syndrome is clinical, as there is no specific genetic defect described yet in this developmental disorder. However, we have performed a karyotype to exclude an eventual chromosomal abnormality and the result has been normal (46,XY).

Surgical treatment of this syndrome generally involves the surgical correction of facial cosmesis and improvement of hearing and sight loss. Also performed are cleft lip and palate surgical repair and surgical orthodontic reconstruction of dental malocclusion. The course and prognosis of Goldenhar syndrome may be favorable but depend on the severity of abnormalities.

Conclusions

Goldenhar syndrome is a rare condition characterized mostly by abnormalities of the face, eyes, ears, and spine. Patients have to be examined by a multidisciplinary team of specialists, in view of detecting the visceral anomalies, that may be associated with this syndrome. In Goldenhar syndrome early diagnosis, adequate management, and continued monitoring of the patient are very important to optimal long-term outcomes.

References

1. Kulkarni VV, Shah MD, Parikh AA (1985) Goldenhar syndrome (a case report). *J of Postgrad Med* 31: 177-179.
2. Oski FA, De Angelis CA, Feigin RD, Warshaw JB (1990) Síndromes comuns com anomalias morfológicas. *Princípios e Prática de Pediatria*. Rio de Janeiro: Guanabara Koogan 482.
3. Vinay C, Reddy RS, Uloopi KS, Madhuri V, Sekhar RC (2009) Craniofacial features in Goldenhar syndrome. *J Indian Soc Pedod Prev Dent* 27: 121-124.
4. Pinheiro ALB, Araujo LC, Oliveira SB, Sampaio MCC, Freitas AC (2003) Goldenhar's Syndrome-Case Report. *Braz Dent J* 14: 67-70.
5. Gaukar SP (2013) Goldenhar syndrome: A report a 3 cases. *Indian J Dermatol* 58: 244-248.
6. Rios JA (1998) Síndrome de Goldenhar- A propósito de um caso. *An Otorrinolaringol Iber Am XXV* 491-497.
7. Riyaz A, Riyaz N (1999) Goldenhar syndrome with unusual features. *Indian J Dermatol Venereol Leprol* 65: 143-144.
8. Kapur R, Kapur R, Sheikh S, Jindal S, Kulkarni S (2008) Hemifacial microsomia: A case report. *J Indian Soc Pedod Prev Dent* 26: 34-40.
9. Reddy MVV, Reddy PP, Usha RP, Hema BL (2005) Facio-auricular vertebral syndrome: a case Report. *Indian J Hum Genet* 11: 156-158.
10. Miller TD, Metry D (2004) Multiple accessory tragi as a clue to the diagnosis of the oculo-auriculo-vertebral (Goldenhar) syndrome. *J Am Acad Dermatol* 50: 11-13.
11. Lessick M, Vasa R, Israel J (1991) Severe manifestations of oculoauriculovertebral spectrum in a cocaine-exposed infant. *J Med Genet* 28: 803-804.
12. Araneta MR, Moore CA, Onley RS, Edmons LD, Karcher JA, et al. (1997) Goldenhar syndrome among infants born in military hospital to Gulf War veterans. *Teratology* 56: 244-251.
13. Setzer ES, Castaneda NR, Sevem C, Ryden S, Frias JL (1981) Etiologic heterogeneity in the oculoauriculovertebral syndrome. *J Pediatr* 98: 88-91.
14. Gorlin RJ, Cohen MM, Levin LS (1990) *Syndromes of the head and neck*. Oxford University Press, New York 1707-708.
15. Tasse C, Böhringer S, Fischer S, Lüdecke HJ, Albrecht B, et al. (2005) Oculo-auriculo-vertebral spectrum (OAVS): clinical evaluation and severity scoring of 53 patients and proposal for a new classification. *Eur J Med Genet* 48: 397-411.
16. Padaley JS, Patankar D, Meena HR (2014) Goldenhar syndrome. *Int J Contemp Pediatr* 1: 58-60.
17. Martelli-Junior H, Teixeira de Miranda R, Fernandes CM, Bonan PRF, Paranaíba LMR, et al. (2010) Goldenhar syndrome: clinical features with orofacial emphasis. *J Appl Oral Sci* 18: 646-649.
18. Vilki SK, Hukki J, Nietosvaara Y, Hurmerinta K, Suominen E (2002) Microvascular temporomandibular joint and mandibular ramus reconstruction in hemifacial microsomia. *J Craniofac Surg* 13: 809-815.
19. Shawky RM, Zahra SS (2011) Goldenhar syndrome with skin tags on the chest wall. *Egyptian J Med Hum Genet* 12: 217-220.
20. Hartsfield JK (2007) Review of the etiologic heterogeneity of the oculo-auriculo-vertebral spectrum (Hemifacial Microsomia). *Orthod Craniofac Res* 10: 121-128.
21. Feingold M, Baum J (1978) Goldenhar's Syndrome. *Am J Dis Child* 132: 136-138.
22. Nakajima H, Goto G, Tanaka N, Ashiya H, Ibukiyama C (1998) Goldenhar syndrome associated with various cardiovascular malformations. *Jpn Circ J* 62: 617-620.
23. Rodriguez JI, Palacios J, Lapunzina P (1993) Severe axial anomalies in the oculo-auriculo-vertebral (Goldenhar) complex. *Am J Med Genet* 47: 69-74.
24. Wilson GN, Barr M (1983) Trisomy 9 mosaicism: another etiology for the manifestations of Goldenhar Syndrome. *J Craniofac Genet Dev Biol* 3: 313-316.
25. Taysi K, Marsh JL, Wise DM (1983) Familial hemifacial microsomia. *Cleft Palate J* 20: 47-53.
26. Robinow M, Reynolds JF, Fitzgerald J, Bryant JA (1986) Hemifacial microsomia, ipsilateral facial palsy, and malformed auricle in two families: an autosomal dominant malformation. *Am J Med Genet* 2: 129-133.

Copyright: © 2015 Costea CF, et al. This is an open-access article distributed under the terms of the Creative Commons Attribution License, which permits unrestricted use, distribution, and reproduction in any medium, provided the original author and source are credited.

Citation: Costea CF, Rusu C, Ivănescu CG, Dumitraş S, Dimitriu G, et al. (2015) Goldenhar Syndrome. *J Clin Res Ophthalmol* 2(3): 041-044. DOI: 10.17352/2455-1414.000019