

Chandana Chakraborti^{1*}, Nabanita Barua², Sheuli Kumar³ and Rosy Chishti⁴

¹Department of Ophthalmology, Assistant Professor, Calcutta National Medical College and Hospital, West Bengal, India

²Department of Ophthalmology, RMO cum Clinical Tutor, Calcutta National Medical College and Hospital, West Bengal, India

³Department of Ophthalmology, RMO cum Clinical Tutor, Calcutta National Medical College and Hospital, West Bengal, India

⁴Department of Ophthalmology, PGT 1st year, Calcutta National Medical College and Hospital, West Bengal, India

Dates: Received: 29 October, 2014; Accepted: 21 March, 2015; Published: 23 March, 2015

*Corresponding author: Dr. Chandana Chakraborti, Assistant Professor, Department of Ophthalmology, Calcutta National Medical College and Hospital, Kolkata, West Bengal, India, Tel: 91-9830558243; 91-9830158243; E-mail: cchakoptha@yahoo.com

www.peertechz.com

Keywords: BIH; Complete blindness; Surgical management

ISSN: 2455-1414

Research Article

A Rare Case of Benign Intracranial Hypertension with Bilateral Complete Visual Loss and Sixth Nerve Paresis

Abstract

Introduction: Benign intracranial hypertension (BIH) is a disorder defined by symptoms and signs suggestive of increased intracranial pressure (ICP) in the absence of any cause evident on neuro-imaging or other evaluations. Usually the disease has a variable outcome but chances of severe visual loss are only 6%.

Methods: We report a case of 50 year old lady who presented to us with severe headache. Visual acuity was 20/20 both eyes. Anterior segment was within normal limit. Post segment evaluation revealed bilateral disc oedema. Thorough radiological and neurological examination confirmed diagnosis of Benign intracranial hypertension (BIH). We advised medical treatment and referred the patient to Neurology OPD for further management. She was lost to follow up to us for 4 months. She discontinued medicines in between. Her vision was 20/200 and fundus showed atrophic disc edema. We restarted previous medicines and referred to Neurology where she was admitted and managed conservatively. Finally she presented after 2 months with no perception of light both eyes. Examination revealed bilateral afferent pupillary defect and sixth nerve paresis. Fundus showed bilateral disc pallor.

Conclusion: Our endeavor is to document that BIH is not always benign condition. A multidisciplinary approach should be taken to look for early progression and appropriate intervention.

Abbreviations

BIH: Benign Intracranial Hypertension; ICP: Increased Intracranial Pressure

Introduction

Benign intracranial hypertension (BIH) is a disorder defined by modified Dandy's criteria that include symptoms and signs suggestive of increased intracranial pressure (ICP) (e.g. headache, transient visual obscurations, pulsatile tinnitus, papilledema, vision loss), no episode of impaired consciousness, normal cerebrospinal fluid composition, no other cause evident on neuro-imaging or other evaluations [1].

The name distinguishes it from secondary intracranial hypertension produced by a malignancy, venous thrombosis [2], bony and vascular malformations [3]. BIH in itself is not benign. Many patients suffer from incapacitating headache [4], nerve palsies [5] and severe visual loss⁶. We report a case of BIH where patient progressed to total blindness due to noncompliance to medical therapy.

Case Report

A 50 years old female, recently diagnosed to have diabetes and hypertension, presented to our Ophthalmology OPD, in tertiary care hospital with the presenting complain of severe headache for 1 month. Her height was 5'3", weight 80 kg. Her higher mental function and cranial nerve function were normal. All neurological examinations e.g. higher mental function, all cranial nerves from first to twelfth except second and sixth were normal. Locomotor system, sensory and motor examination of lower and upper limbs was normal. Visual

acuity was 20/20 both eyes. Anterior segment was within normal limit. Post segment evaluation with slit-lamp biomicroscope revealed bilateral disc oedema.

Neuroimaging studies excluded all intracranial space occupying lesion. CT scan showed chinked lateral ventricles. Renal, hepatic function and thyroid profile were normal. Urine analyses, serum Calcium were normal. VDRL was negative. CSF pressure was 280mm Hg with normal cytology and proteins. Automated perimetry was done which was within normal limit.

On the basis of all above mentioned investigations patient was diagnosed to have BIH. We advised weight reduction, tab. Diamox 500mg 4 times a day, T. Prednisolone 60 mg for 2 week and referred in Neuromedicine OPD for further management. They confirmed the diagnosis and continued the same medication.

She was lost to follow up to us for four months. She came with gradually progressive loss of vision. The vision recorded was 20/200 with accurate projection of rays both eyes. Pupils were sluggishly reacting with fundus picture of atrophic papilledema (Figure 1). We explained the need of regular follow up and restarted the medicine. She was admitted in Neurology OPD and managed conservatively. Repeat radiological evaluation was done. MRI images (Figure 2) were suggestive of choroidal ischemic foci. MR arteriography and venography was within normal limit. We advised DFA which showed bilateral disc leakage even in early frames with normal foveal zone. She was advised a close follow up at 2 weekly intervals.

She came after two months. Her complaint loss of vision over last 1 week. Her vision was no perception of light in both eyes.

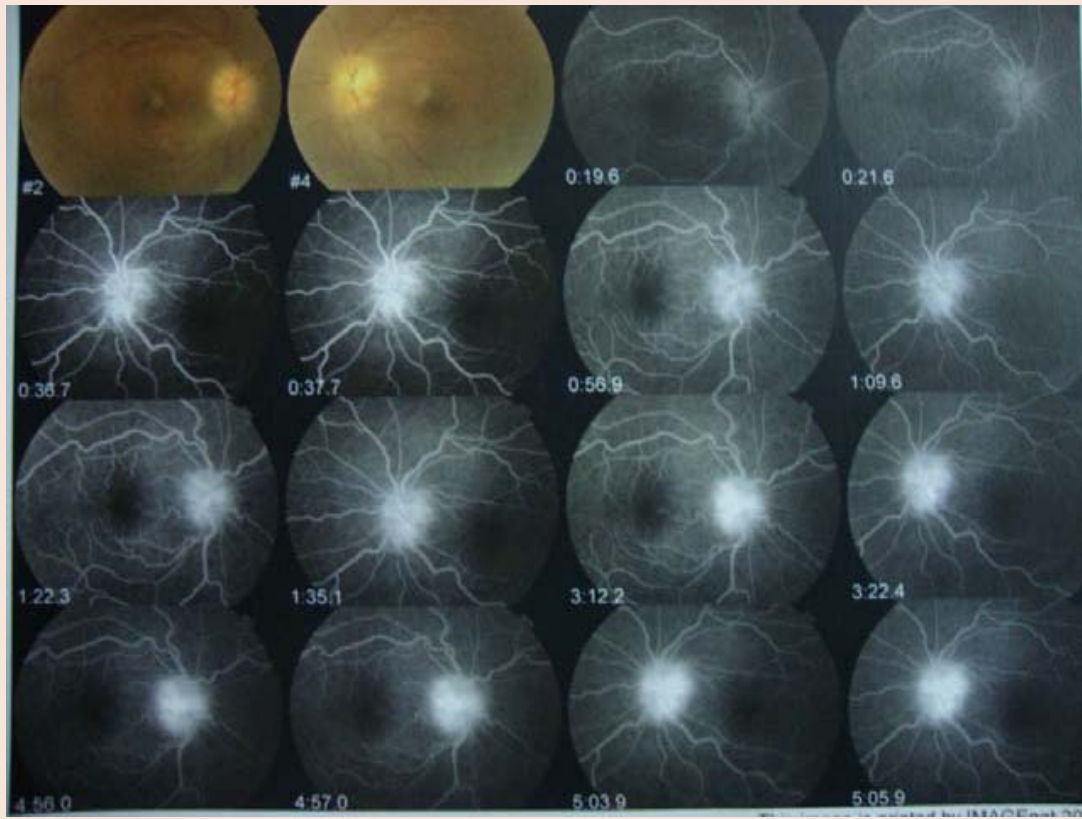


Figure 1: Fundus photograph showing atrophic papilledema. Dynamic Fluroscin Angiography showing disc leakage even in early frames.

Both pupils showed afferent pupillary defect. On examination of extraocular movement's abduction were restricted in both eyes (Figure 3a,3b). Fundus evaluation showed bilateral atrophic papilledema. Retrospectively we found patient took irregular treatment and neglected her symptoms. She took painkillers from local drug dispensing shop for her intermittent headache and used

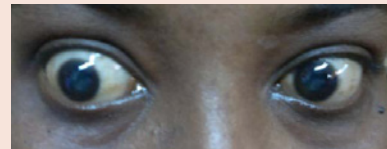

Figure 3a: Ocular movements in dextroversion.

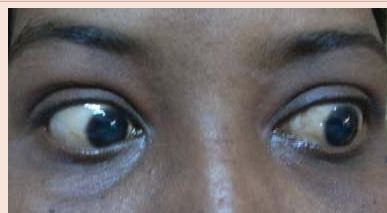

Figure 3b: Ocular movements in levoversion.

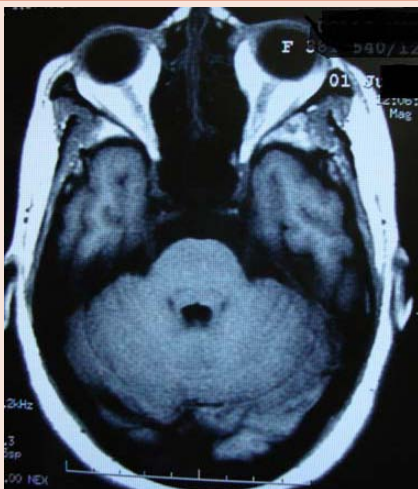


Figure 2: MRI Brain and orbit: Orbital section showing normal ocular scan.

spectacles. At this stage we advised systemic control only and referred back to Neurology OPD.

Discussion

BIH has highly unpredictable outcome lasting from few months to years. In 10% patients even after remission of the pappilledema,

symptoms might reappear weeks to many years after the first symptom [6].

In a prospective study done by Corbett et al in 57 patients with BIH, 49% had visual loss, of which 6% had severe loss⁶. We reviewed the literature and found multiple causative factors for severe visual loss such as high grade papilledema, progressive disease causing compression of papillomacular bundle, sub retinal neovascularisation, foveal hemorrhage, and high myopia, age more than 40 years, anemia, and atrophic papilledema [7].

Abducens nerve palsy is the commonest described abnormality seen in association with BIH. It has been accepted as a false localizing sign [5].

The treatment goal for patients with BIH is to preserve optic nerve function while managing ICP. Medical management is multifaceted. Optic nerve function should be carefully monitored. Weight control is recommended for obese patients. Specific therapy includes Carbonic anhydrase inhibitors and loop diuretics. Corticosteroids are indicated on a short-term basis when rapid lowering of ICP is required [8]. Headaches can often be controlled with commonly prescribed migraine prophylaxis agents. Stopping oral contraceptive pills, repeated lumbar punctures are other modalities.

In our patient the medical management was irregular and close ophthalmological follow up was lacking. BIH usually responds well to medical management. In unresponsive group, surgical options are lumbar puncture and optic nerve sheath fenestration [9]. The later effectively restores vision in 80–90% of patients creating an alternate channel for CSF drainage to restore axoplasmic flow. The indications are as follows: development of a new visual-field defect or enlargement of a previously existing field defect, presence of severe visual loss in one or both eyes at the time of first examination, hypotension induced by treatment of high blood pressure or renal dialysis, patient's inability to perform visual-field studies, headache unresponsive to conservative treatment. Lumboperitoneal shunt is an effective alternative in relieving intractable headache and papilledema [10] but it has many complications and is contraindicated in patients requiring subsequent abdominal surgery (e.g., renal transplantation). Reoperation is very often a rule.

In the present scenario of improved technology diagnosing BIH is

not much of a challenge; the treatment modality specially an effective and less complicating measure needs to be explored.

We report this case as there are only few such reports in literature. We emphasize that all patients of BIH should be followed up carefully with clinical examination and visual field, electrophysiology and neuroimaging studies when needed to avoid the dreaded complication of hyperacute /malignant BIH and a collaborated approach with neurologist, neurosurgeon, radiologist and ophthalmologists should be considered while dealing with this condition. Patients' primary caregiver should be informed about rare but probable grave prognosis of the disease and need for regular follow up.

References

1. Friedman DI, Jacobson DM (2002) Diagnostic criteria for idiopathic intracranial hypertension. *Neurology* 59: 1492-1495.
2. Sylaja PN, AhsanMoosa NV, Radhakrishnan K (2003) Differential diagnosis of patients with intracranial sinus venous thrombosis related isolated intracranial hypertension from those with idiopathic intracranial hypertension. *J Neurol Sci* 215: 9-12.
3. Cognard C, Casasco A, Toevi M (1998) Dural arteriovenous fistulas as a cause of intracranial hypertension due to impairment of cranial venous outflow. *J Neurol Neurosurg Psychiatry* 65: 308-316.
4. Friedman DI, Rausch EA (2002) Headache diagnoses in patients with treated idiopathic intracranial hypertension. *Neurology* 58: 1551-1553.
5. Quattrone A, Bono F, Fera F, Lavano A (2006) Isolated unilateral abducens palsy in idiopathic intracranial hypertension without papilledema. *Eur J Neurol* 13: 670-671.
6. Corbett JJ, Savino PJ, Thompson HS (1982) Visual loss in pseudotumor cerebri. Follow-up of 57 patients from five to 41 years and a profile of 14 patients with permanent severe visual loss. *Arch Neurol* 39: 461-474.
7. Morse PH, Leveille AS, Antel JP, Burch JV (1981) Bilateral juxta-papillary subretinal neovascularization associated with pseudotumor cerebri. *Am J Ophthalmol* 91: 312-317.
8. Orcutt JC, Page NGR, Sander D (1984) Factors Affecting Visual Loss in Benign intracranial Hypertension. *Ophthalmology* 91: 1303-1312.
9. Tang RA, Doratheo EU, Schiffman JS, Bahrani HM (2004) Medical and surgical management of idiopathic intracranial pressure in pregnancy. *Current Neurol Neuroscience Rep* 4: 398-409.
10. Lessell S (1992) Pediatric Pseudotumor cerebri (idiopathic intracranial hypertension). *Surv Ophthalmol* 37: 155-166.

Copyright: © 2015 Chakraborti C, et al. This is an open-access article distributed under the terms of the Creative Commons Attribution License, which permits unrestricted use, distribution, and reproduction in any medium, provided the original author and source are credited.

Citation: Chakraborti C, Barua N, Kumar S, Chishti R (2015) A Rare Case of Benign Intracranial Hypertension with Bilateral Complete Visual Loss and Sixth Nerve Paresis. *J Clin Res Ophthalmol* 2(3): 033-035. DOI: 10.17352/2455-1414.000017