

Teresa Papalia*, Rosita Greco, Agata Mollica and Renzo Bonofiglio

Nephrology, Dialysis and Transplantation
Department, Annunziata Hospital, Cosenza, Italy

Dates: Received: 20 March, 2016; Accepted: 25 April, 2016; Published: 26 April, 2016

*Corresponding author: Teresa Papalia,
Nephrology, Dialysis and Transplantation
Department, Annunziata Hospital,
Cosenza, Italy, Tel: +393405202652;
E-mail: teresapapalia@alice.it

www.peertechz.com

Review Article

Acute Renal Failure in Sarcoidosis: A Review of the Literature

Abstract

We report two cases of acute kidney failure (ARF) as the initial manifestation of sarcoidosis. Two patients were sent from their primary care physicians with hypercalcemia and progressive increase of serum creatinine. The renal biopsy revealed granulomatous interstitial nephritis (GIN). Both patients were started on Methylprednisolone pulse therapy, followed by administration of oral prednisolone and by a slow taper thereafter to a maintenance dose. The renal function has improved immediately in response to this therapy. Our cases demonstrate that GIN due to sarcoidosis, although a rare entity, can cause severe ARF and progressive ESRD. With early detection and appropriate therapy, the majority of patients will maintain adequate renal function. Therefore the diagnosis of renal sarcoidosis must be done quickly to prevent renal.

Case No 1

A 57-year-old Caucasian man is hospitalized in our Nephrology Department with progressive increase in serum creatinine (2.48 mg/dl; MDRD 32.6 ml/min) and proteinuria less than 500 mg/24h. The serum creatinine level was within normal range one year before this admission. He had a medical history of Hypertension, hearing loss and weight loss of twelve Kg. The hypertension had been present for 8 years, and was controlled with Amlodipine and Metoprolol. We did not rule any personal or family history of kidney disease, autoimmune disease, diabetes or cancer. The results of his physical examination were relatively unremarkable, except for moderate edema limited to lower extremities. His blood pressure was 140/85 mmHg. The renal echography was normal. We performed a renal biopsy. Light microscopy revealed non-caseating granulomatous tubulointerstitial nephritis with multinucleated giant and normal glomeruli (Figure 1). Furthermore foci of tubular atrophy and T-lymphocyte focal interstitial infiltration (Figure 1). Immunofluorescence studies were negative for Immunoglobulin (Ig) IgA, IgM, kappa, lambda, C1q and C3. Typical findings of sarcoidosis were found, e.g., hilar lymph node

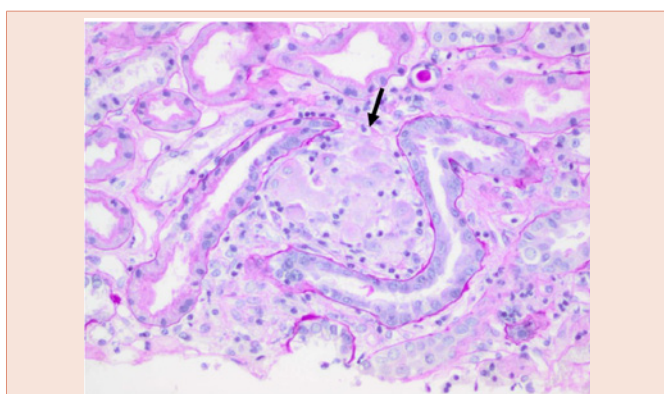


Figure 1: (Hematoxylin and Eosin). Diffuse interstitial inflammation from the area with granulomatous response (black arrow).

uptake on Computed tomography (CT) scan of this chest, elevated serum ACE level, hypercalcemia (12.3 mg/dL), splenomegaly, retinal degeneration, nonischemic cardiomyopathy with hypertrophy on echocardiography, no pathognomonic skin lesions. Serologic testing showed normal complement levels and negative results for anti-nuclear antibody, double-stranded DNA, antineutrophil cytoplasmic antibody (ANCA). The presence of hypercalcemia and very low PTHrP might be mistaken for Multiple Myeloma. Monoclonal Gammopathies were excluded by normal serum immunofixation, absent Bence Jones proteinuria and absent κ and λ free light chains (FLC). A skeletal survey showed no lytic or blastic osseous lesions.

Active tuberculosis, fungal infection, viral hepatitis, vasculitis and malignancy were clinically excluded.

The patient started with Methylprednisolone pulse therapy, followed by administration of oral prednisolone (1.0 mg/Kg/die) for 12 weeks and by a slow taper thereafter to a maintenance dose of 10 mg for an additional six months period. The renal function and hypercalcemia improved immediately in response to this therapy after one month. The follow up was marked by complete resolution of clinical and biological signs.

Case No 2

We report the case of a 53-year-old Caucasian woman presenting acute renal failure (ARF), proteinuria of 1.0 gr/24H, hypercalcemia and elevated 1.25 dihydroxycholecalciferol. She had reported the onset of fatigue, weight loss (about 12 Kg), arthralgia, loss of appetite a few months before hospital admission. The serum creatinine level has been documented to be 1.0 mg/dL two months before hospitalization. Her medical history included "rheumatica peliosis" when she was 22 years old, right pleurisy and erythematous maculopapular rash on her face when she was 24 years old, onset of Diabetes when she was 46 years old.

On admission on physical exam, the patient was febrile, normotensive and preserved diuresis (1800 mL/24H).

Upon admission, laboratory results showed creatinine of 4.7 mg/

dL; blood urea nitrose of 60 mg/dL, calcemia of 11,8 g/Dl, PTHi of 6 ng/L, white blood cell count of 6.800 mm³, normal level of ACE, AST and ALT. Urinalysis revealed 2+ proteinuria, 20 RBC/hpf and 40 WBC/hpf. CT scan of the chest without contrast was negative. Among the different etiologies of ARF with hypercalcemia we could exclude Hyperparathyroidism (suppress of PTHi); Multiple Myeloma (normal serum immunofixation, absent Bence Jones proteinuria and absent κ and λ FLC); malignancy with bone methastases. The patient underwent a renal biopsy. Light microscopy demonstrated relatively involved glomeruli and marked diffuse interstitial inflammatory composed of activated and rare eosinophils and neutrophils (polymorphonuclear cells) with frequent foreign body giant cells associated with non-caseating granulomas. There was moderate acute tubular injury and mild interstitial fibrosis. Granulomatous interstitial nephritis (GIN) was diagnosed. Negative serum Quantiferon testing for tuberculosis and negative special staining for acid-fas bacilli on urinary colture could exclude tuberculosis-induced GIN. In the last months our patient has never taken drugs as antimicrobials or analgesis (non-steroidal- anti-inflammatory drugs, NSAID) or Diuretics (hydrochlorothiazide and triamterene) or other medication. Viral hepatitis and vasculitis (negative ANCA and ANA, normal complement) were excluded. A glossy normal ocular exam and no simultaneous renal failure with uveitis could exclude Tinu Syndrome.

Moreover renal involvement with ARF, hypercalcemia resulting from increased 1.25 dihydroxyvitamin D₃ production by activated macrophages in areas of inflammation and exclusion of other causes of GIN allowed the diagnosis of sarcoidosis GIN.

The patient started with Methylprednisolone pulse therapy for three days, followed by administration of oral prednisolone (1.0 mg/Kg/die) for 12 weeks and by a slow taper thereafter to a maintenance dose of 10 mg for an additional six months period. The renal function has improved immediately in response to this therapy after two months. The follow up was marked by complete resolution of clinical and biological signs.

Introduction

Sarcoidosis, formerly called Mortimer's Malady, is a chronic multisystem disorder without any defined etiology. It is characterized by noncaseating granulomas in the affected organs or tissues. Its incidence varies from 3-4 to 35-80 per 100,000 according to ethnicity, region, and gender. Lymph nodes and lungs are the most frequently affected tissues, but sarcoidosis can also affect other organs and tissues like the skin, the central nervous system, the eyes, the muscles, the bones, the heart and the kidney. Although the incidence and prevalence of renal involvement in sarcoidosis remain uncertain clinically important renal involvement occasionally occurs in sarcoidosis [1]. Renal manifestations include abnormal calcium metabolism, nephrolithiasis and nephrocalcinosis, and acute interstitial nephritis with or without granuloma formation. Glomerular disease, obstructive uropathy, and end-stage renal disease (ESRD) may also occur, but are uncommon [2,3]. Renal biopsy is essential to identify the presence of noncaseating granulomatous interstitial nephritis.

Corticosteroids with or without immunosuppressants are the mainstay of therapy for Renal Sarcoidosis (RS). This review will summarize the epidemiologic, pathophysiologic, diagnostic, clinical, and therapeutic aspects of RS.

Epidemiology

Sarcoidosis can affect people of all racial and ethnic backgrounds and usually develops between 20 and 39 years of age [4]. The annual incidence varies throughout the world due to differences in environmental exposures, predisposing HLA alleles, and other genetic factors. The annual incidence among African Americans is three times more than among White Americans [4]. Sarcoidosis has an increase in mortality and morbidity among African Americans. Similarly, the Scandinavians have a higher prevalence of sarcoidosis than other Whites [5].

Sarcoidosis is said to have a slight sex preference since females between the ages of 20 and 40 have the highest incidence of Systemic Sarcoidosis (SS) [6,7].

Incidence and prevalence of renal involvement in sarcoidosis remain uncertain [8]. The reported prevalence ranges widely due to the enormous variation in study design and enrolled patient populations and also due to the heterogeneity and often asymptomatic nature of renal disease. Several small series have suggested that renal involvement occurs in approximately 35 to 50 percent of patients [8], even if, in most cases, the disease may be silent and undetected for many years or forever. Primary renal manifestations are nephrolithiasis and nephrocalcinosis and acute interstitial nephritis with or without granuloma formation. The nephrocalcinosis is estimated to occur in 5 percent of patients with sarcoidosis [9]. Nephrocalcinosis may be the most common cause of chronic kidney disease (CKD) [10]. Nephrolithiasis occurs in approximately 1 to 14 % of patients with sarcoidosis [11]. Interstitial nephritis with granuloma formation occurs in approximately 20 % of patients; however, renal insufficiency is not always present [12,13]. Patients who have interstitial nephritis may also have nephrolithiasis or nephrocalcinosis [14]. In one study that included a cohort of 27 patients with renal sarcoidosis (four of them with isolated renal involvement; the others with systemic sarcoidosis), the most commonly observed histologic lesion was nongranulomatous tubulointerstitial nephritis (44%), followed by granulomatous tubulointerstitial nephritis (30%), immunoglobulin A glomerulonephritis (IgAN 26%), and nephrocalcinosis (11%) [15]. Glomerular involvement is rare. A variety of different lesions have been described in isolated cases, including Membranous Nephropathy, IgAN, Minimal Change Disease, Proliferative or Crescentic Glomerulonephritis, and Focal Segmental Glomerulosclerosis [16,17].

Pathogenesis and etiologic factors

The etiology and pathophysiology of sarcoidosis has not been fully understood. The noncaseating epithelioid cell granuloma is the principal lesion found in organs affected by sarcoidosis [18]. These epithelioid cell granulomas consist of highly differentiated mononuclear phagocytes (epithelioid cells and giant cells) and lymphocytes [19]. Granuloma formation occurs as a result of a cell-mediated delayed hypersensitivity immune reaction in individuals

with immune dysfunction. After macrophages phagocytize the antigen, they present the antigen and effector CD4+helper T cells secrete IL-2 and IFN- γ that trigger a Th1 immune response. Non-necrotizing granuloma is formed as a result of the collection of highly differentiated mononuclear phagocytes (epithelioid cells and multinucleated giant cells), Schaumann bodies or asteroid bodies, patchy fibrosis, and lymphocytes [20]. Three categories of potential etiologic factors have previously been defined: infective, noninfective, and genetic [21]. Viruses (herpes, Epstein-Barr, retrovirus, coxsackie B virus, and cytomegalovirus), *Borrelia burgdorferi*, *Propionibacterium acnes*, *Mycobacterium tuberculosis* and other mycobacteria, *Mycoplasma orale*, beryllium, aluminum, zirconium, clay, talc, hairspray, pine tree pollen, peanut dust, mineral oil, and drugs (e.g. sulfonamide or methotrexate) can induce granulomaformation in genetically-predisposed individuals with abnormal immune responses [21]. The variability of disease presentation (pattern of disease, severity, and prognosis) among different races and in individuals with specific HLA sub-types and the presence of some familial clusters indicate a genetic susceptibility for sarcoidosis [7]. First degree relatives of patients with sarcoidosis were found to have a relative risk of sarcoidosis five times that of control subjects [7]. HLA analyses of affected families showed that inheritance of the risk for sarcoidosis can be polygenic, most commonly including the class I HLA-A1 and -B8 and class II HLADR3 genotypes [22-24]. Genetically predisposed individuals are likely to develop granulomas after exposure to antigens that trigger an exaggerated cellular immune response [18].

Clinical manifestations

Although the incidence of renal involvement in sarcoidosis remains uncertain, several studies have suggested that renal involvement occurs in approximately 35 to 50% of patients, even if, in most cases, the disease may be silent and go undetected for many years or forever [8]. Disorders related to calcium metabolism and electrolyte abnormalities are the most common renal symptom and observed among patients with sarcoidosis. The defect in calcium metabolism is due to extra renal production of calcitriol by activated macrophages. Manifestations of abnormal calcium metabolism include increased intestinal calcium absorption, hypercalciuria (which occurs in up to 50 percent of cases), hypercalcemia (which occurs in 10 to 20 percent), nephrocalcinosis, and nephrolithiasis. If untreated, renal calcium deposition can lead to chronic renal failure and end-stage renal disease. Nephrolithiasis may be the presenting feature of sarcoidosis [7]. In a retrospective study of 618 patients with sarcoidosis, renal calculi were the first manifestations in 14 of them (2.2%) [25]. The stones are usually of calcium oxalate, sometimes mixed with calcium phosphate. Patients with nephrocalcinosis may have polyuria, which is caused by hypercalcemia and possibly hypercalciuria, resulting in reduced responsiveness to antidiuretic hormone [26]. Polyuria in sarcoidosis may reflect central diabetes in *sipidus* (ie, lack of antidiuretic hormone) or primary polydipsia due to granulomatous infiltration of the hypothalamus [27]. The differential diagnosis of sarcoidosis-related nephrocalcinosis and nephrolithiasis includes conditions that cause hypercalcemia and hypercalciuria (primary hyperparathyroidism, vitamin D therapy, milk alkali syndrome, other granulomatous diseases, and congenital hypothyroidism) and conditions that cause hypercalciuria in the

absence of hypercalcemia (distal renal tubular acidosis, medullary sponge kidney, neonatal nephrocalcinosis and loop diuretics, inherited tubulopathies, and chronic hypokalemia). Although only 30 to 50 percent of patients with active sarcoidosis are hypercalciuric, abnormal calcitriol metabolism can be demonstrated in some who are normocalciuric and normocalcemic. As an example, increasing calcium intake appropriately lowers serum calcitriol concentrations in normal subjects but not in patients with sarcoidosis. Ca absorption is regulated by 1,25 (OH) $_2$ D, and serum values vary inversely with Ca intake. In sarcoidosis 1,25 (OH) $_2$ D is produced by alveolar macrophages in response to gamma-interferon, and patients may develop hypercalcemia after prolonged exposure to sunlight and increased dermal production of vitamin D3 [28]. Patients with sarcoidosis interstitial nephritis present with an elevated serum creatinine that is detected on routine screening or as part of their initial evaluation for sarcoidosis. Most patients have clear evidence of diffuse active sarcoidosis elsewhere. The urinalysis is usually normal or shows sterile pyuria or mild proteinuria. In a review of 52 cases of sarcoidosis interstitial nephritis, sterile pyuria, hematuria, glycosuria, and hypercalciuria were identified in 33, 21, 12, and 8%, respectively [9]. The diagnosis of sarcoidosis interstitial nephritis is strongly suggested by renal biopsy. Renal granulomatoses represent 0.5%-0.9% of nephropathies examined by renal biopsies. Granulomas can be isolated to the kidney or associated with other tissue involvement. Renal biopsy reveals normal glomeruli; interstitial infiltration, mostly with mononuclear cells; noncaseating granulomas in the interstitium; tubular injury; and, with more chronic disease, interstitial fibrosis. However, these findings are suggestions, but not diagnostic factors, of sarcoidosis. Among patients with interstitial nephritis, other conditions that must be considered include drug-induced interstitial nephritis, tuberculosis, other mycobacterium infections, granulomatosis with polyangiitis (Wegener's), brucellosis, histoplasmosis, tubulointerstitial nephritis with uveitis (TINU) syndrome, and, rarely, Crohn disease [29,30]. Occasionally, patients with renal sarcoidosis have no extra renal manifestations of sarcoidosis upon presentation. Thus, all patients who have granulomatous interstitial nephritis detected on biopsy should have a chest radiograph and pulmonary function tests and, if these are nondiagnostic, a high-resolution chest computed tomography (CT) scan to evaluate for pulmonary sarcoidosis. Patients with sarcoidosis occasionally present glomerulonephritis, although the mechanism of glomerular injury is not known, nor is the relationship to sarcoidosis proven [31]. Ureteral obstruction may result from retroperitoneal lymph node involvement, retroperitoneal fibrosis, renal stones, and direct ureteral involvement by sarcoid [3]. Retroperitoneal fibrosis can also involve the renal artery, which may be affected by sarcoid angiitis. When present, vasculitis of the renal artery is commonly associated with hypertension [32]. The recurrence in transplant recipients renal of renal sarcoidosis is not rare [33]. In one report, sarcoidosis recurred in five patients (27%), including two who had extra renal involvement and three who had renal involvement [34]. Recurrence was observed a median of 13 months after transplantation. Risk factors for recurrence included primary renal disease related to sarcoidosis and a shorter delay between the last episode of sarcoidosis and renal transplantation.

Diagnosis

The diagnosis of renal involvement in sarcoidosis is somewhat challenging because there is no single diagnostic test for sarcoidosis. Occasionally, patients with renal sarcoidosis have no extra renal manifestations of sarcoidosis upon presentation. Early diagnosis and prompt initiation of anti-inflammatory therapy is crucial to preventing poor outcomes. A comprehensive initial evaluation should be performed in all patients with suspected sarcoidosis.

The purpose of this initial evaluation is to obtain additional data supporting the diagnosis of sarcoidosis, while eliminating alternative diagnoses.

The diagnosis of sarcoidosis interstitial nephritis is suggested by renal biopsy, which shows an interstitial mononuclear infiltrate, noncaseating granulomas, tubular injury, and, with more chronic disease, interstitial fibrosis. These findings are suggestions, but not diagnostic factors, of sarcoidosis. A comprehensive evaluation should be performed in all patients with suspected sarcoidosis, including history, physical examination, a chest radiograph, pulmonary function tests, peripheral blood counts, serum chemistries, urinalysis, electrocardiogram, ophthalmologic examination, and a tuberculin skin test. The purpose of this evaluation is to obtain additional data supporting the diagnosis of sarcoidosis and to assess disease severity and extent, while eliminating alternative diagnoses. Thus, all patients who have granulomatous interstitial nephritis detected on biopsy should have a chest radiograph, pulmonary function tests, and, if these are nondiagnostic, a high-resolution chest computed tomography (CT) scan to evaluate for pulmonary sarcoidosis [18]. A variety of laboratory abnormalities may be seen in patients with sarcoidosis:

Anemia is uncommon. When present, it usually results from the anemia of chronic diseases, although hypersplenism, bone marrow involvement, or autoimmune hemolytic anemia can occur in some patients [35]. Leukopenia (5 to 10 %), eosinophilia (3 %) and thrombocytopenia (rare) can be seen [36].

The erythrocyte sedimentation rate is frequently elevated, but is not useful in assessing disease's activity.

C-reactive protein (CRP) is mildly elevated in about one-third of patients with sarcoidosis, but does not differentiate sarcoidosis from other causes of inflammation and shows only a variable correlation with fatigue among patients with sarcoidosis the relationship between CRP and the response to therapy is an area of further research [37]. Hypercalciuria is more commonly observed than hypercalcemia.

A moderate elevation in the serum alkaline phosphatase concentration suggests diffuse granulomatous hepatic involvement. Hypergammaglobulinemia (30 to 80 percent) and a positive rheumatoid factor may be present, but are not usually obtained. There are no disease-specific markers for diagnosis of RS. Although the serum angiotensin converting enzyme (ACE) level is elevated in 75% percent of untreated patients with sarcoidosis [38], ACE has limited utility as a diagnostic test, due to poor sensitivity (false negative results) and insufficient specificity (almost a 10 % rate of false positive results). Tissue levels of ACE are typically very high, but are not used

clinically. The value of monitoring the ACE level to assess the course of the disease remains unclear.

The tuberculin skin testing or an interferon gamma release assay is performed to help excluding *Mycobacterium tuberculosis* infection. Diminished skin test reactivity is expected in sarcoidosis, therefore a positive test is strong evidence in favor of mycobacterial disease.

Once the diagnosis of renal sarcoidosis is confirmed, the extent of involvement of other organs should be determined.

In addition to clinical and laboratory assessment for extrapulmonary sarcoidosis, all patients with a new diagnosis of sarcoid should have an electrocardiogram performed on them. Additional studies, such as 24 hour Holter monitoring and echocardiography, are performed based on symptoms, signs, and results of the electrocardiogram. These patients should also undergo visual acuity, tonometry, slit lamp, and fundoscopic testing to assess for ocular involvement. The differential diagnosis of sarcoidosis-related nephrocalcinosis and nephrolithiasis includes conditions that cause hypercalcemia and hypercalciuria (primary hyperparathyroidism, vitamin D therapy, milk alkali syndrome, other granulomatous diseases, and congenital hypothyroidism) and conditions that cause hypercalciuria in the absence of hypercalcemia (distal renal tubular acidosis, medullary sponge kidney, neonatal nephrocalcinosis and loop diuretics, inherited tubulopathies, and chronic hypokalemia).

Also, it is necessary to obtain serum testing for vitamin D deficiency by measuring both 25-hydroxyvitamin D (calcidiol) and 1,25-dihydroxyvitamin D [39]. Deficiency of 25-hydroxyvitamin D is nearly universal among patients with sarcoidosis, although 1,25-dihydroxyvitamin D is sufficient in 70 percent of cases. For patients with an elevated serum calcium, a 24-hour urine sample is obtained to assess urinary calcium excretion and creatinine clearance. If the urinalysis shows protein, then urinary protein is also assessed in the 24-hour specimen. A definitive diagnostic test for sarcoidosis does not exist. The diagnosis of sarcoidosis requires three elements: Compatible clinical and radiographic manifestations, exclusion of other diseases that may present similarly and histopathologic detection of noncaseating granulomas. The diagnosis of sarcoidosis interstitial nephritis is suggested by renal biopsy, which shows an interstitial mononuclear infiltrate, noncaseating granulomas, tubular injury, and, with more chronic disease, interstitial fibrosis. Biopsy should be performed in most cases of suspected sarcoidosis as both the incidence and the prevalence of renal involvement in sarcoidosis remain still uncertain.

Prognosis, therapy and follow-up

Prognosis: Although end-stage renal disease (ESRD) requiring some form of renal replacement therapy is uncommon, the sarcoidosis cannot necessarily be considered a benign nephrologic condition. ESRD is most often due to hypercalcemic nephropathy rather than granulomatous nephritis or a glomerulonephropathy, some studies have shown that granulomatous tubulointerstitial nephritis is also associated with acute renal failure and may lead to hemodialysis. In the largest observational study, among 46 patients with sarcoidosis-related interstitial nephritis, only two progressed to ESRD (at 15 and 2 years after presentation) [40], although 66 % of patients had

an estimated glomerular filtration rate (eGFR) <60 mL/min/1.73 m² at a median follow-up of 24 months. The prognosis is worse in blacks, the elderly, and those patients who fail to respond to steroids or have extensive multi-organ involvement. The prognosis of this condition, like its natural history, is variable. The presence of scarring within the kidney carries a less favorable prognosis. Hypercalcemia may also cause a decreased glomerular filtration rate (GFR) through preglomerular arteriolar vasoconstriction [41].

Therapy and Follow-up: Corticosteroids are the mainstay of treatment for sarcoid GIN [42]. Initial treatment requires a daily dose of prednisone or prednisolone preferably 1mg/kg/day. In symptomatic cases, steroids are highly effective in suppressing the cellular inflammatory reaction of sarcoidosis and in reversing most forms of organ dysfunction caused by granulomatous infiltration. The best response to glucocorticoids was noted in a study by Mahevas et al. [40], in which 47 patients with renal sarcoid received prednisolone while 10 also received pulse methylprednisolone. The authors concluded that at the 24th month, a complete and partial remission had occurred in 30 and 5 patients respectively. But no response was noted in patients with severe interstitial fibrosis of greater than 50%. Underlying functional tubular dysfunction improves with progressive drop in serum creatinine. The presence of hypercalcemia on presentation correlated with a complete response to glucocorticoid therapy at one year. There are limited data to guide glucocorticoid therapy. We suggest oral prednisone 1 mg/kg/day for 6 to 12 weeks, followed by a slow taper thereafter to a maintenance dose of 10 to 20 mg for an additional six to nine months. The steroid treatment has to be prolonged and must be continued for at least 6 months as nephropathy relapses very frequently with short term therapy [43]. Unfortunately, these patients are at higher risk of relapse after steroid withdrawal and often require a longer course of corticosteroid therapy. Close monitoring of patients is therefore essential during tapering and after discontinuation of steroid therapy, because 25% of treated patients experience relapse. Long term use of corticosteroids, especially in adolescents, can cause substantial side effects including diabetes, growth retardation and cataract. Alternative agents that have been attempted in treating sarcoid GIN include mycophenolate [44] and mizoribine [45,46], which are limited to case reports and have been primarily used in pediatric patients to break steroid dependence or ameliorate significant side effects. There has been great interest in the use of TNF-antagonists as another modality to treat sarcoid GIN in order to avoid use of steroids. TNF-alpha, which is expressed by monocytes, is critical in the development of these noncaseating granulomas.

TNF-alpha receptor antagonists have also been shown to prevent the initiation and perpetuation of inflammation and subsequent interstitial fibrosis. Etanercept is a soluble TNF-alpha receptor fusion protein that binds TNF-alpha. Infliximab and adalimumab are monoclonal antibodies that bind specifically to and neutralize TNF-alpha. While etanercept is an ineffective agent in the treatment of systemic sarcoidosis [47], infliximab has been shown to be effective in a case of renal sarcoid. Although adalimumab and infliximab are generally safe, some side effects include risk of lymphoma and reactivation of latent tuberculosis [48]. These agents may hold promise for future research once large scale randomized studies

are available to show consistent benefits with minimal side effects. Other drugs that have been used in cases unresponsive to steroids are methotrexate, chloroquine, azathioprine, and cyclophosphamide. Of these, methotrexate seems to be more effective.

For patients who occasionally present with glomerulonephritis, as in other forms of sarcoid nephropathy, the administration of steroids appears to improve renal function [49,50]. Treatment of the hypercalcemia or hypercalciuria in granulomatous disorders is aimed at treatment of the underlying disorder. In addition, treatment of hypercalcemia or hypercalciuria includes reducing intestinal calcium absorption and calcitriol synthesis. These can be achieved by reducing calcium intake (no more than 400 mg/day), reducing oxalate intake, elimination of dietary vitamin D supplements, and avoidance of sun exposure. In addition to dietary measures, low-dose glucocorticoid therapy (10 to 30 mg/day of prednisone) is typically used to treat sarcoidosis [49].

Conclusions

With early detection and appropriate therapy, the majority of patients will maintain adequate renal function provided they follow medical advice carefully. Therefore the diagnosis of renal sarcoidosis must be done quickly to prevent renal failure. Also reported on the works the key prognostic factor for renal survival in RS is the early response to treatment.

References

- Berger KW, Relman AS (1955) Renal impairment due to sarcoid infiltration of the kidney; report of a case proved by renal biopsies before and after treatment with cortisone. *N Engl J Med* 252: 44-49.
- Muther RS, McCarron DA, Bennett WM (1981) Renal manifestations of sarcoidosis. *Arch Intern Med* 141: 643-645.
- Casella FJ, Allon M (1993) The kidney in sarcoidosis. *J Am Soc Nephrol* 3: 1555-1562.
- Rybicki BA, Major M, Popovich J Jr, Maliarik MJ, Iannuzzi MC (1997) Racial differences in sarcoidosis incidence: A 5-year study in a health maintenance organization. *Am J Epidemiol* 145: 234-241.
- Mirsaeidi M, Machado RF, Schraufnagel D, Sweiss NJ, Baughman RP (2015) Racial difference in sarcoidosis mortality in the United States. *Chest* 147: 438-449.
- Lee LS, Rose CS, Maier LA (1997) Sarcoidosis. *N Engl J Med* 336: 1224-1234.
- Lebacqz E, Desmet V, Verhaegen H (1970) Renal involvement in sarcoidosis. *Postgrad Med J* 46: 526.
- Bergner R, Hoffmann M, Waldherr R, Uppenkamp M (2003) Frequency of kidney disease in chronic sarcoidosis. *Sarcoidosis Vasc Diffuse Lung Dis* 20: 126-132.
- Berliner AR, Haas M, Choi MJ (2006) Sarcoidosis: the nephrologist's perspective. *Am J Kidney Dis* 48: 856-870.
- Singer FR, Adams JS (1986) Abnormal calcium homeostasis in sarcoidosis. *N Engl J Med* 315: 755-757.
- Rizzato G (1992) Sarcoidosis in Italy. *Sarcoidosis* 9: 145.
- Singer DR, Evans DJ (1986) Renal impairment in sarcoidosis: granulomatous nephritis as an isolated cause (two case reports and review of the literature). *Clin Nephrol* 26: 250-256.
- Joss N, Morris S, Young B, Geddes C (2007) Granulomatous interstitial nephritis. *Clin J Am Soc Nephrol* 2: 222-230.

14. Mahévas M, Lescure FX, Boffa JJ, Delastour V, Belenfant X, et al. (2009) Renal sarcoidosis: clinical, laboratory, and histologic presentation and outcome in 47 patients. *Medicine (Baltimore)* 88: 98-106.
15. Löffler U, Tuleweit A, Waldherr R, Uppenkamp M, Bergner R (2015) Renal Sarcoidosis: epidemiological and follow-up data in a cohort of 27 patients. *Sarcoidosis Vasc Diffuse Lung Dis* 31: 306-315.
16. Dahl K, Canetta PA, D'Agati VD, Radhakrishnan J (2008) A 56-year-old woman with sarcoidosis and acute renal failure. *Kidney Int* 74: 817.
17. Van Uum SH, Cooreman MP, Assmann KJ, Wetzels JF (1997) A 58-year-old man with sarcoidosis complicated by focal crescentic glomerulonephritis. *Nephrol Dial Transplant* 12: 2703-2707.
18. (1999) Statement on sarcoidosis. Joint Statement of the American Thoracic Society (ATS), the European Respiratory Society (ERS) and the World Association of Sarcoidosis and Other Granulomatous Disorders (WASOG) adopted by the ATS Board of Directors and by the ERS Executive Committee, February 1999. *Am J Respir Crit Care Med* 160: 736-755.
19. Barnard J, Newman LS (2001) Sarcoidosis: Immunology, rheumatic involvement, and therapeutics. *Curr Opin Rheumatol* 13: 84-91.
20. Sehgal VN, Riyaz N, Chatterjee KK, Venkatas P, Sharma S (2014) Sarcoidosis as a systemic disease. *Clin Dermatol* 32: 351-363.
21. Hance AJ (1998) The role of mycobacteria in the pathogenesis of sarcoidosis. *Semin Respir Infect* 13: 197-205.
22. Naruse TK, Matsuzawa Y, Ota M, Katsuyama Y, Matsumori A, et al. (2000) HLA-DQB1*0601 is primarily associated with the susceptibility to cardiac sarcoidosis. *Tissue Antigens* 56: 52-57.
23. Takashige N, Naruse TK, Matsumori A, Hara M, Nagai S, et al. (1999) Genetic polymorphisms at the tumour necrosis factor loci (TNFA and TNFB) in cardiac sarcoidosis. *Tissue Antigens* 54: 191-193.
24. Lenhart K, Kolek V, Bártova A (1990) HLA antigens associated with sarcoidosis. *Dis Markers* 8: 23-29.
25. Rizzato G, Fraioli P, Montemurro L (1995) Nephrolithiasis as a presenting feature of chronic sarcoidosis. *Thorax* 50: 555-559.
26. Procino G, Mastrofrancesco L, Tamma G, Lasorsa DR, Ranieri M, et al. (2012) Calcium-sensing receptor and aquaporin 2 interplay in hypercalciuria-associated renal concentrating defect in humans. An in vivo and in vitro study. *PLoS One* 7: e33145.
27. Stuart CA, Neelon FA, Lebovitz HE (1980) Disordered control of thirst in hypothalamic-pituitary sarcoidosis. *N Engl J Med* 303: 1078-1082.
28. Basile JN, Liel Y, Shary J, Bell NH (1993) Increased calcium intake does not suppress circulating 1,25-dihydroxyvitamin D in normocalcemic patients with sarcoidosis. *J Clin Invest* 91: 1396-1398.
29. Javaud N, Belenfant X, Stirnemann J, Laederich J, Zioli M, et al. (2007) Renal granulomatoses: a retrospective study of 40 cases and review of the literature. *Medicine (Baltimore)* 86: 170-180.
30. Adams AL, Cook WJ (2007) Granulomatous interstitial nephritis secondary to histoplasmosis. *Am J Kidney Dis* 50: 681-685.
31. Jones B, Fowler J (1989) Membranous nephropathy associated with sarcoidosis. Response to prednisolone. *Nephron* 52: 101-102.
32. Gross KR, Malleson PN, Culham G, Lirenman DS, McCormick AQ, et al. (1986) Vasculopathy with renal artery stenosis in a child with sarcoidosis. *J Pediatr* 108: 1724-1726.
33. Mann DM, Fyfe B, Osband AJ, Lebowitz J, Laskow DA, et al. (2013) Sarcoidosis within a renal allograft: a case report and review of the literature. *Transplant Proc* 45: 838-841.
34. Aouizerate J, Matignon M, Kamar N, Thervet E, Randoux C, et al. (2010) Renal transplantation in patients with sarcoidosis: a French Multicentric study. *Clin J Am Soc Nephrol* 5: 2101-2108.
35. Lower EE, Smith JT, Martelo OJ, Baughman RP (1998) The anemia of sarcoidosis. *Sarcoidosis* 5: 51-55.
36. Renston JP, Goldman ES, Hsu RM, Tomashefski JF Jr. (2000) Peripheral blood eosinophilic association with sarcoidosis. *Mayo Clin Proc* 75: 586-590.
37. Sweiss NJ, Barnathan ES, Lo K, Judson MA, Baughman R (2010) T48 Investigators. C-reactive protein predicts response to infliximab in patients with chronic sarcoidosis. *Sarcoidosis Vasc Diffuse Lung Dis* 27: 49-56.
38. Study PR, Bird R (1989) Serum angiotensin converting enzyme in sarcoidosis-its value in present clinical practice. *Ann Clin Biochem* 26: 13-18.
39. Judson MA, Baughman RP, Teirstein AS, Terrin ML, Yeager H Jr. (1999) Defining organ involvement in sarcoidosis: the ACCESS proposed instrument. ACCESS Research Group. A Case Control Etiologic Study of Sarcoidosis. *Sarcoidosis Vasc Diffuse Lung Dis* 16: 75-86.
40. Mahévas M, Lescure FX, Boffa JJ, Delastour V, Belenfant X, et al. (2009) Renal sarcoidosis: clinical, laboratory, and histologic presentation and outcome in 47 patients. *Medicine (Baltimore)* 88: 98-106.
41. Levi M, Peterson L, Berl T (1983) Mechanism of concentrating defect in hypercalcemia. Role of polydipsia and prostaglandins. *Kidney Int* 23: 489-497.
42. Iannuzzi MC, Fontana JR (2011) Sarcoidosis: Clinical Presentation Immunopathogenesis, and Therapeutics. *JAMA* 305: 391-399.
43. O'Riordan E, Willert RP, Reeve R, Kalra PA, O'Donoghue DJ, et al. (2001) Isolated sarcoid granulomatous interstitial nephritis: review of five cases at one center. *Clin Nephrol* 55: 297-302.
44. Moudgil A, Przygodzki RM, Kher KK (2006) Successful steroid-sparing treatment of renal limited sarcoidosis with mycophenolate mofetil. *Pediatric Nephrol* 21: 281-285.
45. Ito S, Harada T, Nakamura T, Imagawa T, Nagahama K, et al. (2009) Mizoribine for renal sarcoidosis: effective steroid tapering and prevention of recurrence. *Pediatr Nephrol* 24: 411-414.
46. Rajakariar R, Sharples EJ, Raftery MJ, Sheaff M, Yaqoob MM (2006) Sarcoid tubulo-interstitial nephritis: Long-term outcome and response to corticosteroid therapy. *Kid Int* 70: 165-169.
47. Utz JP, Limper AH, Kalra S, Specks U, Scott JP, et al. (2003) Etanercept for the treatment of stage II and III progressive pulmonary sarcoidosis. *Chest* 124: 177-185.
48. Denys BG, Bogaerts Y, Coenegrachts KL, De Vriese AS (2007) Steroid-resistant sarcoidosis: is antagonism of TNF- α the answer? *Clinical Science* 11: 281-289.
49. Seymour JF, Gagel RF (1993) Calcitriol: the major humoral mediator of hypercalcemia in Hodgkin's disease and non-Hodgkin's lymphomas. *Blood* 82: 1383-1394.
50. Papalia T, Greco R, Mollica F, Cassani S, Bonfiglio R (2007) Acute renal failure in granulomatous interstitial nephritis. *G Ital Nefrol* 24: 333-337.

Copyright: © 2016 Papalia T, et al. This is an open-access article distributed under the terms of the Creative Commons Attribution License, which permits unrestricted use, distribution, and reproduction in any medium, provided the original author and source are credited.

Citation: Papalia T, Greco R, Mollica A, Bonfiglio R (2016) Acute Renal Failure in Sarcoidosis: A Review of the Literature. *Arch Clin Nephrol* 2(1): 011-016.