

Case Report

Negative Pressure Treatment for Abdominal Wall Pseudotumor Due to Fishbone Perforation

Alassiri A¹, Paolino L¹, Martini F¹, Droz J¹, Livideanu C^{2*} and Fritsch S¹

¹Minimally Invasive Surgical Department, Joseph Ducuing Hospital, 15 rue Varsovie, 31027 Toulouse, France

²Radiology Department, Joseph Ducuing Hospital, 15 rue Varsovie, 31027 Toulouse, France

*Corresponding author: Dr. Luca Paolino, Minimally Invasive Surgical Department, Joseph Ducuing Hospital, 15 rue Varsovie, 31027 Toulouse, France, Tel: +330561773435; Fax: +330561773470; E-mail: lpaolino@hotmail.com

Received: 13 December, 2015; Accepted: 13 January, 2016; Published: 25 January, 2016

Introduction

The inadvertent swallowing of foreign bodies is common, but results in perforation of the gastrointestinal tract in less than 1% of cases [1]. Because any site of the gastrointestinal tract may be perforated by a foreign body, the clinical presentation may vary and mimic diverse medical conditions.

Presentation may be early in the form of peritonitis or late in the form of intra-abdominal abscess. Up to date no case of abdominal wall abscess was reported.

Herein we describe the clinical history of a 60 year-old man presenting with an abdominal wall pseudo tumor due to accidental fishbone ingestion occurred 8 months before. After surgical drainage of the abscess, negative pressure wound therapy (NPWT) was used with excellent results.

Clinical Case

A 60 year-old man presented to the emergency department with a gradually enlarging supraumbilical lump. Lump volume had progressively increased over 8 months and a slight pain appeared 7 days before, in the absence of fever or any gastrointestinal symptom. No trauma was reported. On physical examination, an oval 10 cm mass was palpable which was firm, slightly tender and fixed to the abdominal wall. The skin overlying the swelling was normal.

Blood tests revealed severe hyper leukocytosis and high level of C-reactive protein. CT-scan showed 8 cm abscess deeply situated inside the rectus muscle, in contact with the transverse colon (Figure 1A). A hyper dense line could be detected in the middle of the abscess, suggesting a foreign body (Figure 1B). A complete colonoscopy was performed which showed no lesion.

After 48 hours of antibiotic treatment, a surgical exploration was performed, showing an abscess around a fishbone, situated deeply in the abdominal wall. Approximately 30 ml of purulent liquid were aspirated and the fishbone extracted. Abscess cavity was covered by a hemorrhagic, thick granulation tissue (Figure 2A). Multiple intraoperative biopsies were performed which showed no sign of malignancy. NPWT (VAC®, KCI inc, France) was applied (Figure 2B). Following an intraoperative bleeding of about 700 ml,

2 red blood cell units were transfused in the postoperative period. Postoperative course was uneventful and the patient was discharged on postoperative day 4. Wound care was provided at home by a nurse. NPWT was applied during 4 weeks and complete healing was achieved in 10 weeks with a good quality scar tissue (Figure 2C).

Definitive histology on abscess wall tissue showed a foreign body granuloma. When the patient was said about the fishbone perforation, he was able to remember he had accidentally swallowed a fishbone 8 months before, just some days before the lump appeared.

Discussion

The great majority of ingested foreign bodies pass spontaneously through the gastrointestinal tract within 1 week [1], while 10-20% require endoscopic removal and less than 1% require surgery [2].

Clinical presentation may be early in the form of peritonitis or

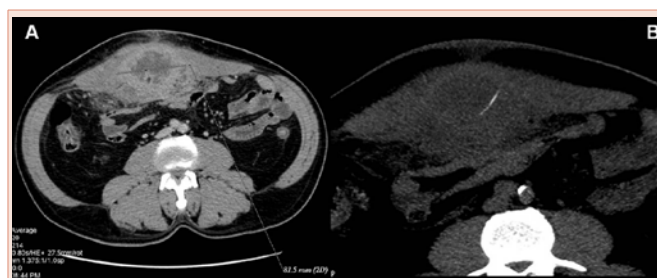

Figure 1

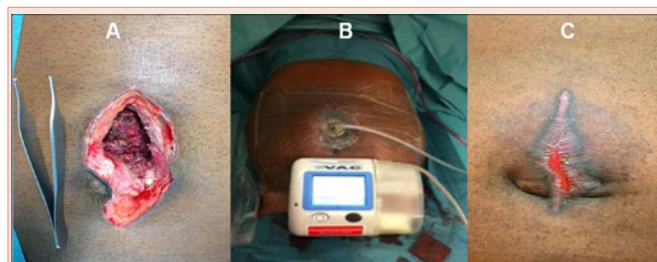


Figure 2



late in the form of intra-abdominal abscess. Chiu et al. described a case of transverse colon perforation by a fishbone 4 weeks after ingestion with the development of an intra-abdominal abscess [3].

We report the case of a transverse colon perforation by a fishbone with a very late clinical presentation as abdominal wall pseudo tumor.

Pseudo tumor is a term used to describe a benign mass of inflammatory origin mimicking a neoplastic process. Pseudo tumors can be found in nearly every site in the body. Concerning the abdominal wall, they are usually infectious origin such as in case of actinomycosis [4] and cysticercosis [5]. Another cause can be infected foreign bodies such as hernia meshes, retrieved surgical gauzes, etc...

Concerning NPWT, it was introduced about 20 years ago and has progressively gained popularity among the surgical community. Nowadays it is commonly used for several kinds of complicated wounds, especially in case of infection. NPWT promotes wound healing by delivering negative pressure at the wound site through a foam dressing, this helps draw wound edges together, remove infectious materials and actively promote granulation.

Therefore it represents a wall preserving solution for infected wounds with large tissue defects as the one we met in this case [6].

Conclusions

Abdominal wall pseudo tumor represents an uncommon clinical presentation of colon perforation by a fishbone. After surgical drainage of the parietal abscess, NPWT represents the ideal solution for an infected wound with such a large tissue defect.

References

1. Webb WA (1995) Management of foreign bodies of the upper gastrointestinal tract: update. *Gastrointest Endosc* 41: 39-51.
2. Strauss JE, Balthazar EJ, Naidich DP (1985) Jejunal perforation by a toothpick: CT demonstration. *J Comput Assist Tomogr* 9: 812-814.
3. Chiu JJ, Chen TL, Zhan YL (2009) Perforation of the transverse colon by a fish bone: a case report. *J Emerg Med* 3: 345-347.
4. Carkman S, Ozben V, Durak H, Karabulut K, Ipek T (2010) Isolated Abdominal Wall Actinomycosis Associated with an Intrauterine Contraceptive Device: A Case Report and Review of the Relevant Literature. *Case Rep Med* pii: 340109.
5. Badar F, Yasmeen S, Azfar SF, Kirmani S, Ahmed I (2011) Isolated cysticercosis of internal oblique muscle: a rare cause of abdominal wall pseudotumor. *Pakistan Journal of Radiology* 21: 180-181.
6. Hutan M, Bartko C, Majesky I, Prochotsky A, Sekac J, et al. (2014) Reconstruction option of abdominal wounds with large tissue defects. *BMC Surg* 14: 50.

Copyright: ©2016 Paolino L, et al. This is an open-access article distributed under the terms of the Creative Commons Attribution License, which permits unrestricted use, distribution, and reproduction in any medium, provided the original author and source are credited.

Citation: Alassiri A, Paolino L, Martini F, Droz J, Livideanu C, Fritsch S (2016) Negative Pressure Treatment for Abdominal Wall Pseudotumor Due to Fishbone Perforation. *Imaging J Clin Med Sciences* 3(1): 002-003. DOI: 10.17352/2455-8702.000022