

Clinical Image

Giant renal Cyst into Giant Laparotomic Hernia

Francisco Javier Pérez Lara*, David Hernández Alcaraz, Juan Hernández Carmona, Arturo del Rey Moreno and Horacio Oliva Muñoz

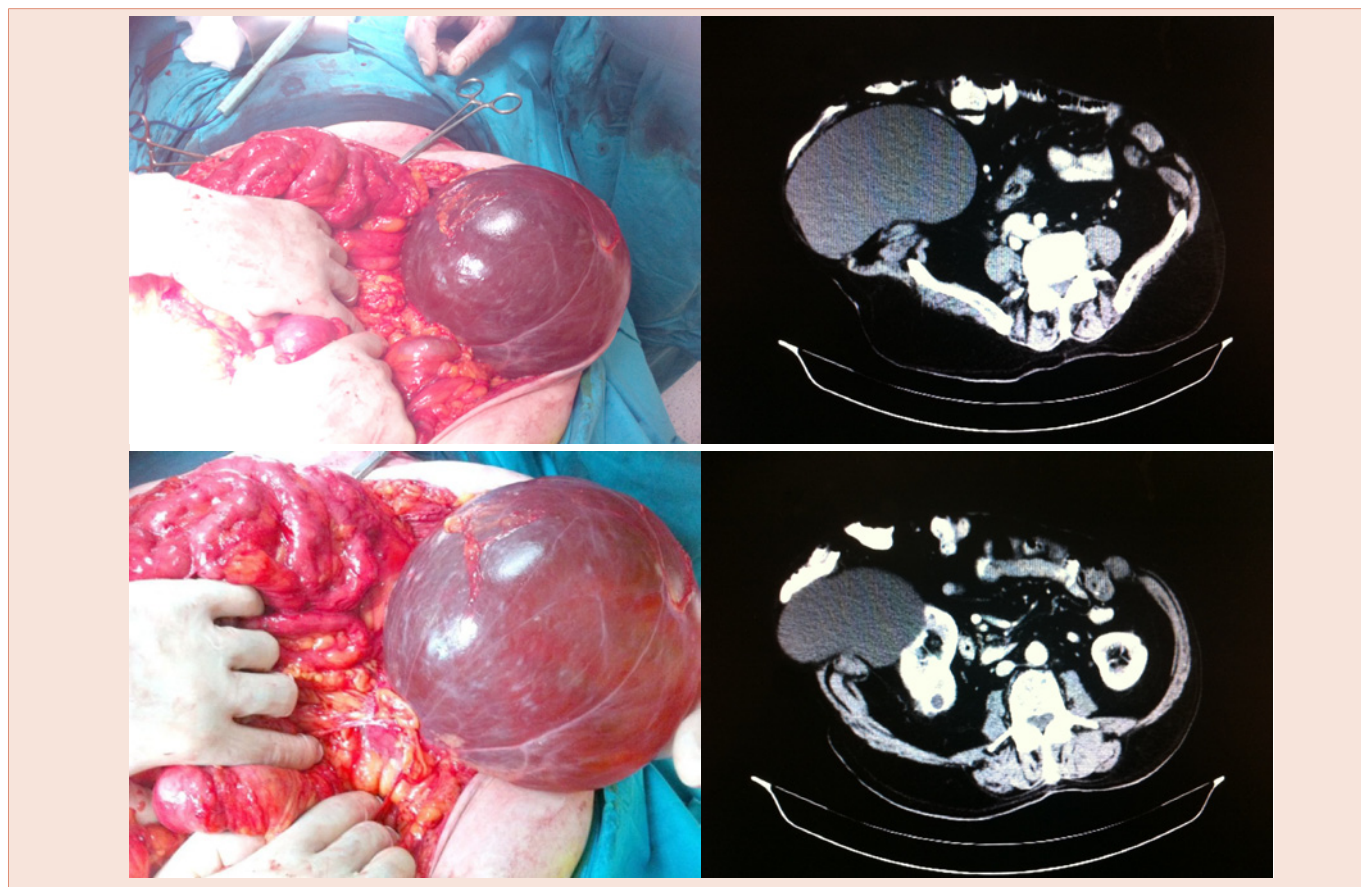
Surgery Department, Antequera Hospital, Spain

*Corresponding author: Francisco Javier Pérez Lara, Surgery Department, Antequera Hospital, Spain

Received: 24 September, 2014; Accepted: 21 November, 2014; Published: 24 November, 2014

82-year-old male patient previously twice subjected to surgical intervention for peritonitis, and to two subsequent interventions for giant incisional hernia. After the final intervention, the meshpad was removed, due to infection, but the giant eventration persisted. Eight years later, when anaemia was observed, a gastroenterology examination was performed and sigmoid cancer diagnosed.

Subsequent CT scans revealed a giant right renal cyst measuring 29 × 21 cm, within the evisceration. In response, a left hemicolectomy was performed, with resection and marsupialisation of the renal cyst, and repair of the incisional hernia. The patient evolved well and was discharged eight days after surgery.



Copyright: © 2014 Pérez Lara FJ, et al. This is an open-access article distributed under the terms of the Creative Commons Attribution License, which permits unrestricted use, distribution, and reproduction in any medium, provided the original author and source are credited.

Citation: Pérez Lara FJ, Alcaraz DH, Carmona JH, del Rey Moreno A, Muñoz HO (2014) Giant renal Cyst into Giant Laparotomic Hernia Imaging J Clin Med Sciences 1(2): 021. DOI: 10.17352/2455-8702.000014