

Case Report

Multiple Hepatic Cirrhosis Complications: Left Hepatic Hydrothorax, Upper Gastrointestinal Hemorrhage and Acute Portal Vein Thrombosis: A Case Report

Jorge Vidal Hernández Rodríguez*, Adrián Rodríguez García and Olga Campesino Ramos

Intensive Care Unit, Hospital el Bierzo, Ponferrada, Leon, Spain

*Corresponding author: Jorge Vidal Hernández Rodríguez, Intensive Care Unit, Hospital el Bierzo, Ponferrada, Leon, Spain, E-mail: jvhr1@hotmail.com

Received: 12 November, 2014; Accepted: 16 December, 2014; Published: 18 December, 2014

Introduction

Hepatic hydrothorax (HH), variceal haemorrhage (VH) and portal vein thrombosis (PVT) are complications associated with hepatic cirrhosis (HC) and involve poor prognosis.

HH occurs in 4%-17% of cirrhotic patients [1]. Atypical presentations include pleural effusion without ascites and left-sided only effusions. The pathophysiology is believed to involve defects in tendinous diaphragmatic portion. Usual treatment includes diuretics and thoracocentesis, and even transjugular intrahepatic portosystemic shunt (TIPS) and liver transplantation [2]. Among patients with cirrhosis, due to portal hypertension (PH), varices form quite frequently (10% a year, approximately), and about a third of patients with varices will develop VH. PVT is commonly developed in cirrhosis (ultrasonography studies have reported prevalence of 5 to 24 per cent), and is related to unbalanced haemostasis and slowing of portal flow.

Case Presentation

A 75 year old patient was admitted to our intensive care unit (ICU) because life-threatening upper digestive haemorrhage. He was diagnosed years ago of cirrhotic liver disease (CHILD B MELD 11). An upper gastrointestinal endoscopy, 6 days before admission, showed esophageal varices grade III (treated with endoscopic band ligation) and severe portal hypertension gastropathy. The patient had no previous history of cardiopathy.

After ICU admission, an upper gastrointestinal endoscopy was performed showing active bleeding from gastric fundus, and unsuccessful esclerotherapy was intended. Tracheal intubation and mechanical ventilation was required. A Sengstaken-Blakemore tube was inserted with adequate control of bleeding. Ultrasonography showed ascites and portal vein permeability.

In the routinary chest radiography a left white lung was observed. A fibrobronchoscopy was performed ruling out atelectasis associated with tracheal intubation. A thoracic tube was inserted, draining 4250 millilitres of transudate liquid in 10 hours. Despite of this, a new radiography showed no improvement in hydrothorax (Figure 1).

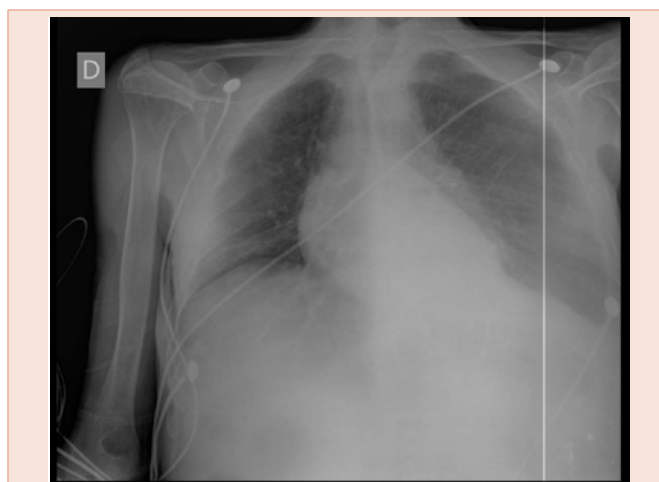


Figure 1: Thorax radiogram 48 hours before ICU admission.

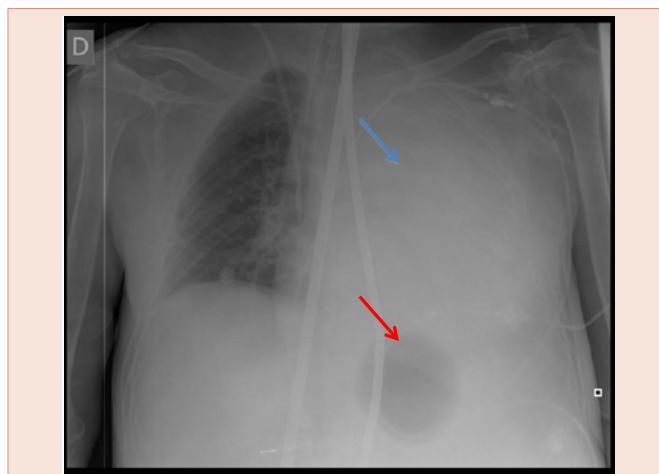


Figure 2: ICU admission thorax radiogram. A massive occupation of left lung can be observed (blue arrow). Note a Segstaken-Blackmore gastric balloon inflated with 200 ml (red arrow), orotracheal tube and jugular venous catheter.

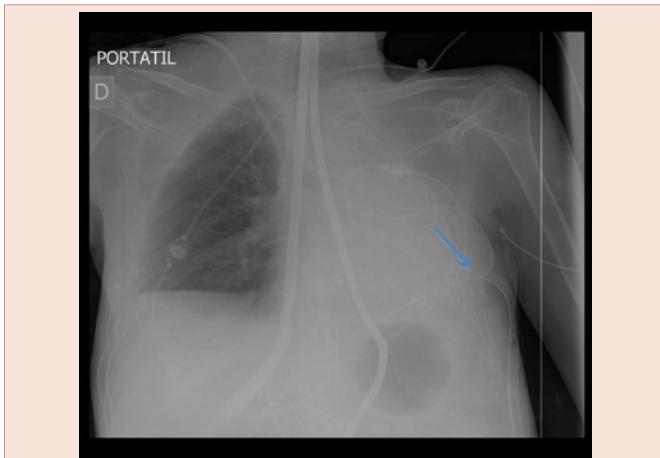


Figure 3: Control thorax radiogram after chest tube insertion (blue arrow).

In order to treat both complications, it was decided to transfer the patient to our reference centre to perform a TIPS, that couldn't be achieved because a portal thrombosis was discovered in abdominal ultrasonography (Figure 2).

Limitation on therapeutic efforts was decided. The patient died a few hours later, 74 hours after admission in our ICU (Figure 3).

Discussion

HC can develop PH. Due to this, several complications may take place (including HH, VH and PVT), involving a difficult management and a poor prognosis.

Left sided only HH is uncommon. HH is usually right sided because the bigger right tendinous portion of diaphragm, being more feasible defects on this side that allow the passage of peritoneal fluid into the pleural cavity assisted by negative intrathoracic pressure in inspiration.

Although long term HC, no PVT was found in the initial evaluation. Acute PVT has been associated to endoscopic sclerotherapy [3], which may explain the mechanism of thrombosis in this patient.

Conclusion

The combination of these three acute complications (VH left sided only HH and acute PVT) is extremely rare but involve poor prognosis, so every physician should be aware. Imaging procedures as portable ultrasonography could be very helpful. In order to decrease PH, either early TIPS or liver transplantation (if possible) should be considered in patients that develop HH and VH.

References

1. Badillo R, Rockey DC (2014) Hepatic hydrothorax: clinical features, management, and outcomes in 77 patients and review of the literature. *Medicine* 93: 135-142.
2. Roussos A, Philippou N, Mantzaris GJ, Gourgouliannis KI (2007) Hepatic hydrothorax: pathophysiology diagnosis and management. *J Gastroenterol Hepatol* 22: 1388-1393.
3. Amitrano L, Brancaccio V (2002) Portal vein thrombosis after variceal endoscopy sclerotherapy in cirrhotic patients: role of genetic thrombophilia. *Endoscopy* 34: 535-538.