

Nasir AM Al Jurayyan\*

Professor and Senior Consultant Pediatric Endocrinologist, Endocrine Division, Department of Pediatrics, College of Medicine and King Khalid University Hospital, King Saud University, Riyadh, Saudi Arabia

**Dates:** Received: 16 June, 2016; Accepted: 18 July, 2016; Published: 22 July, 2016

\*Corresponding author: Nasir A.M. Al Jurayyan, Department of Paediatrics (39), College of Medicine & King Khalid University Hospital, PO Box 2925, Riyadh 11461, King Saud University, Riyadh, Saudi Arabia, Tel: 00966-11-4670807; Fax: 00966-11-4671506; E-mail: njurayyan@gmail.com

www.peertechz.com

**Keywords:** Childhood; Diagnosis; Gynecomastia; Pathogenesis; Therapy

## Mini Review

# Childhood Gynecomastia: A Mini Review

### Abstract

Gynecomastia, referred to enlargement of the male's breast tissue is a common finding in boys during childhood. Although most cases are benign and self-limited, it may be a sign of an underlying systemic disease or even drug induced. Rarely, it may represent male breast cancer. Understanding its pathogenesis is crucial to distinguish a normal developmental variant from pathological cases. This review will highlight the pathophysiology, etiology, diagnosis and various medical and surgical therapies.

## Introduction

Gynecomastia, referred to enlargement of the male breast tissue (Figure 1), it is a common finding in childhood reported to be between 30 and 60%. Although, most cases are benign and self-limited, it may be a sign of an underlying systemic disease or drug-induced. It is usually bilateral but sometimes unilateral, and results from proliferation of the glandular component of the breast. It is defined clinically by the presence of a rubbery or firm mass extending concentrically from the nipple. Gynecomastia should be differentiated from pseudogynecomastia (lipomastia), which is characterized by deposition of fat without, glandular proliferation [1-6].

In this brief review we highlight the pathophysiology, etiology, diagnosis and discuss the various modalities of therapy (medical and surgical).

## Pathophysiology

The mechanism and pathophysiology of gynecomastia are not really clear (Figure 2). However, the major cause is believed to be an altered imbalance between estrogen and androgen effects, absolute increase in estrogen effects either an increase in estrogen production, relative decrease in androgen production, or a combination of both. Estrogen acts as a growth hormone of the breast and, therefore, excess of estradiol in men leads to breast enlargement by inducing

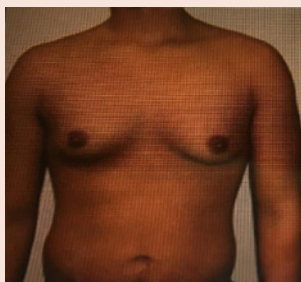


Figure 1: A 15 year old boy with gynecomastia.

**Increase in estrogens**  
 Direct secretion (from testes/adrenals/placenta)  
 Extraglandular aromatisation of precursors  
 Decreased metabolism  
 Exogenous administration  
**Decrease in endogenous free androgens**  
 Decreased secretion  
 Increased metabolism  
 Increased binding to sex hormone-binding globulin  
**Altered serum androgen/estrogen ratio**  
 Puberty, aging, refeeding gynecomastia, hepatic cirrhosis,  
 Hyperthyroidism, drugs, renal failure and dialysis  
**Androgen receptor defects**  
 Enhanced sensitivity of breast tissue ?

Figure 2: Pathophysiological mechanisms leading to gynecomastia.

ductal epithelial hyperplasia, duct elongation and branching, and the proliferation of periductal fibroblasts and vascularity. Local tissue factors in the breast can also be important, for example, increased aromatic activity that can cause excessive local production of estrogen, decreased estrogen degradation and changes in the levels or activity of estrogen, and androgen receptors.

Although prolactin (PRL) receptors are present in male breast tissue, hyperprolactinemia may lead to gynecomastia through effects on the hypothalamia causing central hypogonadism. Activation of PRL, also, leads to decreased androgens and increased estrogen and progesterone receptors. The role of PRL, progesterone and other growth factors such as insulin like growth factors (IGF-1) and epidermal growth factor (EGF), in the development of gynecomastia need to be clarified [5-10].

## Classification

The spectrum of gynecomastia severity has been categorized into a grading system [11]:

Grade I	Minor enlargement, no skin excess
Grade II	Moderate enlargement, no skin excess
Grade III	Moderate enlargement, skin excess
Grade IV	Marked enlargement, skin excess



## Etiology of gynemastia

Generally can be subdivided, according to the cause, into; (Table 1) [12-24].

**Physiological:** Estrogen levels rise during neonatal and pubertal period, which leads to an elevated estrogen/testosterone ration and, hence, gynecomastia the condition usually regress within two years of onset.

**Pathological:** Gynecomastia can occur at any age, as a result of a number of medical conditions such as liver cirrhosis primary hypogonadism and trauma.

**Medicational:** Medication induced gynecomastia is the most common cause. Agents associated with gynecomastia are listed in Table 2.

## Diagnosis of Gynecomastia

The history and physical examination should direct the laboratory and radiological imaging studies (Figure 3).

**Clinical Evaluation:** (History and physical examinations)

All boys with gynecomastia should be evaluated thoroughly by an experienced clinician. A detailed history should include the onset and duration of the breast enlargement, pain or tenderness, weight loss or gain, nipple discharge, virilization, medication history, and family history of gynecomastia which may suggest androgen insensitivity syndrome, familial aromatase excess or sestoli cell tumours. Physical examination should differentiate between true gynecomastia and pseudogynecomastia and should include signs of tomours, liver and kidney diseases, or hyperthyroidism and should also include genital examination [5,6,25-31].

Physiological
Neonatal
Pubertal
Involuntional
Pathological
Cirrhosis/liver disease
Starvation
Male hypogonadism (Primary or secondary)
Testicular neoplasms (germ cell tumours, leydig cell tumours, sex-cord tumours)
Hyperthyroidism
Renal failure and dialysis
Feminizing adrenocortical tumours
Ectopic HCG production
True hermaphroditism
Androgen insensitivity syndromes
Aromatase excess syndrome
Stressfull life events
Type 1 DM
Kennedy's syndrome
Drugs
Idiopathic

Drug
Estrogens, including topical preperations
Aromatisable androgens
hCG
Digitoxin, herbal products
GnRH agonistor antagonist
Leydig cell damage or inhibition
Ketoconazole, Metronidazole
Spironolactone, cancer chemotherapy
Finasteride or dutasteride
Flutamide, bicalutamide
Spironolactone, cancer chemotherapy
Cimetidine, Marijuana
Antipsychotic Agents
Metoclopramide, Verapamil
Isoniazid, Amiodarone, Antidepressants
Human GH, Proton pump inhibitors
Highly active retroviral therapy

## Diagnostic testing

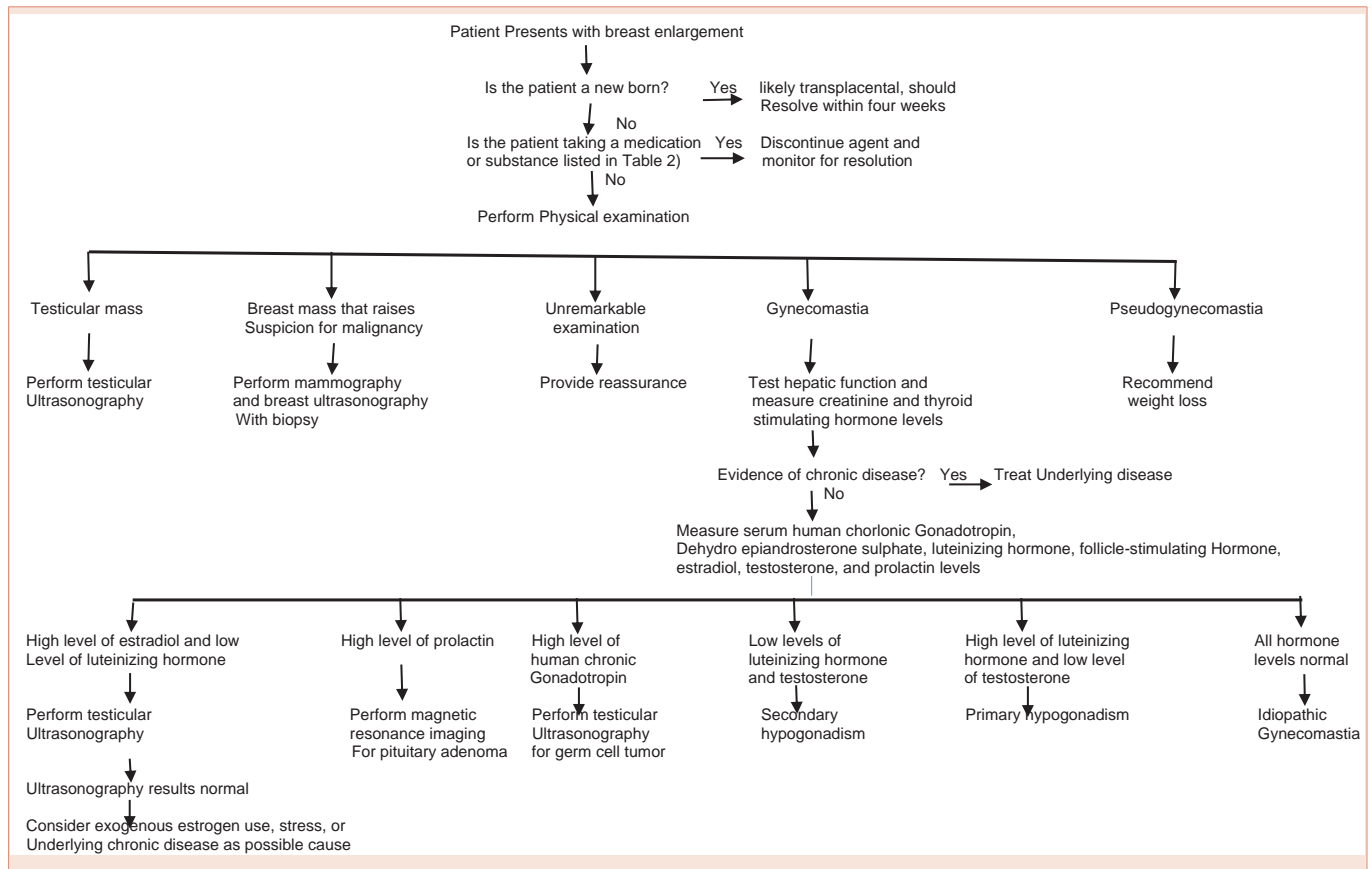
In cases without a clear cause, laboratory investigations should be pursued and must include liver, kidney and thyroid function tests as well as hormonal tests, estrogen, and free testosterone, luteinizing hormone (LH) , follicle-stimulating hormone (FSH), prolactin, human chorlonic gonadotrophin (HCG), dehydro epiandrosterone sulphate (DHEA-SO<sub>4</sub>) and α Feto protein (α FP). If testes are small the patients Karyotype should be obtained to roll out Klinefelter's Syndrome. Mammography (MMG) is the primary imaging when there is any suspicion of malignancy. Breast ultrasonography (USG), scrotal USG and abdominal computerized tomography (CT) of the abdomen can also be used as well as magnetic resonance imaging of the pituitary. A percutaneous biopsy should be taken, at times, when it is difficult to differentiate gynecomastia and breast cancer [5,6,32-36].

## Treatment of gynecomastia

Most cases of gynecomastia regress overtime without treatment. However, if gynecomastia is caused by an underlying conditions such hypogonadism, malnutrition or Cirrhosis, that condition may need treatment. If the patient taking medications that can cause gynecomastia, the clinician may recommend stopping or substituting them with other medication. In adolescents with no apparent cause, gynecomastia often goes away without treatment in less than 2 years. Reassurance and frequent follow up 3-6 months that's what needed. However, treatment may be necessary if gynecomastia does not improve on its own or if it causes significant pain tenderness or embarrassment [1,6,37].

## Medical treatment

Although no medical treatment cause complete regression of gynecomastia, they may provide partial regression, or symptomatic relief. Several agents regulate the hormonal imbalance. The major medical intervention options are androgens, anti-estrogens and aromatase inhibitors. Androgen testosterone replacement can be



**Figure 3:** Algorithm for the diagnosis of gynecomastia.

used to improve gynecomastia secondary to hypogonadism. Topical preparations are preferable as they lead to more steady state levels of testosterone in the body as compared with the injectable forms, which can worsen breast enlargement by aromatizing to estradiol. In recent years, anti-estrogens such as tamoxifen and anastrozole has been shown to be effective. More studies are needed to assess the effectiveness of aromatase inhibitors such as anastrozole and testalactone, which are powerful agents that block estrogen [32,38-43].

**Surgical treatment**

Surgical treatment should be individualized to each patient. Numerous techniques have been described for the correction of gynecomastia and the surgery is forced with a wide range of excisional and liposuction procedures. The most frequently encountered complication was a residual subareolar lump. Although skin excess remains a challenge, it can be satisfactorily managed without excessive scarring. A practical approach to the surgical management of gynecomastia, should take into account breast size, consistency, skin excess and skin quality. However generally it is not recommended until the testis has reached adult size, because if surgery is performed before achieving puberty, breast tissue may regrow [44-47].

If pseudogynecomastia is suspected no work up is needed and the patient can be reassured that weight loss will lead to resolution of

pseudogynecomastia. If necessary liposuction procedures can reduce breast enlargement secondary to subareolar fat accumulation.

**Acknowledgement**

The author would like to thank Ms. Cecile Sael for typing the manuscript, and extend his thanks and appreciation to Miss Hadeel N. Al Jurayyan for her help in preparing this manuscript.

**References**

1. Glenn D, Braunstein MD (2007) Gynecomastia. *N Engl J Med* 357:1229-1237.
2. Lazala C, Saenger P (2002) Pubertal Gynecomastia. *J Pediatr Endocrinol Metab* 15: 553-560.
3. De Sanctis V, Bernasconi S, Bona G, Bozzola M, Buzi F, et al. (2002) Pubertal gynecomastia. *Minerva Pediatr* 54: 357-361.
4. Nordt CA, DiVasta AD (2008) Gynecomastia in adolescents. *Curr opin Pediatr* 20: 375-382.
5. Cuhaci N, Polat SB, Evranos B, Ersoy R, Cakir B (2014) Gynecomastia: Clinical evaluation and management. *Indian J Endocrinol Metab* 18: 150-158.
6. Dickson G (2012) Gynecomastia. *Am Fam Physician* 85: 716-722.
7. Barros AC, Sampaio MD (2012) Gynecomastia: pathophysiology, evaluation and treatment. *So Paulo Med J* 130: 187-197.
8. Narula HS, Carlson HE (2014) Gynecomastia-pathophysiology, diagnosis and treatment. *Nat Rev Endocrinol* 10: 684-698.

9. Farthing MJ, Green JR, Edwards CR, Dawson AM (1982) Progesterone, prolactin and gynecomastia in men with liver disease. *Gut* 23: 276-279.
10. Ladizinski B, Lee KC, Nutan FN, Higgins HW, Federman DG (2014) Gynecomastia; Etiologies, Clinical Presentation, Diagnosis and Management. *South Med J* 107: 44-49.
11. Wollina U, Goldman A (2011) Minimally invasive esthetic procedures of the male breast. *J Cosmetic dermatol* 10: 150-155.
12. Bhasin S (2008) Testicular disorders. in; Kroneberg HM, Palonsky KS, Larson PR editors. *William textbook of Endocrinology*. 11th ed, Philadelphia Saunders Elsevier.
13. Nuttall FQ (2010) Gynecomastia. *Mayo Clin Proc* 85: 961-962.
14. Lanfranco F, Kamischke A, Zitzmann M, Nieschlag E (2004) Klinefelter's Syndrome. *Lancet* 364: 273-283.
15. Handelsman DJ, Dong Q (1993) Hypothalamo-pituitary gonadal axis in chronic renal failure. *Endocrinol Metab Clin North Am* 22: 145-161.
16. Karagiannis A, Harsoulis F (2005) Gonadal dysfunction in systemic diseases. *Eur J Endocrinol* 152: 501-513.
17. Layman LC (2007) Hypogonadotropic hypogonadism. *Endocrinol Metab Clin North Am* 36: 283-296.
18. Fentiman IS, Fourquet A, Hortobagyi GN (2006) Male breast cancer. *Lancet* 367: 595-604.
19. Eckman A, Dobs A (2008) Drug-induced gynecomastia. *Expert Opin Drug Saf* 7: 691-702.
20. Thompson DF, Carter JR (1993) Drug -induced gynecomastia. *Pharmacotherapy* 13: 37-45.
21. Goldman RD (2010) Drug-induced gynecomastia in children and adolescents. *Canadian Family physician* 56: 344-345.
22. Deepinder F, Braunstein GD (2012) Drug-Induced Gynecomastia: an evidence based review. *Expert Opin Drug Saf* 11: 779-795.
23. Basaria S (2010) Androgen abuse in athletes: detection and consequences. *J Clin Endocrinol Metab* 95: 1533-1543.
24. Goh SY, Loh KC (2001) Gynecomastia and the herbal tonic "Dong Quai" *Singapore Med J* 42:115-116.
25. Bembo SA, Carlson HE (2004) Gynecomastia: it's features, and when and how to treat it. *Cleve Clin J Med* 71: 511-517.
26. Gikas P, Mokbel K (2007) Management of gynecomastia: an update. *Int J Clin Pract* 61: 1209-1215.
27. Carlson HE (2011) Approach to the patients with gynecomastia. *J Clin Endocrinol Metab* 96: 15-21.
28. Dobs A, Darkes MJ (2005) Incidence and management of gynecomastia in men treated for prostate cancer. *J Urol* 174: 1737-1742.
29. Derkacz M, Chmiel-Perzynskal, Nowakoski A (2011) Gynecomasti- a difficult diagnostic problem. *Endokrynol Pol* 62: 190-202.
30. Biro FM, Lucky AW, Huster GA, Morrison JA (1990) Hormonal studies and physical examination in adolescents gynecomastia. *J Pediatr* 116: 450-455.
31. Hassan HC, Cullen IM, Casey RG, Rogers E (2008) Gynaecomastia: an endocrine manifestation of testicular cancer. *Andrologia* 40: 152-157.
32. Plourde PV, Kulin HE, Santner SJ (1983) Clomiphene in the treatment of adolescent gynecomastia, Clinical and endocrine studies. *AM J Dis Child* 137: 1080-1082.
33. Sansone A, Romanelli F, Sansone M, Lenzi A, Di Luigi L (2016) Gynecomastia and hormone. *Endocrine* PMID 27145756.
34. La Franchi SH, Parlow AF, Lippe BM, Coyotupa J, Kaplan SA (1975) Pubertal gynecomastia and transient elevation of serum estradiol level. *Am J Dis Child* 129: 927-931.
35. Bridenstein M, Bell BK, Rothman MS (2003) Gynecomastia in McDermott MT,ed *Endocrine secrets Am ed Philadelphia, PA elsevier sanders* Chig 40.
36. Munoz CR, Alvarez BM, Munoz GE, Raya P, Martinez PM (2010) Mammography and ultrasound in evaluation of male breast disease. *Eur Radiol* 20: 2797-2805.
37. Ruth EJ, Cindy AK, M Hassan M (2011) Gynecomastia evaluation and current treatment options. *Ther Clin Risk Manag* 7: 145-148.
38. Lapid O, van Wingerden JJ, Perlemuter L (2013) Tamoxifen therapy for the management of pubertal gynecomastia: a systematic review. *J Pediatr Endocrinol Metab* 26: 803-807.
39. Khan HN, Rampaul R, Blamey RW (2004) Management of physiological gynaeomastia with tamoxifen. *Breast* 13: 61-65.
40. Lawrence SE, Faught KA, Vethamuthu J, Lawson ML (2004) Beneficial effects of raloxifene and tamoxifen in the treatment of pubertal gynecomastia. *J Pediatr* 145: 71-76.
41. Maura N, Bishop K, Merinbaum P, Emeribe U, Agbo F, et al. (2009) Pharmacokinetics and Pharmacodynamics of anastrozole in prepubertal boys with recent-onset gynecomastia. *J Clin Endocrinol Metab* 94: 2975-2978.
42. Wit JM, Hero M, Nunez SB (2011) Aromatase inhibitors in Pediatrics . *Nat Rev Endocrinol* 8: 135-147.
43. Braunstein GD (1999) Aromatase and gynecomastia. *Endocr Relat Cancer* 6: 315-324.
44. Fruhstorfer BH, Malata CM (2003) A systematic approach to the surgical treatment of gynecomastia. *Br J Plast Surg* 56: 237-246.
45. Brown RH, Chang DK, Siy R, Friedman J (2015) Trends in surgical correction of gynecomastia. *Semin Plast Surg* 29: 122-130.
46. Handschin AE, Biertry D, Husler R, Banic A, Constaninescu M (2008) Surgical Management of gynecomastia: a 10 years analysis. *World J Surg* 32: 38-44.
47. Kasielska A, Antoszewski B (2013) Surgical management of gynecomastia: an outcomeanalysis. *Ann Plast Surg* 71: 471-475.