

SK Datta¹, KK Sethi¹, S Singh^{2*} and M Fotedar²

¹Department of Cardiology, Delhi heart and lung institute, New Delhi, India

²Department of Non-invasive Cardiology, Delhi heart and lung institute, New Delhi, India

Dates: Received: 14 June, 2016; Accepted: 29 July, 2016; Published: 01 August, 2016

***Corresponding author:** Sukhvinder Singh, Department of Non-invasive Cardiology, Delhi heart and lung institute, New Delhi, India, Tel: 9717205832; +911147098698; E-mail: kuks145@yahoo.co.in

www.peertechz.com

ISSN: 2455-5282

Keywords: Lutembacher syndrome; Percutaneous management; Mitral stenosis; Atrial septal defect; PTMC; Device closure

Case Report

Complete Percutaneous Management of Lutembacher Syndrome with Severe Pulmonary Hypertension in a Middle Aged Indian Female: Is this the Magic Wand?

Abstract

Lutembacher syndrome is a combination of ostium secundum atrial septal defect with acquired rheumatic mitral stenosis. This is a case of middle aged woman who had lutembacher syndrome with severe pulmonary hypertension with class IV symptoms. She had very severe mitral stenosis with valve area of 0.7 cm² and ostium secundum atrial septal defect of 14 mm size. The management of lutembacher syndrome was only surgical till 1990s. Total percutaneous management has been described in late 1990s. Percutaneous management is relatively cheaper option and saves the patient from artificial valve and related complications. However, only a small number of cases of total percutaneous management of this condition are available in world literature.

This patient was managed with percutaneous transmitral commissurotomy with Inoue balloon. Immediately after commissurotomy, her pulmonary artery pressure decreased by one-third. Device closure was done for her atrial septal defect in the same sitting. Her pulmonary artery pressure decreased further. The procedure was successful without any complications. She was symptomatically better on first post-procedure visit.

Abbreviations

ASD: Atrial Septal Defect; ECG: Electrocardiogram; PTMC: Percutaneous Transmitral Commissurotomy

Introduction

Lutembacher syndrome is a combination of ostium secundum atrial septal defect with acquired rheumatic mitral stenosis. The management of lutembacher syndrome was only surgical till 1990s. Total percutaneous management has been described in late 1990s. Percutaneous management is relatively cheaper option and saves the patient from artificial valve and related complications. However, only a small number of cases of total percutaneous management of this condition are available in world literature.

Case Presentation

A fifty-five years old female was referred to our institute from a remote place for double valve replacement (aortic and mitral) with atrial septal defect closure. She had a history of breathlessness on exertion for one year that had progressively increased from class II to class IV. The clinical examination revealed a low grade mid diastolic rumble and loud pulmonary component of second heart sound. A mid systolic murmur was present at left upper parasternal region and a pansystolic murmur was present at left lower parasternal region. The ECG showed normal sinus rhythm with left atrial abnormality. Echocardiogram revealed rheumatic heart disease with very severe mitral stenosis with mitral valve area of 0.7 cm² (0.598 cm²/ m² of body

surface area) (Figure 1, Video 1). There was trace mitral regurgitation and Wilkin's score was 7/ 16. Patient also had moderate tricuspid regurgitation and severe pulmonary hypertension with calculated right ventricular systolic pressure of 93 mmHg (Figure 2). Patient had an ostium secundum atrial septal defect (ASD) of size 8 mm with left to right shunt (Video 2). She had right atrial, left atrial as well as right ventricular enlargement. Not surprisingly, the mean gradient across the mitral valve was only 6.3 mmHg (Figure 3). There was associated aortic valve disease in the form of mild aortic stenosis and mild aortic regurgitation.

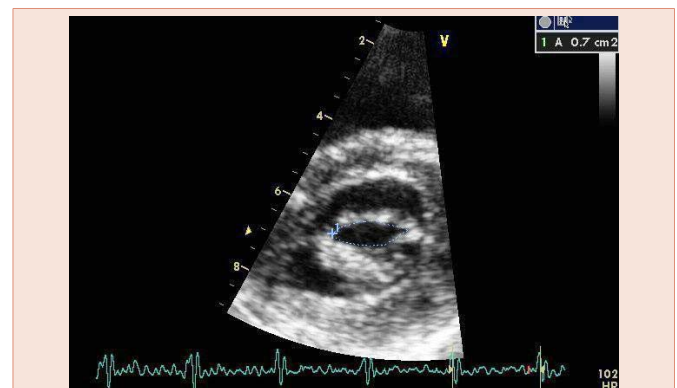
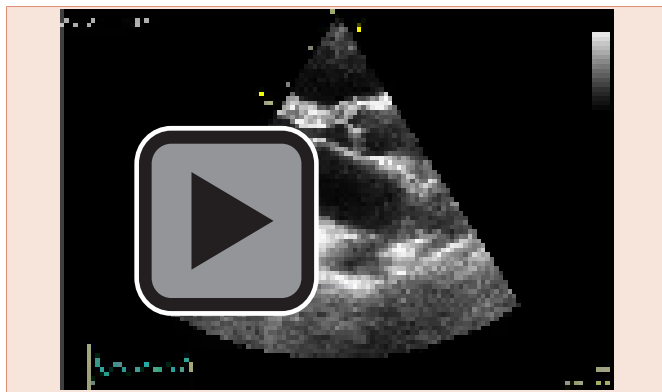


Figure 1: Parasternal short axis view of echocardiogram showing mitral valve area of 0.7cm² by planimetry.

Patient was subjected to transesophageal echocardiogram which revealed the atrial septal defect size to be ~14 mm with adequate margins (**Figure 4**). Catheter coronary angiogram was also performed which showed normal coronary arteries with right dominance.

Patient was planned for a sequential percutaneous transmitral commissurotomy (PTMC) followed by device closure of atrial septal defect after assessment of pulmonary hypertension.

Patient's baseline hemodynamics revealed left atrial pressure of 28/4 mmHg and peak right ventricular systolic pressure of 85mmHg.



Video 1:

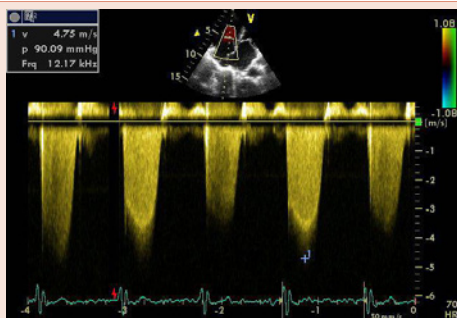
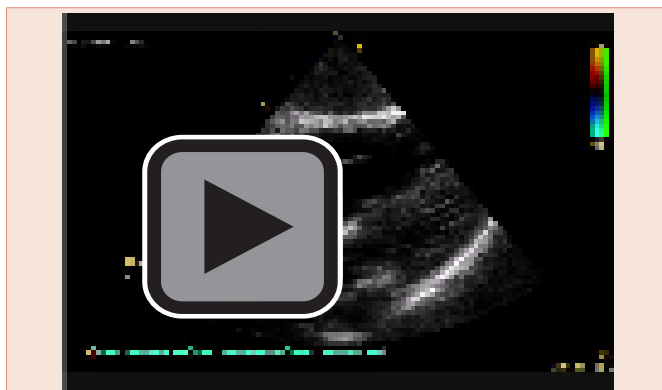


Figure 2: Echocardiogram showing Doppler of tricuspid regurgitation jet with gradient of 90mmHg.



Video 2:

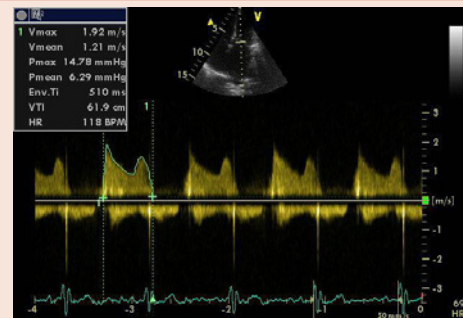


Figure 3: Echocardiogram showing Doppler of mitral valve with mean gradient of 6.29 mmHg.

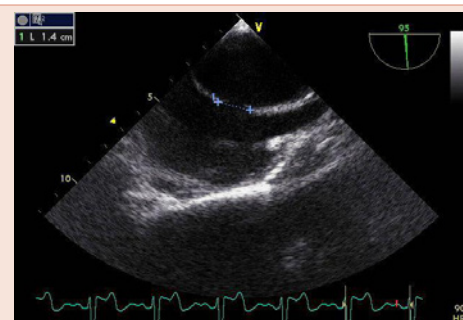


Figure 4: Transesophageal echocardiogram showing an ostium secundum atrial septal defect of 14mm.

Presence of atrial septal defect was confirmed. PTMC was performed using 25 mm inoue balloon (**Video 3**). Immediately after PTMC, the right ventricular systolic pressure reduced to 60mmHg. Trace mitral regurgitation was present on contrast left ventriculography. The ASD was closed using 18mm device (Lifetech, Heart R) (**Video 4**). Post ASD closure the right ventricular pressure decreased further to 40 mmHg. There was no shunt across the atrial septum on contrast study. Procedure remained uneventful.

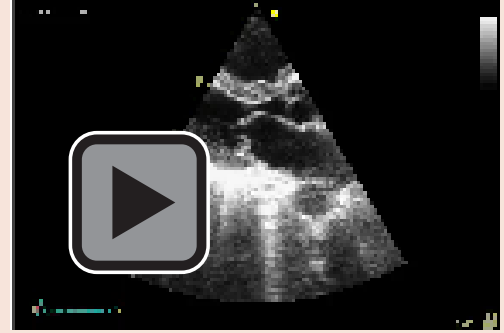
Patient underwent another echocardiogram after 48 hours of the procedure. It revealed absence of any residual shunt across the interatrial septum. The mitral valve area by planimetry increased to 1.3cm² (1.1 cm²/ m² of body surface area) (**Figure 5, Videos 5,6**). Mean gradient across the mitral valve reduced to 2.3 cm² (**Figure 6**). The calculated right ventricular systolic pressure dropped to 32 mmHg (**Figure 7**). There was trace mitral regurgitation. The ASD closure device was seen in normal position (**Video 7**). Patient was symptomatically much better on her first post-procedure visit.

Discussion

Lutembacher syndrome was first described by a French physician in 1916. It is currently regarded as a combination of congenital ostium secundum atrial septal defect and acquired mitral stenosis although Lutembacher stressed that his patient was having a congenital mitral stenosis [1]. The natural history of mitral stenosis changes favourably by presence of ASD which allows left atrium to decompress and prevents development of symptoms for long as gradient across the



Video 3:



Video 6:



Video 4:

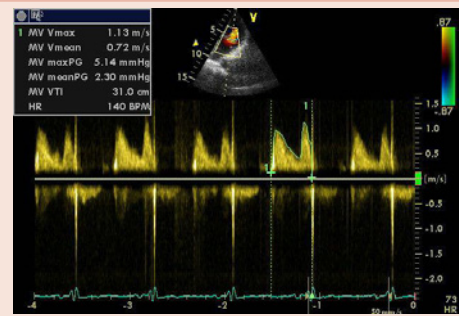


Figure 6: Echocardiogram showing Doppler of mitral valve with mean gradient of 2.3 mmHg after percutaneous commissurotomy.

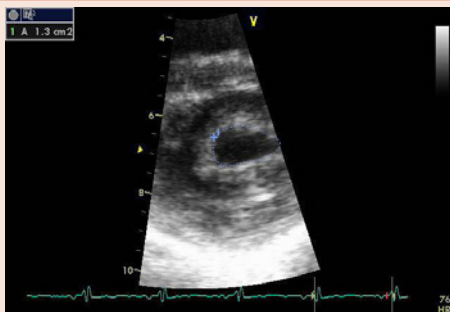


Figure 5: Parasternal short axis view of echocardiogram showing mitral valve area of 1.3cm² by planimetry after percutaneous commissurotomy.

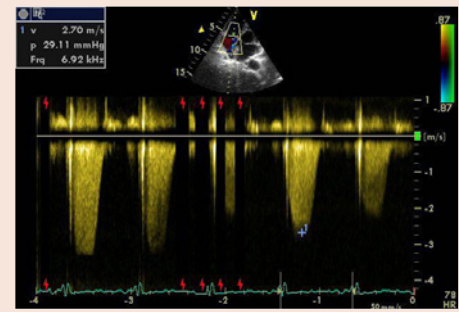




Figure 7: Echocardiogram showing Doppler of tricuspid regurgitation jet with gradient of 29mmHg after percutaneous commissurotomy.



Video 5:



Video 7:



mitral valve decreases. The pressure half time method and gradients across the mitral valve underestimate the severity of mitral stenosis in such a scenario. The mitral valve area should be measured by planimetry and continuity equation in these cases [2]. On the other hand, the excessive blood flow from left to right atrium leads to volume overload of right atrium and right ventricle leading to atrial arrhythmias and right sided failure. Thus mitral stenosis worsens the hemodynamic of ASD [1].

The treatment of lutembacher syndrome was surgical only until recently. Ruiz in 1992 reported first successful percutaneous management of lutembacher syndrome. They also performed balloon valvotomy of aortic valve on the same sitting [3]. The experience of percutaneous management of this condition has remained restricted to case reports only and large scale comparative studies have not been published as yet [4]. However, it is a promising and economically viable option for patients of poorer countries where rheumatic fever is more prevalent.

References

1. Perloff JK (2003) From Atrial septal defect. In: The clinical recognition of congenital heart disease, 5th edition. Edited by JK Perloff WB Saunders, Philadelphia 233-299.
2. Vasan RS, Shrivastava S, Kumar MV (1992) Value and limitations of Doppler echocardiographic determination of mitral valve area in Lutembacher syndrome. *J Am Coll Cardiol* 20: 1362-1370.
3. Ruiz CE, Gamra H, Mahrer P, Allen JW, O'Laughlin MP, et.al. (1992) Percutaneous closure of a secundum atrial septal defect and double balloon valvotomies of a severe mitral and aortic valve stenosis in a patient with Lutembacher's syndrome and severe pulmonary hypertension. *Cathet Cardiovasc Diagn* 25:309-312.
4. Babu MB, Rajasekhar D, Vanajakshamma V (2004) Percutaneous transcatheter treatment of Lutembacher syndrome. *J NTR Univ Health Sci* 3: 180-182.

Copyright: ©2016 Datta SK, et al. This is an open-access article distributed under the terms of the Creative Commons Attribution License, which permits unrestricted use, distribution, and reproduction in any medium, provided the original author and source are credited.

Citation: Datta SK, Sethi KK, Singh S, Fotedar M (2016) Complete Percutaneous Management of Lutembacher Syndrome with Severe Pulmonary Hypertension in a Middle Aged Indian Female: Is this the Magic Wand?. *Global J Med Clin Case Reports* 3(1): 022-025. DOI: 10.17352/2455-5282.000028