

Gálvez-Valdovinos Ramiro^{1*}, Arellano Aguilar Gregorio², Gutiérrez-Velazco José Luis³, Domínguez-Gasca Luis Gerardo⁴ and Domínguez-Carrillo Luis Gerardo⁵

¹Surgeon. Surgery Division from Hospital Angeles León. León, Guanajuato México

²Internal Medicine Specialist. Medicine Division, México

³Internal undergraduate. Surgery Division from Hospital Angeles León. León, Guanajuato México

⁴Traumatology and Orthopedic Resident. Surgery Division. General Hospital from León, Guanajuato México

⁵Rehabilitation Medicine Specialist. Professor of School Medicine from León. Guanajuato University, México

Dates: Received: 14 May, 2016; Accepted: 11 June, 2016; Published: 13 June, 2016

***Corresponding author:** Dr. Gálvez-Valdovinos Ramiro, Hospital Ángeles León. Av. Cerro Gordo No. 311, Col. Lomas del Campestre, León, Gto. México, CP, 37150, Tel: 477-7-88-56-83; 044-47-77-87-86-23; E-Mail: vgalvez@angelesleon.com

www.peertechz.com

ISSN: 2455-5282

Keywords: Sheep bite; Pasteurella canis; Septic arthritis; jejunostomy

Case Report

Pasteurella Canis as a Cause of Septic Arthritis and Soft Tissue Infection after Sheep Bite: A Case Report

Abstract

Pasteurella spp is the first organisms to consider in any patient who presents with a soft tissue infection following cat or dog bites. Pasteurella canis is most common isolate of dog bites, but there are no reports of pastereulla canis infection caused by sheep bite. A case of a 66 years old farmer woman with symptoms of infected left hand with wrist septic arthritis, after a lamb bite is described (the sheep was sick after a dog bite). Microbiological examination of the wrist articular liquid was performed. The specimen was both aerobic and anaerobic cultures were performed. After 24 hours, growth of smooth, greyish-white colonies was observed only on Columbia agar. Another Gram stained slide was performed from those colonies and Gram negative cocobacilli to short rod shaped morphology with bipolar staining was observed. They demonstrate positive catalase and oxidase positive reaction. The bacterium was susceptible to all tested antimicrobial agents. Although systemic forms of Pasteurella are possible, cutaneous infections from animal bites are the most common presentation. Most animal-bite injuries can be treated with oral antimicrobials on an outpatient basis, but in this case the patient needed intravenous antimicrobial aggressive therapy.

Introduction

Animal bites account for about 1 percent of emergency department visits and 10,000 inpatient admissions annually; approximately 1 in every 775 persons seeks emergency care for dog bites each year. Wound infections were diagnosed in 2.1 percent of cases [1]. In relation to microbiology, the predominant pathogens in animal bite wounds are the oral flora of the biting animal and human skin flora [2]. About 85 percent of bites harbor potential pathogens, and the average wound yields five types of bacterial isolates; 60 percent have mixed aerobic and anaerobic bacteria. Skin flora such as staphylococci and streptococci are isolated in about 40 percent of bites [3]. Pasteurella species are isolated from 50 percent of dog bite wounds and 75 percent of cat bite wounds [4]. Capnocytophaga canimorsus, can cause bacteremia and fatal sepsis after animal bites, especially in asplenic patients or those with underlying hepatic disease. Anaerobes isolated from dog and cat bite wounds include Bacteroides, fusobacteria, Porphyromonas, Prevotella, propionibacteria, and peptostreptococci. This is a report of the case of a patient with a sheep bite, (the sheep had sickened by dog bite). In this case Pasteurella canis was the culprit bacteria of the zoonoses transmission of an animal to another and from the latter to the human. Reports of sheep bite are rare, and Actinobacillus spp is the most frequent bacteria in sheep and horses bites [5,6].

Case Report

A 66-year-old farmer woman presented with symptoms of infected left hand, cellulitis of forearm and wrist septic arthritis after

a sheep bite on her thumb. The sheep was sick because a dog bite, the dog has been properly vaccinated. Patient stated that the first symptoms, with redness of thumb fingerprint, swelling and pain appeared 12 hours after the bite, over time (24 hour) they became worse. Clinical examination revealed a little lacerations on the anterior surface of the fingerprint thumb (Figure 1), the wound was regular in shape without secretions. The thumb, volar forearm and wrist were painful, erythematous, and edematous. (Figure 2) There was no evidence of conditions and past procedures that may put the patient at greater risk, such as diabetes, liver disease, immunosuppression or splenectomy. The patient was no febrile and she was feeling well except for important pain (in 8 in 0-10 VAS). There were no clinical signs of systemic infection. Laboratory results showed: PCR 201 mg/L,

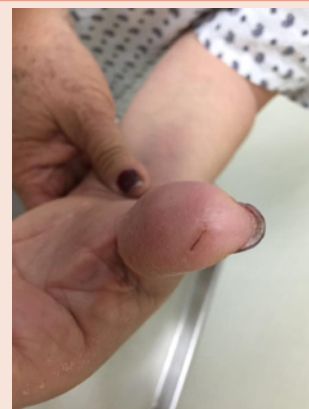

Figure 1: Lacerations on the anterior surface of the fingerprint part of the thumb; the wound was shaped regularly with no secretions caused by the sheep bite.

Procalcitonin 0.4 ng/mL, erythrocyte sedimentation rate 43mm/h %, neutrophils 55%, monocytosis of 14%. Blood cultures were not considered because the patient was not febrile. Magnetic resonance (Figure 3) showed wrist articular liquid increased and cellulitis at volar forearm. Articular liquid of wrist was aspirated with puncture guided by ultrasound for microbiological examination and cultures (Figure 4). Patient was hospitalized and provided with analgesics and broad spectrum intravenous antibiotics (Ceftriaxona 1 gr I.V qd, Doxyciclina 100mg V.O bid until the results of microbiological examination were done. She was asked for examinations on daily basis. Two days later, during the control examination, there were signs of local condition improvement, laboratory showed: PCR 64 mg/L. By that time the microbiological examination (Results: *Pasteurella canis*) was ready and since the administrated antibiotic therapy was satisfying we suggested the patient to proceed with it. The next control (after 4 days) showed even greater progress. Patient left hospital with Ceftriaxona 1 gr I.M qd and Doxyciclina 100mg V.O bid, bouth by 6 weeks. In following twenty days after, she was asymptomatic.

Discussion

Genus *Pasteurella* [7], are small, nonmotile, nonspore-forming organisms. In Gram stained specimens, they generally appear as a single bacillus, often with bipolar staining, but may also be seen in pairs or short chains. *Pasteurella* spp [8], are aerobic, facultatively anaerobic, and grow well at 37°C on 5 percent sheep blood (the preferred culture medium), chocolate, or Mueller-Hinton agar; most strains recovered from clinical specimens are catalase, oxidase, indole, sucrose, and decarboxylate ornithine positive. The indole-positive species exhibit a mouse-like odor. Potential bacterial virulence factors include capsule lipopolysaccharide, a cytotoxin, iron acquisition proteins. Human infections have been reported from *P. multocida* (the most common pathogen and type species for the genus), including *P. multocida* subsp *multocida*, *P. multocida* subsp *septica*, and *P. multocida* subsp *gallicida*; *P. canis*; *P. dagmatis*; and *P. stomatis*. All except *P. canis* (associated only with dogs) is associated with dogs and cats [9,10]. The clinical evaluation begins with a review of the circumstances related to the incident should be elicited, including whether the animal is available for observation. Patients presenting >8 hours following the injury are likelier to have established infection than those presenting early. Clinical manifestations of bite wound infections may include fever, erythema, swelling, tenderness, purulent drainage [11], subcutaneous abscesses occur in up to 20 percent of cases; in addition to local wound infection, complications include lymphangitis, septic arthritis, osteomyelitis [12] and tenosynovitis; uncommon complications include endocarditis, meningitis [13,14], brain abscess, and sepsis with disseminated intravascular coagulation especially in immunocompromised individuals. Biting study must include plain radiographs of the wound are warranted to evaluate bony structures and for presence of foreign bodies. Patients with suspected, deep or severe wound infections should undergo magnetic resonance imaging scanning to evaluate for subcutaneous abscess, osteomyelitis, septic arthritis (like in this case), or tendonitis. Pain near a bone or joint that is out of proportion to injury severity should suggest periosteal penetration with risk for osteomyelitis,

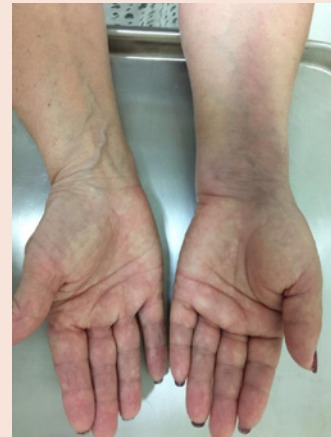

Figure 2: Thumb, thenar zone, volar forearm, and wrist pain in addition to erythematous and edematous two days after sheep bite.

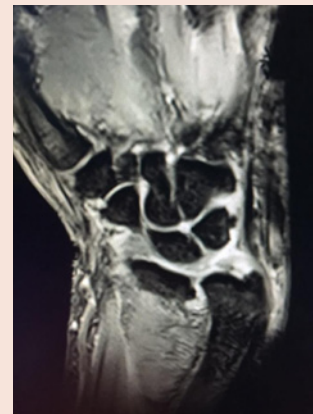

Figure 3: Magnetic resonance image, showing increased fluid in radio-carpal and inter-carpal joints by septic arthritis and laminar cellulitis as secondary effects from a sheep bite.

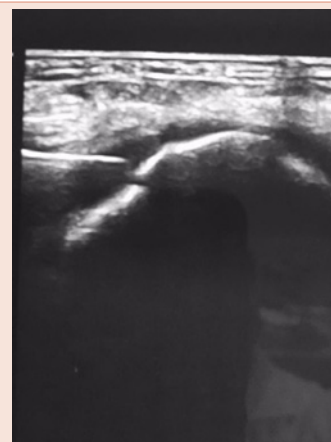


Figure 4: Ultrasound guided puncture of inter-carpal joint for microbiological culture in patient with septic arthritis caused by a sheep bite. (Culture results: *Pasteurella canis*).

while focal pain along a tendon sheath should raise suspicion for tenosynovitis. It is important to remember that bite wounds may also be accompanied by bacteremia, even if they do not appear grossly infected; blood cultures should be obtained in the setting of fever or other signs of systemic infection. Sepsis [15] and its complications can also occur, particularly among immunocompromised hosts. Treatment of bite wounds should be irrigated copiously with sterile saline, and grossly visible debris should be removed. Superficial wound cultures obtained at the time of injury are not helpful for predicting whether infection will develop, since early wounds are often colonized with potential pathogens, and it can be difficult to predict whether the wound will become infected. Surgical evaluation is warranted for patients with deep wounds and for infected animal bite wounds with abscess formation or evidence of deep infection, especially for wounds involving the hand. Debrided material should be sent for aerobic and anaerobic culture. In general, wounds should be left open, with approximation of wound edges to facilitate closure by secondary intention. Elevation of the injured area is important to accelerate healing and reduce pain due to dependent swelling. Antibiotic prophylaxis and empiric antibiotic therapy for infected wounds typically involves broad spectrum coverage of Gram positive, Gram negative, and anaerobic bacteria, similar to victims of dog or cat bites [16]. Patients with deep or severe wound infections should receive intravenous antibiotics; if there are complicated infections ii require prolonged therapy the synovitis should be treated for up to four weeks, and osteomyelitis usually requires at least six weeks of therapy [17]. In the absence of such complications, the duration of antibiotic therapy should be tailored to clinical improvement. In the setting of bacteremia, 10 to 14 days of parenteral therapy should be administered. Otherwise, cellulitis and skin abscess usually respond to 5 to 10 days of therapy. Intravenous therapy may be switched to outpatient oral therapy when evidence of clinical improvement is apparent.

Brief History of the Farm

In the farm in this case study, the farmer who was bitten is responsible for the sheep. She feeds them, attends births, and acts as a veterinarian, activities that have been carried out for years. The patient says that frequently a small sheep dies without apparent cause, and then the dead animal is given to the farm dogs to eat without dismembering or dressing it. We made a visit to the farm with a veterinarian to investigate the clinical status of the dogs, and we found that all of the dogs are carriers of *Pasteurella*. The veterinarian confirmed that one dog in particular is responsible for biting small sheep, so that the sheep get sick and can be eaten. This dog especially eats only raw meat. Both packs of dogs and sheep are being treated by the veterinary team.

References

1. Oehler RL, Velez AP, Mizrahi M, Lamarche J, Gompf S (2009) Bite-related and septic syndromes caused by cats and dogs. *Lancet Infect Dis* 9: 439-447.
2. Aziz H, Rhee P, Pandit V, Tang A, Gries L, et al. (2015) The current concepts in management of animal (dog, cat, snake, scorpion) and human bite wounds. *J Trauma Acute Care Surg* 78: 641-648.
3. Abrahamian FM, Goldstein EJ (2011) Microbiology of Animal Bite Wound Infections. *Clin Microbiol Rev* 24: 231-246.
4. Hon KL, Fu CC, Chor CM, Tang PS, Leung TF, et al. (2007) Issues associated with dog bite injuries in children and adolescents assessed at the emergency department. *Pediatr Emerg Care* 23: 445-449.
5. Peel MM, Hornidge KA, Luppino M, Stacpoole AM et al. (1991) *Actinobacillus* spp. and related bacteria in infected wounds of humans bitten by horses and sheep. *J Clin Microbiol* 29: 2535-2538.
6. Kannikeswaran N, Kamat D (2009) Mammalian bites. *Clin Pediatr (Phila)* 48: 145-148.
7. Harper M, Boyce JD, Adler B (2004) *Pasteurella multocida* pathogenesis: 125 years after Pasteur. *FEMS Microbiol Lett* 265: 1-10.
8. Donnio PY, Lerestif-Gautier AL, Avril JL (2004) Characterization of *Pasteurella* spp. strains isolated from human infections. *J Comp Pathol* 130: 137-142.
9. American Academy of Pediatrics (2015) *Pasteurella* infections. In: Red Book: 2015 Report of the Committee on Infectious Diseases, 30th, Kimberlin DW, Brady MT, Jackson MA, Long SS (Eds), American Academy of Pediatrics, Elk Grove Village IL 596.
10. Jorgensen JH, Hindler JF (2007) New consensus guidelines from the Clinical and Laboratory Standards Institute for antimicrobial susceptibility testing of infrequently isolated or fastidious bacteria. *Clin Infect Dis* 44: 280-286.
11. Stevens DL, Bisno AL, Chambers HF, Dellinger EP, Goldstein EJ, et al. (2014) Practice guidelines for the diagnosis and management of skin and soft tissue infections: 2014 update by the infectious diseases society of America. *Clin Infect Dis* 59: e10-52.
12. Chodakewitz J, Bia FJ (1988) Septic arthritis and osteomyelitis from a cat bite. *Yale J Biol Med* 61: 513-518.
13. Kawashima S, Matsukawa N, Ueki Y, Hattori M, Ojika K, et al. (2010) *Pasteurella multocida* meningitis caused by kissing animals: a case report and review of the literature. *J Neurol* 257: 653-654.
14. O'Neill E, Moloney A, Hickey M (2005) *Pasteurella multocida* meningitis: case report and review of the literature. *J Infect* 50: 344-345.
15. Chang K, Siu LK, Chen YH, Lu PL, Chen TC, et al. (2007) Fatal *Pasteurella multocida* septicemia and necrotizing fasciitis related with wound licked by a domestic dog. *Scand J Infect Dis* 39: 167-170.
16. Brook I (2009) Management of human and animal bite wound infection: an overview. *Curr Infect Dis Rep* 11: 389-395.
17. Baron EJ, Miller JM, Weinstein MP, Richter SS, Gilligan PH, et al. (2013) A guide to utilization of the microbiology laboratory for diagnosis of infectious diseases: 2013 recommendations by the Infectious Diseases Society of America (IDSA) and the American Society for Microbiology (ASM) (a). *Clin Infect Dis* 57: e122-e121.

Copyright: © 2016 Ramiro GV, et al. This is an open-access article distributed under the terms of the Creative Commons Attribution License, which permits unrestricted use, distribution, and reproduction in any medium, provided the original author and source are credited.

Citation: Ramiro GV, Gregorio AA, Luis GVJ, Gerardo DGL, Gerardo DCL (2016) *Pasteurella Canis* as a Cause of Septic Arthritis and Soft Tissue Infection after Sheep Bite: A Case Report. *Global J Med Clin Case Reports* 3(1): 012-014. DOI: 10.17352/2455-5282.000025