

Rocha Michaels C, Kamrul R and
Rehman HU*

Department of Medicine, Regina Qu'Appelle Health
Region, Regina General Hospital, 1440-14th Avenue,
Regina, SK, S4P 0W5, Canada

Dates: Received: 16 October, 2014; Accepted: 08
November, 2014; Published: 10 November, 2014

*Corresponding author: Dr. HU Rehman, Clinical
Associate Professor, Department of Medicine, Regina
Qu'Appelle Health Region, Regina General Hospital,
1440-14th Avenue, Regina, SK, S4P 0W5, Canada,
E-mail: habib31@sasktel.net

www.peertechz.com

ISSN: 2455-5282

Case Report

Iron Deficiency Anemia in a Premenopausal Woman

Case

A 47-year-old woman presented to her family physician with complaints of persistent fatigue of three months duration. She had menorrhagia, irregular menses and mild dysmenorrhea but denied dyspnea, weight loss, fevers, night sweats, melena stool, overt rectal bleeding, hematuria, hematemesis and abdominal pain. She did not smoke and drank socially.

She looked pale on examination. Blood pressure was 141/77 mmHg, heart rate 114/min, temperature 36.6 C, and oxygen saturation while breathing room air was 99%. Gynecological examination was not performed. Her medical history was remarkable for recent diagnoses of iron deficiency anemia, chronic hyponatremia since age 26 and depression treated with Paroxetine. She was not taking aspirin or NSAIDs.

Her complete blood cell count revealed hemoglobin of 7.3g/dL, MCV 74.0 fL and RDW 16.6. Hemoglobin was 12.4g/dL 8 months before presentation. Urea nitrogen (BUN), creatinine and electrolytes were within normal limits. Pregnancy test and urinalysis were not performed.

She was transfused with 3 units of packed red blood cells. Esophagogastroduodenoscopy, colonoscopy and capsule endoscopy did not identify any source of bleeding. Gastric biopsies were negative for Celiac disease. Therapeutic course of iron was commenced and a follow up arranged.

Diagnosis

Given the history of menorrhagia and dysmenorrhea and the fact that GI causes of anemia were ruled out, she underwent pelvic ultrasound. It showed an enlarged right ovary measuring 6.4x5.9cm. The patient was referred to a gynecologist. On gynecological examination, external genitalia, vaginal vaults, introitus, and cervix were unremarkable. A mobile mass was palpable in the right adnexa. MRI revealed a 7.3x7.2x6.1cm mass lesion containing solid and cystic components. There was a large hemorrhagic component to the lesion, appearances strongly suggestive of a malignant ovarian cancer.

A diagnostic laparoscopy was undertaken. Genital tract was found normal and the presumed ovarian mass was actually a pedunculated

lesion measuring 7-8cm arising from the small bowel. Mass was resected laparoscopically.

The pathology diagnosis was a Gastrointestinal Stromal Tumor (GIST) with surgical margins positive for tumor. A second operation was carried out for wedge resection of small bowel. She was referred to the oncologists for chemotherapy.

Discussion

Iron deficiency (ID) is defined as the decrease of the total content of iron in the body. Iron deficiency anemia (IDA) occurs when ID is severe enough to reduce erythropoiesis. In the developed world IDA occurs in about 2 to 5% of men and postmenopausal women [1]. In men and post-menopausal women IDA is most commonly caused by gastrointestinal blood loss [2]. Other causes include malabsorption, blood donation, hematuria, and dietary deficiency. In premenopausal women, IDA is usually due to menstrual blood loss, increase demand in pregnancy and breast-feeding, and dietary deficiency or malabsorption most commonly caused by celiac disease. It is estimated that about 11% of women aged between 20 and 49 years have ID [3] (Table 1).

Initial evaluation should start with detailed history addressing all potential causes of IDA.

Clinical markers for defining ID

Microcytosis (MCV<80fL) and hypochromia (MCH<26pg)

Both are sensitive indicators in the absence of chronic disease, sideroblastic anemia, hemoglobinopathies or coexisting vitamin B12 and folate deficiency.

Elevation of red cell distribution width (RDW) (>14%)

Low ferritin 15ng/ml, low transferrin saturation (<15%), low iron (<7µmol/L) and increased total iron binding capacity (TIBC) (>80%).

CDC and WHO definition of IDA by decreased hemoglobin levels

Menstruating women < 12 g/dL

Pregnant women < 11 g/dL

Men < 13 g/dL

IDA is diagnosed when low hemoglobin level is accompanied by iron deficiency. RDW can distinguish between IDA and thalassemia minor. A low MCV and an RDW of greater than 14.0% indicates IDA, whereas a low MCV and an RDW less than or equal to 14.0%

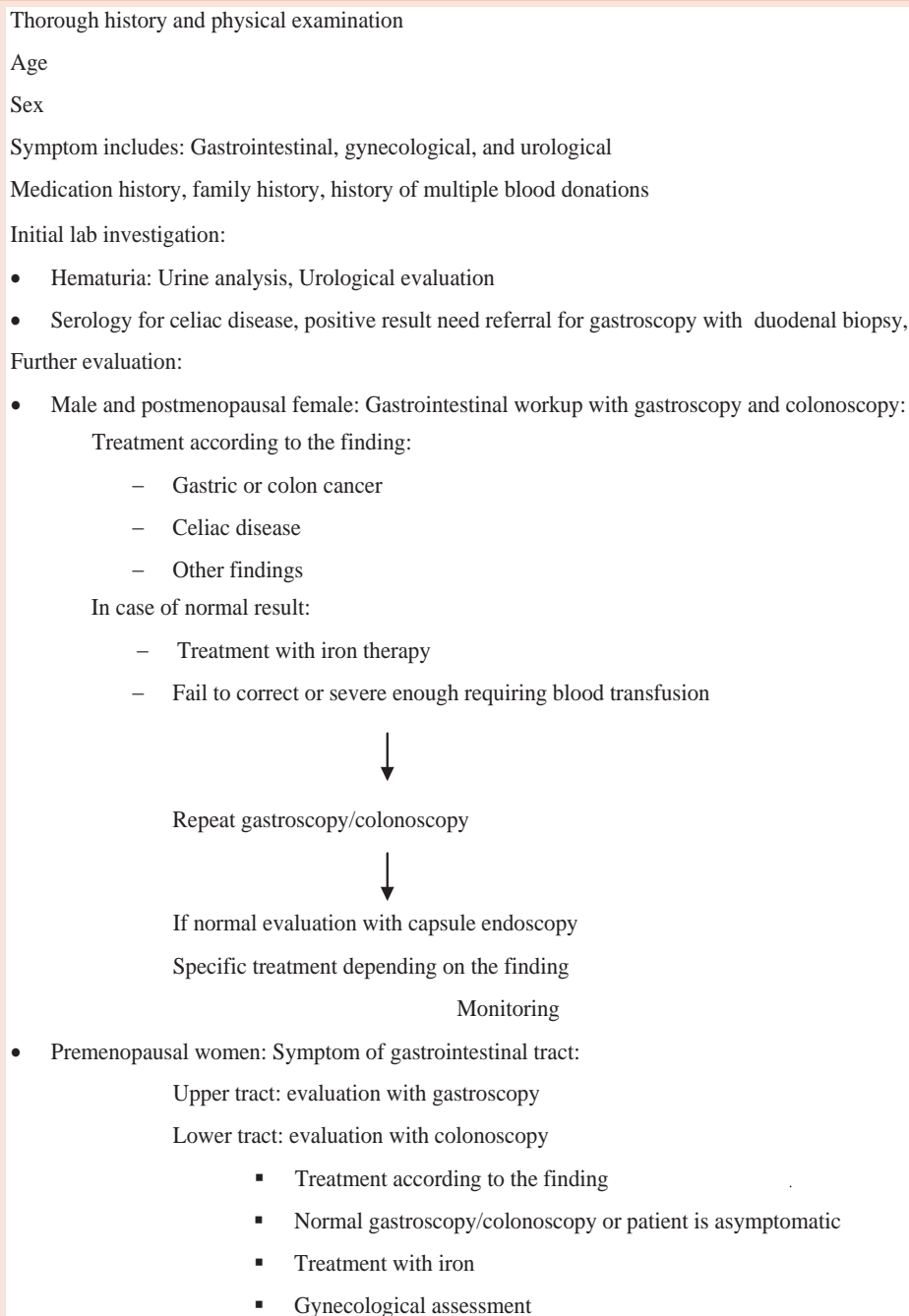


Figure 1: Searching for underlying causes of iron deficiency Anemia [5].

indicates thalassemia minor. Anemia of chronic diseases (ACD) are found to be microcytic, hypochromic in 30-40% of the cases making it difficult to differentiate from IDA, however it is possible that the two disease states coexist. Serum iron is low in both conditions, however, TIBC and ferritin are low in IDA but high in ACD [1]. Other parameters, such as soluble transferrin receptor activity may be useful. The Number of transferrin receptor numbers increase in IDA, but remain normal in ACD [5].

Serum ferritin is the most powerful test for ID in the absence of inflammation. Levels below 15ng/ml are diagnostic of ID (sensitivity 59%, specificity 99%). The diagnostic yield of serum ferritin may be improved by using a cutoff of <30 ng/ml (sensitivity 92%, specificity 98%) [1]. Serum iron, transferrin, and transferrin saturation have their limitations, but are useful in supporting diagnoses of IDA when serum ferritin is equivocal. If uncertainty persists after biochemical investigation, consider bone marrow biopsy for definitive diagnosis.

Table 1: Causes of iron deficiency anemia [5].

| | |
|---|---|
| Increased loss of iron: | |
| 1. | Hemorrhage: <ul style="list-style-type: none"> • Gastrointestinal Cancer, polyp, adenoma • Peptic ulcer disease • Esophagitis • Erosive gastritis • NSAID use • Inflammatory bowel disease • Menorrhagia |
| 2. | Intravascular hemolysis <ul style="list-style-type: none"> • Paroxysmal nocturnal hemoglobinuria |
| 3. | Multiple blood donation |
| Reduced iron absorption | |
| | <ul style="list-style-type: none"> - Celiac disease - Atrophic gastritis - Gastric surgery - Post-intestinal resection - Whipple's disease |
| Urological disease | |
| Gynecological disease | |
| Dietary deficiencies | |
| Increased demand for iron such as in pregnancy | |
| Data from Fernando and Santiago | |
| Data from Fernando [5] and Santiago [5] | |

The underlying cause of IDA must be discovered, otherwise a serious disease may be overlooked (Figure 1) [1]. GI investigations should be considered in all patients with IDA unless there is a clear evidence of non-GI blood loss.

Take Away

In a busy practice a systematic approach is important to prevent a missed or delayed diagnosis. IDA must be taken seriously for two

reasons: It has an impact on the patient's quality of life and may be a sign of a life-threatening disorder. The standard of care is to perform GI investigations in men and postmenopausal women. Management in premenopausal women, where a therapeutic iron course is suggested, can be complex. This is a reasonable approach only for patients with a high risk of physiological ID, for example adolescents and pregnant women. Other than very specific situations, ID with or without anemia should always be investigated in a systematic approach.

References

- Goddard AF, James MW, McIntyre AS, Scott BB (2011) Guidelines for the management of iron deficiency anaemia. British Society of Gastroenterology. Gut 60: 1309-1316.
- Liu K, Kaffes AJ (2012) Iron deficiency anaemia: a review of diagnosis, investigation and management. Eur J Gastroenterol Hepatol 24: 109-116.
- <http://www.cdc.gov/mmwr/preview/mmwrhtml/00051880.htm>, (Accessed April 18, 2014).
- Wians FH Jr., Urban JE, Keffer JH, Kroft SH (2001) Discriminating between iron deficiency anemia and anemia of chronic disease using traditional indices of iron status versus transferrin receptor concentration. Am J Clin Pathol 115: 112-118.
- Bermejo F, Garcia-Lopez S (2009) A guide to diagnosis of iron deficiency and iron deficiency anemia in digestive diseases. World J Gastroenterol 15: 4638-4643.
- Hallberg L, Bengtsson C, Lapidus L, Lindstedt G, Lundberg P-A, et al. (1993) Screening for iron deficiency: an analysis based on bone-marrow examinations and serum ferritin determinations in a population sample of women. Br J Haematol 85: 787-798.
- Bermejo F, Garcia-Lopez S (2009) A guide to diagnosis of iron deficiency and iron deficiency anemia in digestive diseases. World J Gastroenterol 15: 4638-4643.

Copyright: © 2014 Rocha MC, et al. This is an open-access article distributed under the terms of the Creative Commons Attribution License, which permits unrestricted use, distribution, and reproduction in any medium, provided the original author and source are credited.

Citation: Rocha MC, Kamrul R, Rehman HU (2014) Iron Deficiency Anemia in a Premenopausal Woman. Global J Med Clin Case Reports 1(2): 043-045. DOI: 10.17352/2455-5282.000014