

Jelena Roganovic^{1*}, Ingeborg Barisic²,
Nives Jonjic³, Ksenija Fumic⁴ and Ana
Dordevic⁵

¹Department of Pediatrics, University Children's
Hospital, Rijeka, Croatia

²Department of Pediatrics, Children's Hospital
Zagreb, Zagreb, Croatia

³Department of Pathology and Pathological
Anatomy, School of Medicine, University of Rijeka,
Croatia

⁴Department of Laboratory Diagnostics, Clinical
Hospital Center Zagreb, Croatia

⁵Faculty of Pharmacy, University of Trieste, Italy

Dates: Received: 28 Septembr, 2014; Accepted: 13
October, 2014; Published: 15 October, 2014

***Corresponding author:** Jelena Roganovic, MD,
PhD, Prof., Division of Hematology and Oncology,
Department of Pediatrics, University Children's
Hospital Rijeka, Istarska 43, HR – 51000 Rijeka,
Croatia, Tel: ++38551659103; Fax: ++38551623126;
E-mail: jelena.roganovic1@ri.t-com.hr

www.peertechz.com

ISSN: 2455-5282

Keywords: Fabry disease; Angiokeratoma; Child

Case Report

Angiokeratoma in Fabry Disease: Diagnostic but not Treatment Effectiveness Marker

Abstract

Introduction: Fabry disease (FD) is a rare metabolic disorder that leads to severe morbidity and premature mortality as a result of cardiac, renal or cerebrovascular complications. Enzyme replacement therapy (ERT) has been shown to provide clinically important benefits, and treatment is likely to alter the natural history of FD.

Case Report: The authors describe a 7-year-old boy with FD. Vascular skin lesions were very helpful in guiding appropriate investigations leading to prompt diagnosis. Because of multisystem involvement, including signs of nephropathy, ERT was started. The boy showed catch-up growth with skeletal maturation, and albuminuria reversed. However, angiokeratomas increased in size and number.

Conclusion: The most recognizable early physical sign of FD is angiokeratoma, which can play a critical role in the detection of the disease. However, there is no compelling evidence that angiokeratoma can serve as a surrogate marker for the course of the disease or the efficacy of ERT.

Abbreviations

FD: Fabry Disease; ERT: Enzyme Replacement Therapy; α -Gal A: α -Galactosidase A; GL-3: Globotriaosylceramide

Introduction

Fabry disease (FD) is a rare X-linked recessive disorder caused by mutations in the gene encoding the lysosomal enzyme α -galactosidase A (α -Gal A). The resulting deficient α -Gal A activity leads to progressive accumulation of glycosphingolipids, predominantly globotriaosylceramide (GL-3) in the lysosomes of many different cell types throughout the body [1]. The manifestations of this complex metabolic disease are progressive and multisystemic, culminating in life-threatening renal, cardiac and cerebrovascular manifestations [2].

Typical skin manifestations of FD are angiokeratomas, small, flat or slightly raised, purplish-red angiectases. They usually manifest at age 5 to 15, and may be the earliest physical sign of FD. The lesions are mainly found in the "swimsuit" area (the region between the umbilicus and the knees), and become larger and more numerous with age [3,4].

Although angiokeratomas could serve as a key diagnostic sign, they are not considered as a reliable prognostic marker as they are often not directly related with systemic morbidity [5]. Besides, although clinical trials have shown the efficacy and safety of enzyme replacement therapy (ERT) with improvement of clinical symptoms, the reports on its effect on skin lesions are limited and contradictory [6-9].

Case Presentation

A 7-year-old boy was admitted to the University Children's

Hospital Rijeka with a two-year history of failure to thrive and widespread skin lesions. Before the admission, he was seen by numerous physicians regarding these signs, without the working diagnosis. On physical examination, the boy's weight and height were below the 5th percentile age curve. Close inspection of the skin revealed widespread angiokeratomas, most dense over the umbilical region (Figure 1a and 1b). Routine blood tests, coagulation and platelet function studies were unremarkable. Microscopic examination of a skin biopsy specimen confirmed presence of angiomas within the epidermis and dermis. Urine analysis showed minimal proteinuria. Given the presence of angiokeratoma and albuminuria, FD was included in the differential diagnosis. α -galactosidase A activity assay (8% of normal activity) and subsequent genetic studies (p.W81X mutation in the *GLA* gene) verified the diagnosis of FD.

Comprehensive assessment was performed to determine the extent of organ involvement. Glomerular filtration rate was normal. Kidney biopsy showed changes in the glomerular, tubulointerstitial

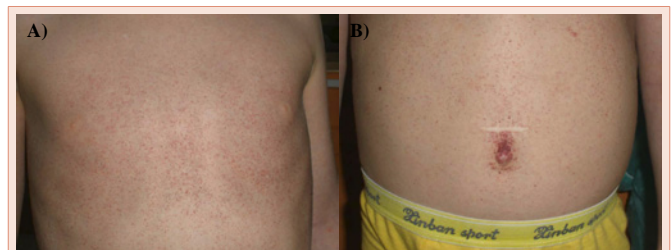


Figure 1: (a) Diffuse angiokeratomas at diagnosis, (b) most dense over the umbilical region.

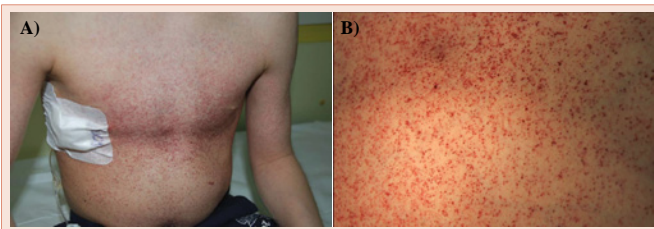


Figure 2: (a, b) Angiokeratomas at diagnosis and after 36 months of treatment.

and vascular compartments. Electron microscopy demonstrated characteristic myelin-like inclusions, most prominently in the podocyte cytoplasm. Slit lamp examination revealed ocular abnormalities including cornea verticillata, conjunctival vessel tortuosity, and posterior subcapsular lenticular opacities. The electrocardiogram and echocardiogram excluded cardiac involvement. Detailed neurologic examinations and audiogram were normal. X-ray of the left hand showed marked delay in skeletal maturation with the age of 2 years. Bone densitometry demonstrated severe osteoporosis with significant risk of fractures. Because of the multisystem involvement, ERT with agalsidase beta was commenced, which the boy tolerated well.

The patient was followed-up carefully. At 36 months of treatment, he had gained weight and height significantly. His bone age increased from 2 to 6 years. Albuminuria occurred only intermittently, and glomerular filtration rate remained normal. The results of cardiac and neurologic examinations were unremarkable. Plasma and urine GL-3 levels, which were elevated at baseline, were remarkably reduced. However, angiokeratomas increased in size and number (Figure 2a and 2b). The boy has not developed any new sign of FD.

Discussion

FD is a devastating, progressive inborn error of glycosphingolipid metabolism. Diagnosis is often delayed because of the rarity of the condition, multisystem involvement and the non-specific nature of many symptoms. Furthermore, the pattern of signs and symptoms may vary significantly among patients, even within the same family.

Observation of angiokeratomas may be one of the first clues to the presence of FD. These characteristic skin lesions are caused by weakening of the capillary wall due to glycosphingolipid accumulation, and subsequent vascular ectasia within the epidermis and dermis. They usually become apparent during childhood or adolescence, and have a predilection for the umbilical region, lower abdomen, buttocks, groin, genital areas and thighs. Angiokeratomas may also occur on mucosal areas, such as the conjunctiva, mouth, and respiratory, gastrointestinal and genitourinary tract [3,4].

Although angiokeratomas can serve as a diagnostic sign, there is no evidence that they could be a prognostic marker. Besides, their importance as ERT effectiveness marker is not established, and published data are sparse and inconsistent. Buongiorno and Pistone [6] reported two patients in whom angiokeratomas remained stable after 12 months of ERT. Tsambaos et al. [7]. and Fauchaise et al. [8]. observed reduction in both size and number of angiokeratomas

during ERT. In contrary, Ries and Schiffman [9] described an increase of angiokeratoma formation in some patients receiving ERT. They also reported that the presence of angiokeratoma was associated with higher risk of end-organ involvement in male children and adolescents.

In our patient with non-classical presentation, angiokeratomas became apparent at a very young age of 5 years. At diagnosis, two years later, he had marked growth retardation, renal involvement and delayed bone age. Initiation of ERT resulted in catch-up growth, skeletal maturation, and reduction of proteinuria. Plasma and urine GL-3 concentrations decreased. Angiokeratomas slowly increased in number and size during the intervening years. Our observation does not support angiokeratomas as a marker of the efficacy of ERT. Further large studies are required to clarify the precise role and effect of ERT on vascular skin lesions in patients with FD.

Conclusion

Although cutaneous signs of FD generally appear during childhood, the diagnosis is often delayed or missed. This case confirms that vascular skin lesions could serve as a diagnostic sign in FD. However, in contrary to some previous reports, it does not support angiokeratomas as surrogate marker of the course of the disease or efficacy of ERT.

Conflict of Interest Statement

The authors have not received any grant support for the submitted manuscript and do not serve as consultants to Genzyme Corp.

References

1. Germain DP (2010) Fabry disease. *Orphanet J Rare Dis* 5: 30.
2. Waldek S, Patel MR, Banikazemi M, Lemay R, Lee P (2009) Life expectancy and cause of death in males and females with Fabry disease: findings from the Fabry Registry. *Genet Med* 11: 790-796.
3. Orteu CH, Jansen T, Lidove O, Jaussaud R, Hughes DA, et al. (2007) Fabry disease and the skin: data from FOS, the Fabry outcome survey. *Br J Dermatol* 157: 331-337.
4. Möhrenschrager M, Braun-Falco M, Ring J, Abeck D (2003) Fabry disease: recognition and management of cutaneous manifestations. *Am J Clin Dermatol* 4: 189-196.
5. Larralde M, Luna P. Fabry disease. In: Wolff K, Goldsmith LA, Katz SI, Gilchrist BA, Paller A, Leffell DJ, editors. *Fitzpatrick's Dermatology in General Medicine*. New York: McGraw-Hill; 2007. p. 1281-1288.
6. Buongiorno MR, Pistone G, Aricò M (2003) Fabry disease: enzyme replacement therapy. *J Eur Acad Dermatol Venereol* 17: 676-679.
7. Tsambaos D, Chroni E, Manolis A, Monastirli A, Pasmatzis E, et al. (2004) Enzyme replacement therapy in severe Fabry disease with renal failure: a 1-year follow-up. *Acta Derm Venereol* 84: 389-392.
8. Ries M, Schiffmann R (2005) Fabry disease: angiokeratoma, biomarker, and the effect of enzyme replacement therapy on kidney function. *Arch Dermatol* 141: 904-905.
9. Fauchais AL, Prey S, Ouatarra B, Vidal E, Sparsa A (2010) Angiokeratoma regression in a Fabry disease after treatment with agalsidase-beta: clinical effectiveness marker? *J Eur Acad Dermatol Venereol* 24: 737-738.

Copyright: © 2014 Roganovic J, et al. This is an open-access article distributed under the terms of the Creative Commons Attribution License, which permits unrestricted use, distribution, and reproduction in any medium, provided the original author and source are credited.

Citation: Roganovic J, Barisic I, Jonjic N, Fumic K, Dordevic A (2014) Angiokeratoma in Fabry Disease: Diagnostic but not Treatment Effectiveness Marker. *Global J Med Clin Case Reports* 1(2): 035-036. DOI: 10.17352/2455-5282.000012