

Leanne Foster and Claude Abdallah*

Division of Anesthesiology, Children's National Medical Center, The George Washington University Medical Center, USA

Dates: Received: 23 February, 2016; Accepted: 16 March, 2016; Published: 18 March, 2016

*Corresponding author: Claude Abdallah, MD, MSc, Division of Anesthesiology, Children's National Medical Center, The George Washington University Medical Center, 111 Michigan Avenue, NW, Washington D.C. 20010-2970, Tel: (202) 476-2025/2407; E-mail: cabdalla@cnmc.org

www.peertechz.com

ISSN: 2455-3476

Keywords: MURCS Association; Cervical Decompression; Child

Case Report

Emergent Cervical Decompression in a Child with MURCS Association

foramen magnum with severe mass effect on the medulla, Chiari I, as well as upper cervical syrinx and multiple cervical segmentation abnormalities with dysgenesis of the craniocervical junction (Figure 1). In the operating room, anesthesia was induced with propofol 3 mg/kg, fentanyl 1 mcg/kg and rocuronium 1 mg/kg after insuring the patency of the endotracheal tube, adequate intravenous access and an arterial line in place. The respiratory status was optimized with inhaled albuterol administration, endotracheal tube suctioning, and positive end expiratory pressure. Patient was placed in a prone position with the head supported by a cerebellar head rest. The initial phase of the surgery including tissue dissection and partial occipital craniotomy was well tolerated; however, repeated episodes of bradycardia and hemodynamic instability necessitated repetitive vasopressors including atropine 0.02mg/kg, epinephrine 5 mcg/kg followed by 10mcg/kg boluses and infusions of dopamine 10 mcg/kg/min and epinephrine starting at 0.1 mcg/kg/min and titrated to response; and correlated on occasion with minimal surgical manipulation.

The surgeon was informed and ultimately, the procedure was stopped after partial foramen magnum decompression and partial C2 laminectomy for further severe hemodynamic instability and desaturations despite vasopressors administration. Patient was transported back to the pediatric intensive critical care unit, weaned gradually from vasopressors and after four days of aggressive additional broad-spectrum antibiotics and steroids, she tolerated a return to the operating room for complete decompression of the foramen magnum and recovered with no sequelae.

Discussion

This case report describes a child with MURCS association who presented from an outside hospital for emergency craniocervical decompression secondary to critical stenosis of the foramen magnum. MURCS association usually does not affect life expectancy [1,2], however there are two reported findings on autopsy of an occipital encephalocele in two fetuses [3]. Foramen magnum stenosis is usually associated to achondroplasia. Literature review shows that decompression of the cervicomedullary junction in the setting of achondroplasia may be accomplished safely with significant clinical benefit and minimal morbidity [4], however, in one case hypotension and bradycardia had been reported in a child with achondroplasia who has a severe stenosis of the foramen magnum [5]. This patient with MURCS association may have been at high risk of severe hemodynamic instability secondary to the severity of stenosis of foramen magnum. Brainstem compression or retraction would alter the respiratory pattern. It also may be detected by its effects on cardiovascular function. Arrhythmias may occur simultaneously in

Introduction

This case report describes an unusual presentation and anesthesia management of a rare genetic association. The MURCS association, a variant of Mayer-Rokitansky-Küster-Hausler syndrome is a rare (1/4500-1/50,000) congenital syndrome, of unknown etiology, consisting of mullerian duct (MU) aplasia, renal (R) aplasia, and cervicothoracic somite (CS) dysplasia.

Case Description

A 3 years old female, with a history of MURCS association including vertebral anomalies, foramen magnum stenosis, upper cervical syrinx and central sleep apnea presented to an outside hospital following sinus congestion. She was initially found to have respiratory syncytial virus (RSV) bronchiolitis. The patient had breath holding spells associated with severe bradycardia, requiring tracheal intubation and hemodynamic resuscitation. Tracheal intubation was performed by the ear/nose/throat surgeon, as the patient had a critical airway due to cervical stenosis.

She was transferred to our institution for urgent decompression after an MRI of the brain and neck showed critical narrowing of the

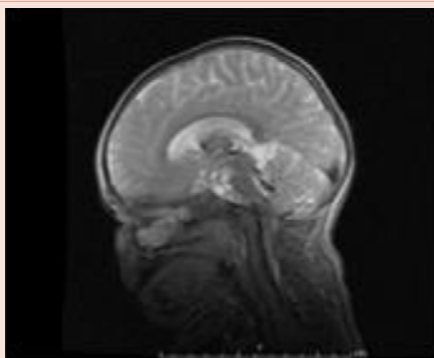


Figure 1: MRI of the brain and neck showing critical narrowing of the foramen magnum with severe mass effect on the medulla.

as many as 14% of pediatric patients. This may be associated with a sudden alteration in vascular tone, resulting in sudden hypotension or hypertension and severe hemodynamic instability. The mechanism may result from the activation of the trigemino-cardiac reflex or the vago-glossopharyngeal reflex. Transcutaneous pacing should be considered during the surgery in these patients at risk of severe hemodynamic instability. Cardio-pulmonary resuscitation of a child in prone position may be challenging, especially if associated with skeletal deformities. Readiness for management of hemodynamic instability and anticipation of possible difficult airway is of crucial importance in dealing with decompression of severe foramen magnum stenosis. This case reports the possible coexistence and management of severe foramen magnum stenosis in patients with MURCS association. Communication between the surgical and anesthesia team is essential to discontinue the surgical manipulation, if needed.

References

1. Al Kaissi A, Ben Chehida F, Ben Ghachem M, Grill F, Klaushofer K (2009) Occipitoatlantoaxial junction malformation and early onset senile ankylosing vertebral hyperostosis in a girl with MURCS association. *Am J Med Genet A* 149A: 470-474.
2. Duncan PA, Shapiro LR, Stangel JJ, Klein RM, Addonizio JC (1979) The MURCS association: mullerian duct aplasia, renal aplasia, and cervicothoracic somite dysplasia. *J Pediatr* 95: 399-402.
3. Lin HJ, Cornford ME, Hu B, Rutgers JK, Beall MH, et al. (1996) Occipital encephalocele and MURCS association: case report and review of central nervous system anomalies in MURCS patients. *Am J Med Genet* 61: 59-62.
4. Bagley CA, Pindrik JA, Bookland MJ, Camara-Quintana JQ, Carson BS (2006) Cervicomedullary decompression for foramen magnum stenosis in achondroplasia. *J Neurosurg* 104: 166-72.
5. Ozcetin M, Arslan MT, Karapinar B (2012) Achondroplastic Case with Foramen Magnum Stenosis, Hydrocephaly, Cortical Atrophy, Respiratory Failure and Sympathetic Dysfunction. *Iran J Pediatr* 22: 121-124.

Copyright: ©2016 Foster L, et al. This is an open-access article distributed under the terms of the Creative Commons Attribution License, which permits unrestricted use, distribution, and reproduction in any medium, provided the original author and source are credited.

Citation: Foster L, Abdallah C (2016) Emergent Cervical Decompression in a Child with MURCS Association. *Glob J Anesthesiol* 3(1): 004-005. DOI: 10.17352/2455-3476.000021