

Qinghao Cheng* and Lei Li

Department of Anesthesiology, China Meitan General Hospital, Beijing 100028, China

Dates: Received: 07 April, 2015; Accepted: 13 April, 2015; Published: 15 April, 2015

*Corresponding author: Qinghao Cheng, Department of Anesthesiology, China Meitan General Hospital, Beijing 100028, China, E-mail: cqh4000@163.com

www.peertechz.com

ISSN: 2455-3476

Keywords: Bronchoscopy intervention; Laryngeal mask airway; Infant anesthesia; Airway stenosis

Case Report

Brochoscopy Intervention using Laryngeal Mask Airway in Infant for Severe Airway Stenosis

kpa; and SpO₂, 92%. Laboratory investigation revealed no significant findings. After consulting with anesthesiologists, endoscopists, surgeons and radiologists, EBI for tracheal stenosis was scheduled though LMA because of her poor respiratory condition.

Anesthetic induction, and maintenance

No pre-medicated drugs were treated before the induction of anesthesia. The patient was monitored using a non-invasive measurement of blood pressure, electrocardiogram, pulse oxymetry, endtidal carbon dioxide concentration. Anesthesia was induced with intravenous sufentanyl (1ug/kg) lidocaine (2mg/kg), propofol (3mg/kg), rocuronium (0.6mg/kg) and slow infusion of atropine (0.02mg/kg), followed by titration of propofol (812mg·kg⁻¹·h⁻¹), and remifentanyl (0.2-0.4ug·kg⁻¹·min⁻¹). A 2nd LMA was then inserted. The size of the LMA was chosen based on the manufacturer's guidelines and the diameter of electric bronchoscope. The infusion rate of propofol and remifentanyl were titrated with baseline vital signs.

Ventilation in patients was performed through the main entry of the Y-connector between the LMA and the anesthesia circuit (Figure 1B). Jet ventilation was applied through the side entry of the Y-connector in patient with jet ventilator (Jiangxiteli Medical Instruments, China). Initial settings were as follows: driving pressure 3 kg/cm², respiratory rate 16 to 24 bpm, and inspiratory fraction 50%. Inspired oxygen fraction (FiO₂) was set at 100% in the whole intervention. Settings were modified during the procedure to achieve both an optimal gas exchange. Ventilation was monitored following continuous pulse oxymetry and intermittent blood gas. When SPO₂ lower 95%, we stopped therapy and manually ventilation until SPO₂ 100mm Hg if therapy permitted.

Introduction

Fibreoptic bronchoscopy (FB) and laryngeal mask airway (LMA) have been used successfully in children since the early 1980s [1,2]. The paediatric fibreoptic bronchoscopy via laryngeal mask airway (LMA) in general anesthesia was established in 1990s [3,4]. Although previous studies have shown some experience on FB in infant, conclusive effects on bronchoscopy intervention are unknown. We report the use of laryngeal mask airway (LMA) to guide electric bronchoscopy interventions (EBI) while maintaining an adequate depth of anesthesia and effective ventilation in small infant who was diagnosed of having severe airway stenosis from computed tomography (CT) scan.

Case Reports

A five-month-old female infant weighing 6kg, was arranged to EBI using LMA. She was hospitalized because of caught one month ago. Preoperative examination: Karnofsky score 20 points, inspiratory stridor, intermittent cyanosis. CT and FB revealed 80% tracheal obstruction (Figure 1A). The stenosis was arising from trachea membrane 20 mm below the vocal cord. The stenotic lesion had extended from the origin of tracheal bronchus to the carina (length of stenosis was 11 mm), without involving the carina. The luminal diameter at the narrowest of the trachea was 2 mm. arterial blood gas analysis were as follows: pH 7.35; PaCO₂, 6.58 kpa; PaO₂, 7.70

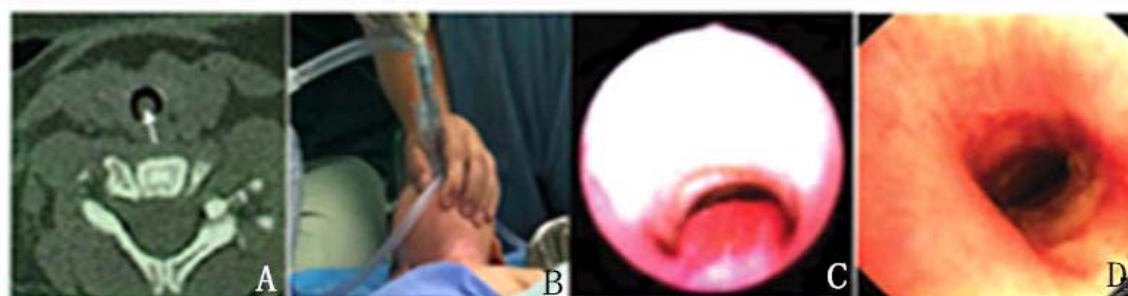


Figure 1: A) CT showing airway stenosis. B) Y-connector. C) Bronchoscopy photography showing a narrowest portion of the trachea. D) Bronchoscopy photography showing canalization of the trachea.

Technique of bronchoscopic intervention

Procedures were performed with electric flexible bronchoscopes (Pantex, Japan, bronchoscopes of external diameters 4.9 mm and 2.8mm) through the 2[#] LMA. When managing airway obstruction, endoscopists recanalized the obstructed lumen and relieve the patient's symptoms [5](Figure 1C). Various methods for controlling the airway have been established to solve this problem, such as the electric loop, cryoprobe, argon plasma coagulation. The operation took 30 minutes (Figure 1D). After operation, the findings of the postoperative arterial blood gas analysis were as follows: pH 7.01; PaCO₂, 15.33KPa; PaO₂, 10.13KPa and SpO₂, 93%.we remove LMA and insert the endotracheal 3.5[#] tube. The patient was transferred to the intensive care unit. 6 hours after the surgery, endotracheal tube was removed. The pathological diagnosis is hemangioma. A week later, the patient discharged. After a year follow-up, the patient has no breath suppress symptoms.

Discussion

EBI under general anesthesia is difficult and hazardous in small infant. Although a rigid bronchoscope is suitable for examining the larynx under general anesthesia, it is more hazardous to tissues around the larynx than fiberoptic procedures. Thus, fiberoptic bronchoscopy with the LMA should fulfill both the requirements of diagnosis and of safety for children [3,6,7].

By contrast, EBI through an endotracheal tube under general anesthesia is a safe procedure, but narrow airway cannot be passed through an appropriately sized bronchoscope. The smallest bronchoscope which has a biopsy channel is 4.9 mm in diameter and endotracheal tube of at least 7 mm in diameter. This would effectively mean that transbronchial intervention could only be performed in children over 8 years of age [3]. The smallest bronchoscope with a suction channel is 2.8 mm in diameter and requires endotracheal tube of at least 4.5 mm in diameter. The lower age limit for bronchoalveolar lavage would then be 1 years. So the size 2 LMA (internal diameter 7 mm) is suitable for use in infants.

Most centers avoid bronchoscopy in children under light sedation because the results will often remain unsatisfactory because of cough and movement. Also, in our experience, significant problems during the procedure are usually due rather to a too shallow and almost never to a too deep level of anesthesia/sedation. A recent review of this topic shows a practical approach to these procedures [8]. Even with deep sedation, protective airway reflexes must be suppressed to allow the passage of the bronchoscope through the glottis, generating a similar level of aspiration risk as during anesthesia [9]. In line with practice in children anesthesia in our department, we use general anaesthetic, rather than sedation, for all interventions. This enables better monitoring and airway control. So we also advocate that bronchoscopy interventions in children should only be performed under general anaesthetic [10].

During this case postoperative blood gas PaO₂, PaCO₂ higher

indicate that mechanical ventilation is inadequate. The reasons of inadequate ventilation include tracheal diameter thin, relative large bronchoscope, and secretions, blood, shedding tiny tissues etc. When SPO₂ lower than 95%, we stopped the intervention and begin handal ventilation until SPO₂ 100%. After pause the therapy, oxygen saturation rate was 78. This indicates that infants have limited oxygen reserve, especially collapse of the small airways and an interval of hypoxemia [11].

Although this case was performed through LMA, other devices should be prepared. From our limited experience, the following features should be focused on. (1) Adjust patient, head low-feet high position, avoid aspiration. (2) Anesthesiologist should be familiar with anesthetic airway control and prepare different sizes of tubes, establish emergency airway. This is critical when managing patients with airway obstruction. (3) During interventions, certified and fully trained nurse is required to the safe procedure.

In conclusion, the LMA is useful for fiberoptic bronchoscopy of children with severe subglottic stenosis. The anesthesiologist must be responsible for the airway in the whole intervention and control the airway quickly when emergency.

Acknowledgements

We would like to thank all the individuals who participated in this study for their support.

References

1. Wood RE, Postma D (1988) Endoscopy of the airway in infants and young children. *J Pediatr* 112: 1-6.
2. Brain AI (1983) The laryngeal mask-a new concept in airway management. *Br J Anaesth* 55: 801-805.
3. Smyth AR, Bowhay AR, Heaf LJ, Smyth RL (1996) The laryngeal mask airway in fibreoptic bronchoscopy. *Arch Dis Child* 75: 344-345.
4. Wood RE (1996) Pediatric bronchoscopy. *Chest Surg Clin N Am* 6: 237-251.
5. Gorden JA, Ernst A (2009) Endoscopic management of central airway obstruction. *Semin Thorac Cardiovasc Surg* 21: 263-273.
6. Bandla HP, Smith DE, Kiernan MP (1997) Laryngeal mask airway facilitated fibreoptic bronchoscopy in infants. *Can J Anaesth* 44: 1242-1247.
7. Baraka A, Choueiry P, Medawwar A (1995) The laryngeal mask airway for fibreoptic bronchoscopy in children. *Paediatr Anaesth* 5: 197-198.
8. Dilos BM (2009) Anesthesia for pediatric airway endoscopy and upper gastrointestinal endoscopy. *Int Anesthesiol Clin* 47: 55-62.
9. Nicolai T (2011) The role of rigid and flexible bronchoscopy in children. *Paediatric Respir Rev* 12: 190-195.
10. Scott JP, Higenbottam TW, Smyth RL, Whitehead B, Helms P, et al. (1990) Transbronchial biopsies in children after heart-lung transplantation. *Pediatrics* 86: 698-702.
11. Nadkarni V (2000) Ventricular fibrillation in the asphyxiated piglet model. In: Quan L, Franklin WH, eds. *Ventricular Fibrillation: a Pediatric Problem*. Armonk, NY: Futura Publishers 43-54.

Copyright: © 2015 Cheng Q, et al. This is an open-access article distributed under the terms of the Creative Commons Attribution License, which permits unrestricted use, distribution, and reproduction in any medium, provided the original author and source are credited.

Citation: Cheng Q, Li L (2015) Brochoscopy Intervention using Laryngeal Mask Airway in Infant for Severe Airway Stenosis. *Glob J Anesthesiol* 2(1): 012-013. DOI: 10.17352/2455-3476.000009